

# The Potential Impact of Cone Eccentricity on Visual Outcomes in Inferior and Central Keratoconus Patients following Keraring Implantation: A Pilot Preliminary Study

<sup>1</sup>Iraklis Vastardis, <sup>2</sup>Aye Khine, <sup>3</sup>Mohamed Elalfy, <sup>4</sup>Samer Hamada, <sup>5</sup>Georgios Perdikakis, <sup>6</sup>Markus Kohlhaas  
<sup>7</sup>Zisis Gatzoufas

## ABSTRACT

**Aim:** To evaluate possible correlation of cone eccentricity and visual acuity in inferior and central keratoconus patients following Keraring implantation for keratoconus.

**Materials and methods:** A total of 19 eyes from an equal number of patients were analyzed in this preliminary pilot retrospective study. Two groups were formed, group I for inferior (n = 11) and group II for central keratoconus (n = 9). Uncorrected distance visual acuity (UDVA), corrected distance visual acuity (CDVA), keratometric readings, central corneal thickness, maximum keratometric distance from corneal apex (DKmax), and corneal thinnest point from corneal apex (DTh) were evaluated preoperatively and 6 months after the Keraring implantation. The DKmax and DTh were measured and from corneal apex to evaluate the eccentricity of the cone.

**Results:** The CDVA and refractive cylinder reduction improved at 6 months postoperatively in both groups (t-test, p = 0.002, p < 0.0001 and p = 0.0007, p = 0.0017 respectively). Topography keratometric findings (Kmax difference) and spherical equivalent improved for group II but not for group I (t-test, p = 0.002, p = 0.005 and p = 0.85, p = 0.12 respectively). There was a high correlation between CDVA and corneal astigmatic reduction (p = 0.0283, correlation coefficient r = -0.7) and a negative relation in regression analysis (p = 0.0240, y = 0.2616 + -0.1354 x + 0,03750 x 2, coefficient of determination R<sup>2</sup> = 0.7115) for the central keratoconus but not for the inferior one.

There was no correlation between the topography landmarks DKmax or DTh and CDVA and no statistical difference was found between them in t-test at 6 months.

**Conclusion:** Both groups profited from a Keraring implantation in terms of CDVA, but a relation between corneal astigmatic reduction and CDVA after Keraring implantation at 6 months was found only in patients with central keratoconus.

**Clinical significance:** This finding suggests that a visual acuity improvement in keratoconus patients is not only topographic and keratometric-related but also higher order aberration reduction-dependent. Bigger prospective studies that also evaluate corneal aberration reduction findings are needed to support our results.

**Keywords:** Eccentricity, Kerarings, Keratoconus.

**How to cite this article:** Vastardis I, Khine A, Elalfy M, Hamada S, Perdikakis G, Kohlhaas M, Gatzoufas Z. The Potential Impact of Cone Eccentricity on Visual Outcomes in Inferior and Central Keratoconus Patients following Keraring Implantation: A Pilot Preliminary Study. *Int J Kerat Ect Cor Dis* 2018;7(1):12-18.

**Source of support:** Nil

**Conflict of interest:** None

## INTRODUCTION

Intracorneal ring segments (ICRS) are polymethylmethacrylate implants that are inserted into the 5 mm zone of the cornea, resulting in a geometrical alteration of its properties and enhancing its refractive output and visual outcomes.

These implants were first proposed by Burris<sup>1</sup> as surgical solution for moderate refractive myopia, but were employed in keratoconic patients by Collin et al,<sup>2</sup> showing that ICRS is a viable and promising surgical option in terms of topographical regularity that results in increased uncorrected visual acuity among other findings.

Many models of ICRS in relation to thickness, diameter, and shape are available nowadays and used to regulate corneal geometry in order to restore visual acuity in patients with keratoconus. They are inserted between the corneal stromal fibers, where a remodeling arc-shortening effect is induced, which flattens the 3 to 5 mm zone and restores corneal symmetry.<sup>3</sup>

Some theoretical models have shown that the flattening effect is directly proportional to the thickness of the ICRS and inversely proportional to the corneal diameter, suggesting that the thicker the segment and the smaller the diameter in the cornea where the device is implanted, the higher the flattening effect will be achieved.<sup>4</sup> These models apply only to normal corneas

<sup>1-5,7</sup>Attending Physician, <sup>6</sup>Head

<sup>1,5,6</sup>Department of Ophthalmology, St.-Johannes-Hospital Dortmund, Nordrhein-Westfalen, Germany

<sup>2-4,7</sup>Department of Corneo-Plastic Unit, QVS Direct, East Grinstead, UK

**Corresponding Author:** Iraklis Vastardis, Attending Physician Department of Ophthalmology, St.-Johannes-Hospital, Dortmund Nordrhein-Westfalen, Germany, e-mail: vastardis.iraklis@gmail.com

where an orthogonal pattern of the collagen fibers is found, but in an abnormal cornea with keratoconus, with an abnormal disposition of fibers, the response of the segments is unpredictable.<sup>5</sup>

Barraquer also proposed "Thickness law" stating that when tissue is added to the periphery of the cornea or tissue is removed from the center, a flattening of the cornea will be achieved and vice versa, that could explain also the flattening effect of ICRS.<sup>6</sup> Many studies have provided positive results after ICRS implantation in keratoconus patients in relation to improved keratometry, spherical equivalent, higher order aberrations, and refractive cylinder changes, but also in UDVA, CDVA respectively.<sup>7-11</sup>

Overall, ICRS present good long-term results and their beneficial effect even after ICRS explanation is well documented.<sup>12-14</sup> Complications following ICRS implantation include infections, displacement or migration, extrusion, corneal scarring, and vascularization.<sup>10,14-16</sup> Their implantation was initially managed manually where a calibrated diamond blade was used to create a corneal pocket at approximately 70% of the corneal thickness after fixation of the eye with a suction ring placed around the limbus. The pocket of the corneal stroma is elongated with two semicircular dissectors that advance in the deep stroma in a clockwise and counter-clockwise movement, making space between the corneal lamellas where ICRS will be inserted.<sup>15</sup> With the advent of femtosecond laser technology, simplifying the procedure, the mechanical method was less favored.<sup>15,16</sup>

Several nomograms<sup>17-21</sup> have surfaced over the years but the most widespread ones used are those proposed by the main manufacturers of ICRS. These nomograms are custom fit according to topographic findings of each patient's corneal characteristics, which consider indications and contraindications, thus providing safety and efficacy of this surgical procedure.<sup>22-24</sup>

However, we are of the opinion that despite all this information available and all the technology surrounding modern corneal surgery nowadays, we have yet to determine a clear prognostic preoperative factor that could guarantee success in relation to visual outcomes after ICRS implantation in patients with keratoconus. This preliminary retrospective pilot study tries to highlight any difference in terms of visual acuity rehabilitation when the inferior keratoconus and central keratoconus are compared and if the eccentricity plays a role regarding topographic findings in such patients after ICRS implantation.

## MATERIALS AND METHODS

This was a retrospective, preliminary pilot study. Our study included 19 patients (Table 1) with stable keratoconus who underwent unilateral Keraring (Mediphacos,

**Table 1:** Demographic summary table of both groups

Characteristics	Value
<i>Demographic data of the study group I</i>	
No. of patients	11
Age median and standard deviation	43 ± 6.66 years
Male:female ratio	8:3
Right eye:left eye ratio	4:7
Inferior Keratoconus stage 2:stage 3 ratio	5:6
<i>Demographic data of the study group II</i>	
No. of patients	9
Age median and standard deviation	43 ± 10.6 years
Male:female ratio	6:3
Right eye:left eye ratio	4:5
Central keratoconus stage 2:stage 3 ratio	3:6

Belo Horizontale, Brazil) implantation with the use of a femtosecond laser (LDV Z6; Ziemer, Port, Switzerland). The patients were divided into two groups, group I for inferior keratoconus and group II for central keratoconus.

All patients had keratoconus stage 2 or 3 according to the Amsler-Krumeich classification. Corneal topography was evaluated using a Scheimpflug camera (Pentacam; Oculus Optikgeräte, Wetzlar, Germany). Keratoconus was diagnosed by corneal topography and corneal elevation mapping, and evaluated by Scheimpflug imaging (Pentacam).

None of the eyes included had undergone corneal cross-linking or refractive surgery and they all had stable keratoconus prior to surgery. Inclusion and exclusion criteria are seen in Table 2. A complete ophthalmic examination was performed preoperatively and postoperatively, including UDVA, CDVA, manifest refraction, spherical equivalent, keratometry readings (in diopters [D]), central corneal thickness (µm), maximum keratometric distance from corneal apex (DKmax), and thinnest point distance from corneal apex (DTh).

The DKmax and DTh were used as topographic landmarks of the cone eccentricity and have been calculated

**Table 2:** Exclusion and inclusion criteria

Inclusion criteria	Exclusion criteria
Age over 21 years	Age less than 21 years
Signed informed consent	Prior refractive surgery or cross-linking
CDVA < 0.2 LogMar or 0.63 Snellen	Corneal scarring
Corneal thickness > 400 µm in the area of ICRS implantation	Ocular surface anomalies, e.g., dry eye disease
Keratoconus inferior and central	Other ocular pathology
Rigid form contact lens intolerance	Pregnancy
<i>Postoperative</i>	
Topical regimen	Chloramphenicol 0.5%/2 weeks Fluorometholone 0.1%/4 weeks

with the aid of the Pentacam-derived x and y values for Kmax and thinnest point respectively, using the Pythagorean theorem: Distance from the center = Visual acuity was measured using Snellen and then converted to logMAR for statistical analysis.

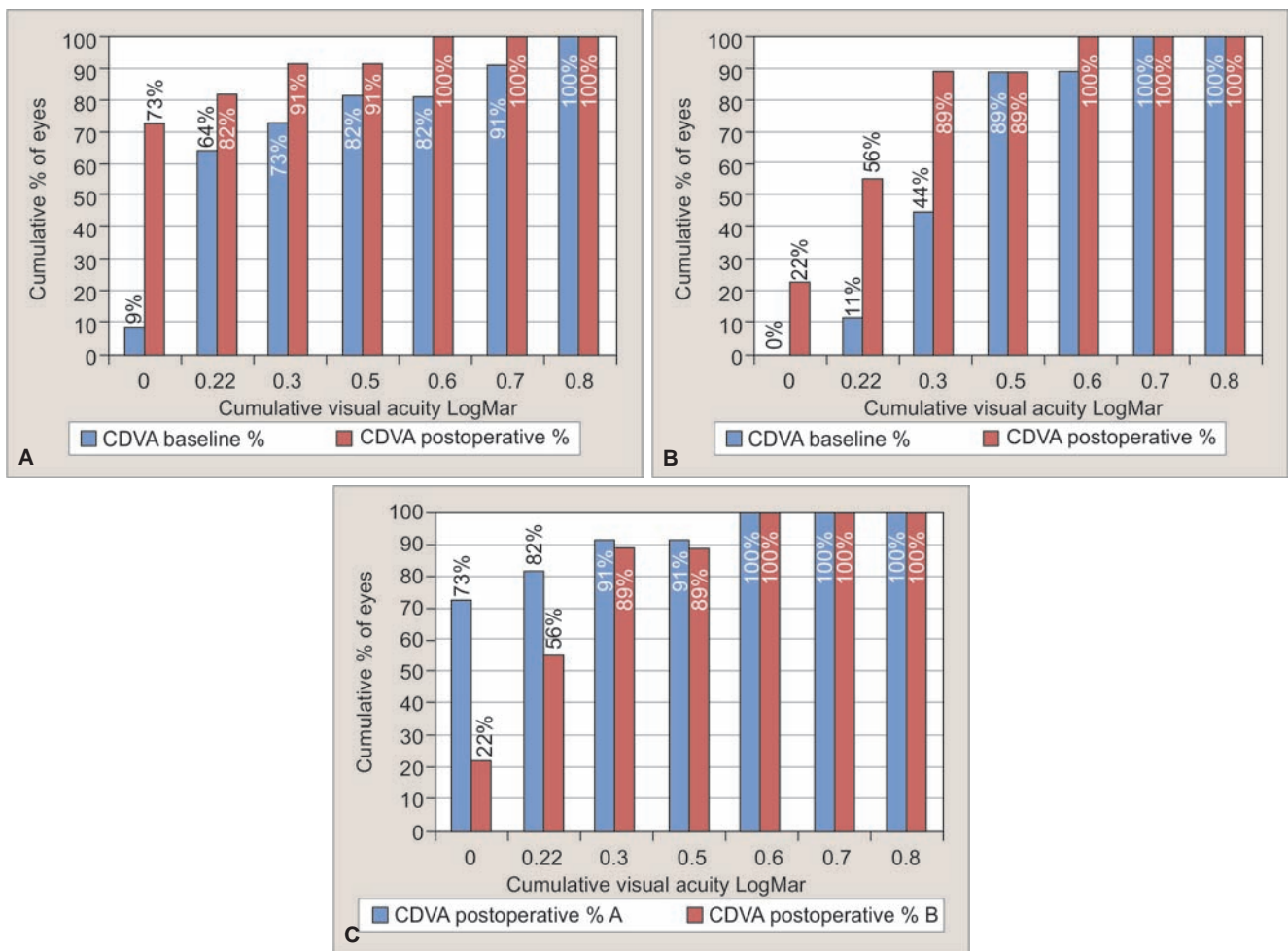
The appropriate ring segment for the every single procedure was selected individually for each patient according to the manufacturer provided nomogram and precalculated parameters. Keratoconus shape (nipple, bow tie, or oval), corneal asymmetry, astigmatic values, and manifest refraction are integrated in this nomogram and taken into consideration prior to implantation.

The first ring segmented was inserted directly in flat axis of the cone. Its diameter was 5 mm and the thickness varied from 150 to 300 μm. The tunnels were created with femtosecond laser. Topical anesthesia was applied (proparacaine hydrochloride 0.5%) and the apex of the conus was marked with ink preoperatively. After appplanation of the cornea with a suction ring, the precalculated incision (2.7 mm) and corneal tunnels (1.3 mm width and 80% depth) were created in the 5-mm zone. The length of the tunnel was created to match the preselected implants.

The implantation of the ring segments was facilitated with special forceps. Follow-up took place at postoperative 1 day, 1 week, and 1, 3, and 6 months. All patients provided their written consent prior to surgery and the tenets of the Declaration of Helsinki were fully respected. The local institutional review board committee approved this study. Statistical analysis was performed using MedCalc software (version 15; MedCalc, Oostende, Belgium).

Parametric or nonparametric tests were used according distribution. A p-value of less than 0.05 was considered statistically significant. Results of 19 patients and 19 eyes were divided in two groups and analyzed in this preliminary retrospective pilot study to investigate any difference in terms of visual acuity rehabilitation when the inferior keratoconus and central keratoconus are compared and if the eccentricity plays a role regarding topographic findings in such patients after ICRS implantation. The UDVA improved although the comparison of the means was not found statistically important.

Graph 1 clearly demonstrates that cumulative visual acuity improved in both groups, with group I reaching a 55% of 0.7 LogMar (0.2 Snellen) or better and 36% a



**Graphs 1A to C:** Group I: cumulative comparison results—CDVA baseline and 6 months. Group II: cumulative comparison results—CDVA baseline and 6 months. Group I vs II: cumulative comparison results—CDVA at 6 months

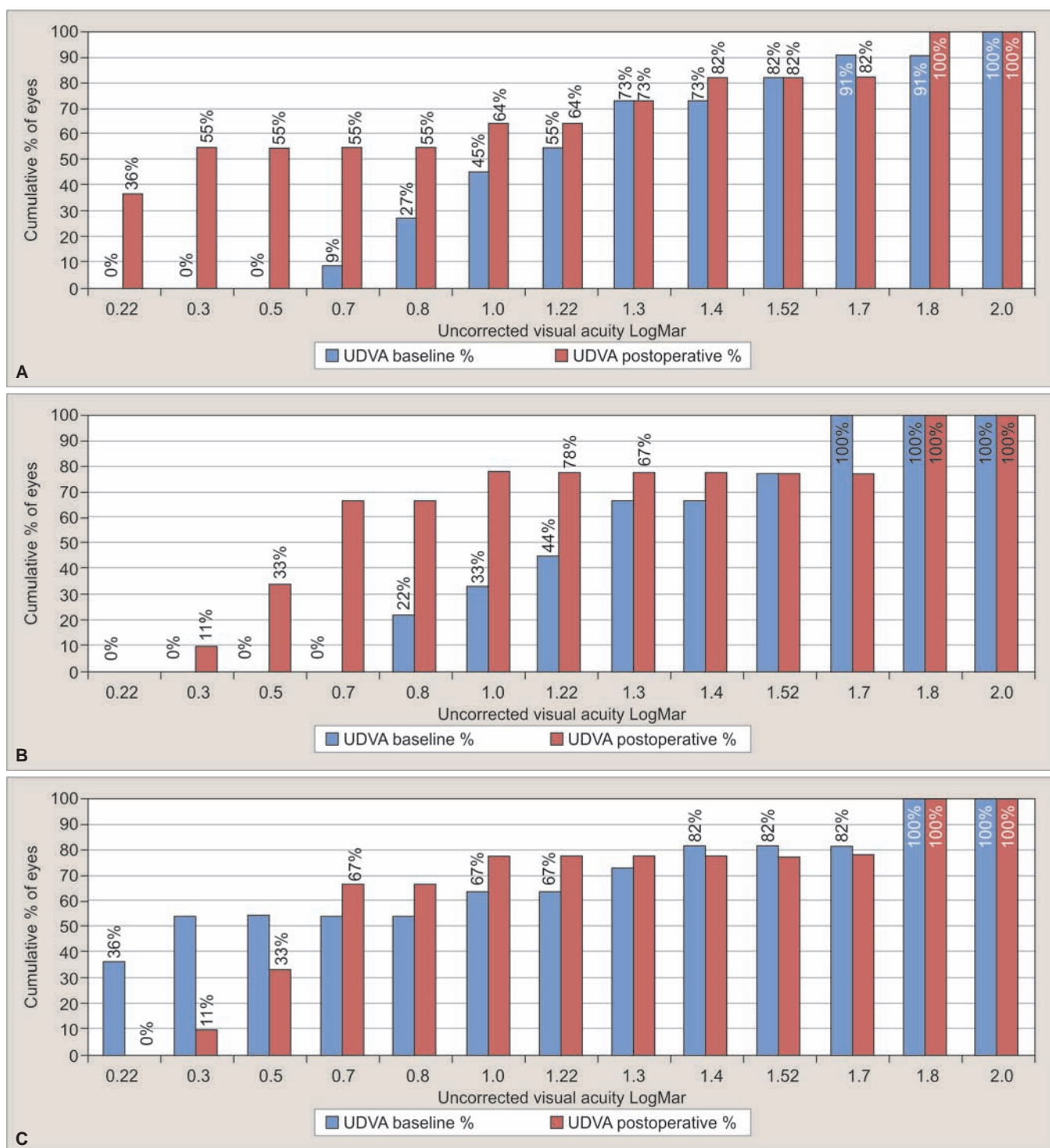


0.2 LogMar (0.63 Snellen). In group II, 67% reached a 0.7 LogMar (0.2 Snellen) or better and 11% a 0.3 LogMar (0.5 Snellen). The CDVA and refractive cylinder reduction improved at 6 months postoperatively and the difference was statistically important in both groups (t-test,  $p = 0.002$ ,  $p < 0.0001$  and  $p = 0.0007$ ,  $p = 0.0017$  respectively). Cumulative visual outcomes of CDVA are presented in Graph 2.

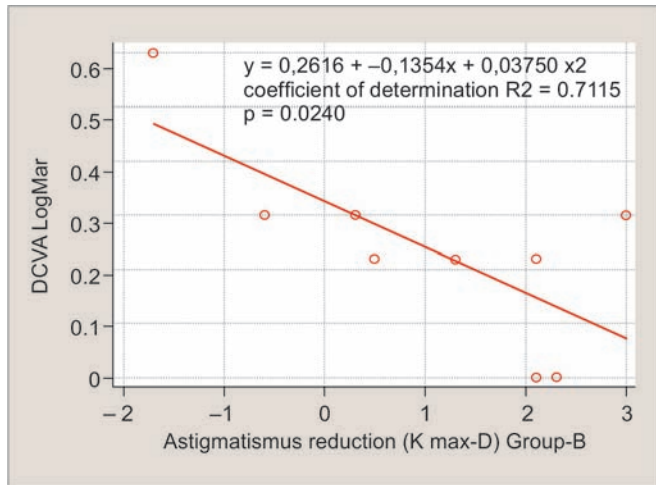
However, spherical equivalent and keratometric findings (K1, K2, and Kmax) favored clearly group II but not

group I (t-test,  $p = 0.002$ ,  $p = 0.005$  and  $p = 0.85$ ,  $p = 0.12$  respectively). There was a high correlation between CDVA and corneal astigmatic reduction ( $p = 0.0283$ , Correlation coefficient  $r = -0.7$ ) and a negative relation in regression analysis ( $p = 0.0240$ ,  $y = 0.2616 + -0,1354 \times + 0,03750 \times 2$ , Coefficient of determination  $R^2 = 0.7115$ ) for the central keratoconus but not for the inferior one (Graph 3).

There was no correlation between the topography landmarks DKmax or DTh and visual outcomes and no



**Graphs 2A to C:** Group I: cumulative comparison results—UDVA baseline and 6 months. Group II: Cumulative comparison results—UDVA baseline and 6 months. Group I vs II: Cumulative comparison results—UDVA at 6 months



**Graph 3:** Regression analysis plot demonstrating a negative relation ( $p = 0.0240$ ,  $y = 0.2616 + -0.1354x + 0.03750 \times 2$ , coefficient of determination  $R^2 = 0.7115$ ) for the central keratoconus patients

**Table 3:** Summary of the visual, refractive, and corneal topographic outcomes after ICRS implantation

Parameters	Baseline	Postoperative	p-value
<i>Group I (Inferior keratoconus, n – 11)</i>			
UDVA (LogMar)	1.21 ± 0.4	0.79 ± 0.6	=0.11
CDVA (LogMar)	0.32 ± 0.2	0.10 ± 0.1	=0.002
Spherical equivalent (D)	-3.93 ± 3.9	-2.17 ± 2.2	=0.12
Cylinder (D)	-7.86 ± 2.6	-3.65 ± 2.38	<0.0001
Kmax (D)	58.69 ± 3.61	58.91 ± 6.74	=0.85
K1 (D)	47.30 ± 3.49	47.13 ± 3.93	=0.84
K2 (D)	51.65 ± 3.14	50.78 ± 4.21	=0.33
DKmax (mm)	2.47 ± 0.24	2.45 ± 0.24	=0.11
DThin (mm)	2.45 ± 0.25	2.42 ± 0.24	=0.2
<i>Group II (Central keratoconus, n – 9)</i>			
UDVA (LogMar)	1.26 ± 0.34	0.88 ± 0.55	=0.11
CDVA (LogMar)	0.42 ± 0.1	0.24 ± 0.1	=0.0007
Spherical equivalent (D)	-8.18 ± 3.04	-3.81 ± 2.67	=0.005
Cylinder (D)	-6.38 ± 2.98	-2.58 ± 3.14	=0.0017
Kmax (D)	58.40 ± 4.69	56.41 ± 4.13	=0.002
K1 (D)	49.42 ± 4.43	47.35 ± 2.27	=0.092
K2 (D)	53.74 ± 3.27	50.65 ± 2.58	=0.0041
DKmax (mm)	0.66 ± 0.17	0.66 ± 0.16	=0.69
DThin (mm)	0.68 ± 0.16	0.67 ± 0.16	=0.81

statistical difference was found between them in t-test at 6 months. Table 3 summarizes all results found.

**DISCUSSION**

Over the years, many studies clearly demonstrated that the flattening effect of ICRS is directly proportional to the thickness of the implanted segment and inversely proportional to the corneal diameter at the implantation site.<sup>23,24</sup>

Surgical management of keratoconus with ICRS has proven to be a minimally invasive and reliable surgical option that provides very good visual outcomes in terms of UDVA, CDVA, spherical equivalent, and keratometry amelioration but also improvement of rigid form contact

lenses toleration.<sup>8,9,13,23,25,26</sup> This small retrospective preliminary pilot study was set out to evaluate possible correlation of cone eccentricity and visual acuity in patients with inferior or central keratoconus who underwent unilaterally ICRS implantation and also to attempt to establish a clear preoperative prognostic factor that could guarantee postoperative success in visual outcomes.

Preoperative prognostic factors have been identified from surgeons to be associated with the visual outcomes after ICRS implantation like poor preoperative visual acuity and alignment of the refractive and keratometric axes (angle <15°) favoring optimal visual outcomes<sup>9,27</sup> but also that significant visual improvement is less likely in advanced keratoconus, a fact that has been linked to low predictability of the keratometric and visual outcomes.<sup>25,28</sup> Regarding our topographic landmarks, no correlation was found between DKmax or DTh and visual outcomes and no statistical difference was found between them in t-test at 6 months postoperatively, so that a direct prognostic factor in relation with these two parameters was not established.

We did, however, notice a great difference in spherical equivalent and keratometric findings (K1, K2, and Kmax), a high correlation between CDVA and corneal astigmatic reduction and a negative relation in regression analysis postoperative that favored clearly central keratoconus group over the inferior one. We know that central cones seems to respond better in various surgical treatments and that its location appears to affect visual acuity with better results for cones within a central 2-mm zone.<sup>29,30</sup>

Considering that CDVA and refractive cylinder reduction improved at 6 months postoperatively and the difference was statistically important in both groups, we assume that such an improvement in keratoconus patients is not only topographic and keratometric-related but also higher order aberration reduction-dependent. Other studies have clearly established a link between increase of visual acuity and improvement of the aberrometric profile, mainly in reduction of coma, as a result of corneal geometry and symmetry improvement after ICRS implantation.<sup>9,13</sup>

Recently, Gatziofufas et al<sup>31</sup> demonstrated an improvement of keratometric readings, but also reduction of coma after ICRS implantation leading to UDVA and CDVA improvement.

**CONCLUSION**

Although in this small study both groups profited from ICRS implantation, we can conclude that the central cone group showed, despite the sheer small number of eyes, better results in terms of corneal astigmatic reduction and CDVA relation.



Still in relation to our limitations in this study, we feel that larger prospective studies are required to investigate further the effect of conus location on ICRS outcomes and validate these results.

## CLINICAL SIGNIFICANCE

The ICRS implantation improves visual acuity in both central and inferior keratoconus. Presumably, visual acuity improvement in keratoconus patients who underwent Keraring implantation is not only topographic and keratometric-related but also higher order aberration reduction-dependent.

## REFERENCES

- Burris TE. Intrastromal corneal ring technology: results and indications. *Curr Opin Ophthalmol* 1998 Aug;9(4):9-14.
- Colin J, Cochener B, Savary G, Malet F. Correcting keratoconus with intracorneal rings. *J Cataract Refract Surg* 2000 Aug;26(8):1117-1122.
- Silvestrini TA, Mathis ML, Loomas BE, Burris TE. A geometric model to predict the change in corneal curvature from the intrastromal corneal ring (ICR). *Invest Ophthalmol Vis Sci* 1994;35:2023.
- Burris TE, Baker PC, Ayer CT, Loomas BE, Mathis ML, Silvestrini TA. Flattening of central corneal curvature with intrastromal corneal rings of increasing thickness: an eye-bank eye study. *J Cataract Refract Surg* 1993;19(Suppl 1):182-187.
- Daxer A, Fratzl P. Collagen orientation in the human corneal stroma and its implication in keratoconus. *Invest Ophthalmol Vis Sci* 1997 Jan;38(1):121-129.
- Albertazzi, R. Tratamiento del queratocono con segmentos intracorneales. In: Albertazzi R, editor. *Queratocono: pautas para su diagnóstico y tratamiento*. Buenos Aires: Ediciones científicas argentina para la keratoconus society; 2010. pp. 205-268.
- Coskunseven E, Kymionis GD, Tsiklis NS, Atun S, Arslan E, Jankov MR, Pallikaris IG. One-year results of intrastromal corneal ring segment implantation (KeraRing) using femtosecond laser in patients with keratoconus. *Am J Ophthalmol* 2008 May;145(5):775-779.
- Piñero DP, Alió JL. Intracorneal ring segments in ectatic corneal disease: a review. *Clin Exp Ophthalmol* 2010 Mar;38(2):154-167.
- Vega-Estrada A, Alió JL, Brenner LF, Javaloy J, Plaza Puche AB, Barraquer RI, Teus MA, Murta J, Henriques J, Uceda-Montanes A. Outcome analysis of intracorneal ring segments for the treatment of keratoconus based on visual, refractive, and aberrometric impairment. *Am J Ophthalmol* 2013 Mar;155(3):575.e1-584.e1.
- Kaya V, Utine CA, Karakus SH, Kavadarli I, Yilmaz OF. Refractive and visual outcomes after Intacs vs Ferrara intrastromal corneal ring segment implantation for keratoconus: a comparative study. *J Refract Surg* 2011 Dec;27(12):907-912.
- Giacomin NT, Mello GR, Medeiros CS, Kiliç A, Serpe CC, Almeida HG, Kara-Junior N, Santhiago MR. Intracorneal ring segments implantation for corneal ectasia. *J Refract Surg* 2016 Dec;32(12):829-839.
- Torquetti L, Ferrara G, Almeida F, Cunha L, Araujo LP, Machado A, Marcelo Lyra J, Merayo-Llodes J, Ferrara P. Intrastromal corneal ring segments implantation in patients with keratoconus: 10 year follow-up. *J Refract Surg* 2014 Jan;30(1):22-26.
- Vega-Estrada A, Alió JL, Brenner LF, Burguera N. Outcomes of intrastromal corneal ring segments for treatment of keratoconus: five-year follow-up analysis. *J Cataract Refract Surg* 2013 Aug;39(8):1234-1240.
- Yeung SN, Lichtinger A, Ku JY, Kim P, Low SA, Rootman DS. Intracorneal ring segment explantation after intracorneal ring segment implantation combined with same-day corneal collagen crosslinking in keratoconus. *Cornea* 2013 Dec;32(12):1617-1620.
- Shabayek MH, Alió JL. Intrastromal corneal ring segment implantation by femtosecond laser for keratoconus correction. *Ophthalmology* 2007 Sep;114(9):1643-1652.
- Coskunseven E, Kymionis GD, Tsiklis NS, Atun S, Arslan E, Siganos CS, Jankov M, Pallikaris IG. Complications of intrastromal corneal ring segment implantation using a femtosecond laser for channel creation: a survey of 850 eyes with keratoconus. *Acta Ophthalmol* 2011 Feb;89(1):54-57.
- Sharma M, Boxer Wachler BS. Comparison of single segment and double-segment Intacs for keratoconus and post-LASIK ectasia. *Am J Ophthalmol* 2006 May;141(5):891-895.
- Alió JL, Artola A, Hassanein A, Haroun H, Galal A. One or 2 Intacs segments for the correction of keratoconus. *J Cataract Refract Surg* 2005 May;31(5):943-953.
- Miranda D, Sartori M, Francesconi C, Allemann N, Ferrara P, Campos M. Ferrara intrastromal corneal ring segments for severe keratoconus. *J Refract Surg* 2003 Nov-Dec;19(6):645-653.
- Kwitko S, Severo NS. Ferrara intracorneal ring segments for keratoconus. *J Cataract Refract Surg* 2004 Apr;30(4):812-820.
- Siganos D, Ferrara P, Chatzinikolas K, Bessis N, Papastergiou G. Ferrara intrastromal corneal rings for the correction of keratoconus. *J Cataract Refract Surg* 2002 Nov;28(11):1947-1951.
- Coskunseven E, Kymionis GD, Tsiklis NS, Atun S, Arslan E, Siganos CS, Jankov M, Pallikaris IG. Complications of intrastromal corneal ring segment implantation using a femtosecond laser for channel creation: a survey of 850 eyes with keratoconus. *Acta Ophthalmol* 2011 Feb;89(1):54-57.
- Vega-Estrada A, Alió JL. The use of intracorneal ring segments in keratoconus. *Eye Vis (Lond)* 2016 Mar;3:8.
- Ertan A, Colin J. Intracorneal rings for keratoconus and keratectasia. *J Cataract Refract Surg* 2007 Jul;33(7):1303-1314.
- Alió JL, Shabayek MH, Artola A. Intracorneal ring segments for keratoconus correction: long-term follow-up. *J Cataract Refract Surg* 2006 Jun;32(6):978-985.
- Shetty R, Kurian M, Anand D, Mhaske P, Narayana KM, Shetty BK. Intacs in advanced keratoconus. *Cornea* 2008 Oct;27(9):1022-1029.
- Peña-García P, Alió JL, Vega-Estrada A, Barraquer RI. Internal, corneal, and refractive astigmatism as prognostic factors for intrastromal corneal ring segment implantation in mild to moderate keratoconus. *J Cataract Refract Surg* 2014 Oct;40(10):1633-1644.
- Zare MA, Hashemi H, Salari MR. Intracorneal ring segment implantation for the management of keratoconus: safety and efficacy. *J Cataract Refract Surg* 2007 Nov;33(11):1886-1891.

29. Prakash G, Srivastava D, Choudhuri S, Thirumalai SM, Bacero R. Differences in central and non-central keratoconus, and their effect on the objective screening thresholds for keratoconus. *Acta Ophthalmol* 2016 Mar;94(2): e118-e129.
30. Shetty R, Nuijts RM, Nicholson M, Sargod K, Jayadev C, Veluri H, Sinha Roy A. Cone location-dependent outcomes after combined topography-guided photorefractive keratectomy and collagen cross-linking. *Am J Ophthalmol* 2015 Mar;159(3):419.e2-425.e2.
31. Gatzoufas Z, Panos GD, Elalfy M, Khine A, Hamada S, Lake D, Kozeis N, Balidis M. Effect of conus eccentricity on visual outcomes after intracorneal ring segments implantation in keratoconus. *J Refract Surg* 2018 Mar;34(3):196-200.