

Management of Intrabony Defects using Hydroxyapatite/ β -Tricalcium Phosphate Bone Substitute Alone or Combined with a Collagen Barrier: A Pilot Split-mouth Randomized Clinical Trial

¹Shaleen Khetarpal, ²Unnati Pitale, ³Mishthu Solanki, ⁴Madhu S Ratre, ⁵Manish Verma, ⁶Ruchi Gulati

ABSTRACT

Aim: To determine the clinical efficacy of biphasic hydroxyapatite+ β -tricalcium phosphate (HA/ β -TCP) alone or in the presence of collagen membrane (CM) in the management of intrabony defects.

Materials and methods: Nineteen bilateral intrabony defects with an intrabony component ≥ 4 mm were selected and randomly allocated in a double-blind, split-mouth design to receive either HA/ β -TCP+CM (test) or HA/ β -TCP (control). Analytical parameters measured at baseline and 1 year after surgery included plaque index, gingival index, probing depth (PD), clinical attachment level (CAL), gingival recession (R), radiographic defect depth (RDD), and radiographic percentage bone fill (PBF).

Results: One year after therapy, the test treatment resulted in statistically higher PD reductions ($p < 0.001$) and CAL gains ($p < 0.001$) than the control one. In the test group, all sites (100%) gained at least 3 mm of CAL, whereas in the control group only 10 sites (53%) gained CAL of ≥ 3 mm. The mean radiographic PBF calculated at the end of 1 year was found to be $41.3 \pm 20.6\%$ for the test group and $30 \pm 20.5\%$ for the control group, with a significant ($p = 0.016$) improvement in the PBF for the former.

Conclusion: The present data appear to indicate that treatment with HA/ β -TCP in combination with collagen barrier may result in higher clinical improvements than that achieved with HA/ β -TCP alone.

Keywords: Collagen, Grafts, Guided tissue regeneration, Hydroxyapatite, Membrane.

How to cite this article: Khetarpal S, Pitale U, Solanki M, Ratre MS, Verma M, Gulati R. Management of Intrabony

Defects using Hydroxyapatite/ β -Tricalcium Phosphate Bone Substitute Alone or Combined with a Collagen Barrier: A Pilot Split-mouth Randomized Clinical Trial. *Int J Oral Care Res* 2018; 6(1):38-46.

Source of support: Nil

Conflict of interest: None

INTRODUCTION

Bone substitutes and guided tissue regeneration (GTR) are among the most widely used techniques for the regeneration of tooth-supporting structures.¹ From a biologic point of view, autogenous bone grafts have long been considered as having the greatest potential for osseous regeneration, but it is necessary to harvest the graft from a donor area, which might require a second surgical site. Alternatively, xeno- and allografts have been well documented to be suitable as bone replacement grafts.^{2,3} However, studies^{4,5} frequently state an incomplete resorption of these materials and there is a risk of transmitting diseases by the use of allo- and xenografts.⁶ These have driven the manufacturers to produce clinically beneficial alternatives to graft materials. Bone substitutes, especially alloplastic bone grafts, have filled the niche in periodontal practice, providing biocompatible defect fillers with variable biologic activity. The two most widely used alloplastic substitutes are HA and β -TCP.

Synthetic HA is a slow-resorbing, porous, osteoconductive material having a high compressive strength. It has a close structural and chemical resemblance to bone mineral and offers the potential of bone ingrowth into the micropores and ultimately leads to bone formation.⁷ Beta-TCP is another porous synthetic material with the proportion of calcium and phosphate similar to that of bone. Considering the beneficial properties of HA and β -TCP, i.e., the higher volume stability of the former and the osteoconductive, bioresorbable nature of the latter,⁸ a combination of HA+ β -TCP would theoretically provide a better scaffold for predictable bone volume gain than HA or β -TCP alone.^{9,10}

The major issue with the use of any therapy is its predictability. One of the regenerative techniques, which

¹Lecturer, ^{2,3}Professor, ⁴Reader, ⁵Tutor, ⁶Postgraduate Student

^{1,4}Department of Periodontology, Government College of Dentistry, Indore, Madhya Pradesh, India

²Department of Periodontology, Modern Dental College, Indore Madhya Pradesh, India

³Department of Paediatric Dentistry and Preventive Dentistry Modern Dental College, Indore, Madhya Pradesh, India

^{5,6}Department of Periodontics, Government College of Dentistry Indore, Madhya Pradesh, India

Corresponding Author: Shaleen Khetarpal, Lecturer Department of Periodontology, Government College of Dentistry Indore, Madhya Pradesh, India, Phone: +919827529603, e-mail: drshaleenk@gmail.com

can improve the clinical results, is GTR.¹¹ Collagen barriers have been extensively investigated in various GTR procedures over the years.¹² It offers several advantages but its main disadvantage is that it tends to collapse in large defects if a broad base is not provided and the membrane is not supported.¹³ A bone graft placed under the CM may help support it.

As there is insufficient evidence regarding the use of HA and β -TCP in combination with collagen barrier, the following split-mouth, randomized, double-blind clinical study has been designed to evaluate the clinical efficacy of HA/ β -TCP alone or in combination with a barrier membrane of type 1 collagen derived from bovine Achilles tendon in the management of intra-bony defects.

MATERIALS AND METHODS

Subjects

Twelve patients (nine males and three females, aged 31–40 years, mean age 33.7 ± 3.12 months) having 19 bilateral intra-bony defects in the premolar–molar area were selected from individuals seeking periodontal treatment at the institute hospital (Modern Dental College & Research Centre, Indore and Government College of Dentistry, Indore, India) between January 1, 2007 and October 1, 2017. A total of 38 sites were treated. All patients had a history of chronic periodontitis with advanced loss of periodontal support, characterized by periodontal PD of ≥ 6 mm, CAL > 4 mm, and radiographic evidence of alveolar bone loss.¹⁴ The selected defects exhibited depth of intra-bony component ≥ 4 mm. All subjects were systemically healthy, cooperative, and understood the study protocol. A written consent (approved by the Ethics Committee of the Institute) of all the human subjects who participated in the study was obtained after the nature of the procedure and risks had been fully explained.

Presurgical Treatment

A complete case history was recorded and all subjects received an initial periodontal therapy including plaque control instructions, full-mouth scaling, root planing, and occlusal adjustment, where necessary. Plaque control instructions were repeated until patients achieved plaque scores¹⁵ and gingival index scores¹⁵ of ≤ 1 each. The enrollment of the bilateral sites by random allocation (a coin toss) to the intervention groups (HA/ β -TCP+CM, i.e., test and HA/ β -TCP, i.e., control) was performed by the operator (SK) performing the surgery. All assessments were performed by a masked calibrated examiner (HJD). Training and calibration were conducted prior to the start of the study to ensure intra- and extra-examiner

reproducibility. The calibration was done by examining a few patients and comparing with gold standard examiner (UP). All patients were also masked to the different treatment allocation.

Analytical Parameters

Full-mouth plaque score, gingival index, probing PD, R, and CAL were recorded at baseline and 1 year. All the measurements were recorded with a manual pressure-sensitive periodontal probe, calibrated at a force of 0.2 N with UNC-15 markings. Occlusal acrylic stents with longitudinal grooves were fabricated for all the patients to standardize the periodontal probe angulation and position.¹⁶ The cemento-enamel junction (CEJ) was used as the fixed reference point. In cases where the CEJ was not clearly visible, the lower border of the groove on acrylic stent that covered the experimental tooth was used.

The intra-bony defect depth (IDD) was measured during the surgery from the most coronal extension of bone crest to the deepest level of the defect. The bony defects were also classified as one-, two-, or three-wall defects depending on their topography in the vertical direction.

Radiographic Analysis

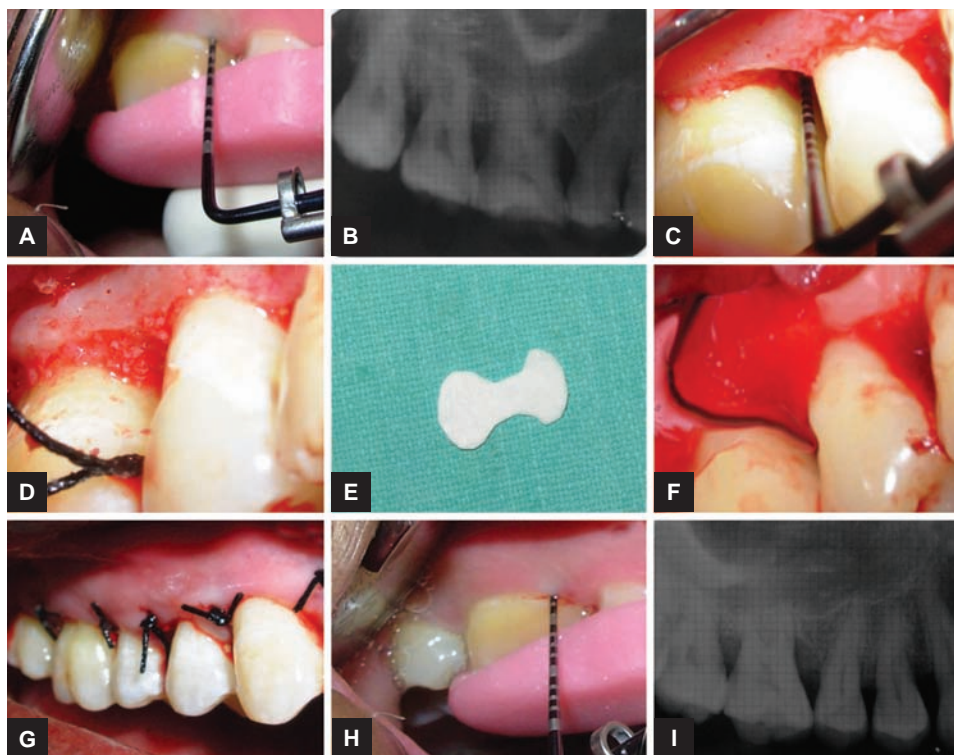
An intraoral periapical (IOPA) radiograph was taken of each selected site with long-cone paralleling technique using film-holding devices to measure the RDD. Radiographic measurements were obtained utilizing a film mount with millimeter grid scale. The grid scale lines are printed at 1 mm intervals with bold lines at 5 mm intervals. The developed IOPA film was inserted in the mount to measure the defect depth at baseline and after 1 year. Vertical linear distances between the CEJ and the apical most part of the defect were obtained by mounting the radiograph on the grid and counting the number of squares (each square = 1×1 mm). The radiographic PBF was also calculated for each defect. The percentage of change for the linear measurement radiographically was calculated¹⁷ as:

$$\text{PBF} = \frac{\text{Preoperative Measurement} - \text{Postoperative Measurement}}{\text{Preoperative Measurement}} \times 100$$

Surgical Procedure

Test Group (HA/ β -TCP+CM)

After recording of the baseline parameters (Figs 1A and B), local anesthesia was administered and an access full-thickness flap was reflected. The osseous defect was debrided and their depth was measured and classified depending on the number of bony walls present (Fig. 1C).



Figs 1A to I: Management of test site. (A) Preoperative view of the test site showing occlusal stent and pressure-sensitive probe. The PD is 6 mm on mesial of first molar. (B) Baseline radiograph showing intrabony defect with first molar. (C) Clinical view of a three-walled intrabony defect on flap reflection and debridement. (D) Bone grafting done. (E) The trimmed collagen barrier. (F) Membrane placed to cover the defect and overlap the alveolar bony walls. (G) Flap approximated and sutured. (H) One-year postoperative view showing PD reduced to 2 mm. (I) Postoperative radiograph. Note the reduction in the defect depth

Presuturing was done with 3-0 Mersilk and the defect was packed with the bone graft material, which was hydrated with saline (Fig. 1D). Care was taken not to overfill the osseous defects. The CM was trimmed (Fig. 1E) in such a way that it overlapped the alveolar bony walls of the defect by at least 2 mm. It was folded in half and passed interproximally beneath the interdental contacts. The dense smooth surface faced the soft tissue and the rough side faced the bone. It was applied over the defect and was held in place with moderate pressure. No sutures were used for stabilization of the membrane (Fig. 1F). The mucoperiosteal flaps were approximated and sutured to their original position using interdental interrupted sutures (Fig. 1G). The surgical site was dressed with a periodontal dressing, on the buccal and lingual aspects without application of excessive pressure interdentally. Figures 1H and I illustrate 1-year postoperative clinical and radiographic views of the treated site respectively.

Control Group (HA/ β -TCP)

A procedure identical to that used for the test site was performed for the HA/ β -TCP group sites (Figs 2A to D). However, in this group, the bone graft was placed alone without the collagen barrier. Figures 2E and F show the

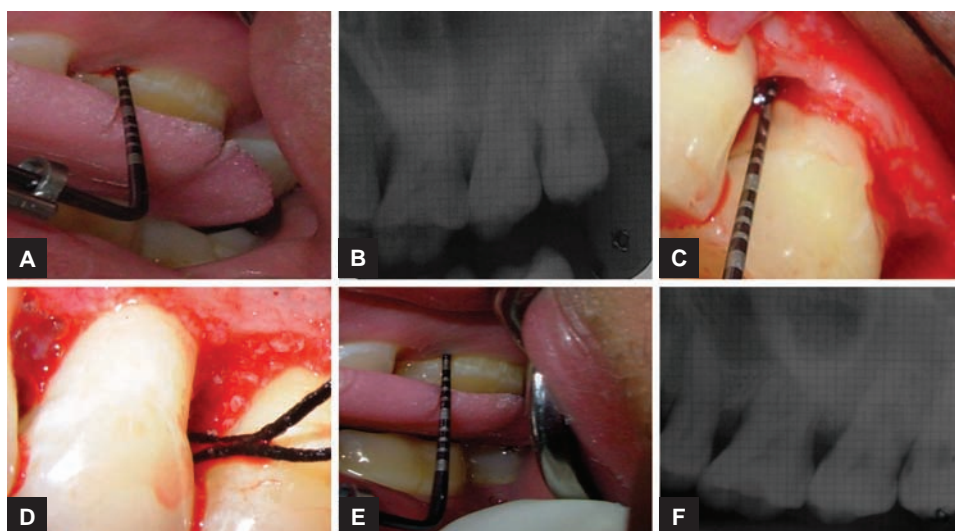
1-year postoperative clinical and radiographic view of the control site respectively.

Postoperative Care and Follow-up

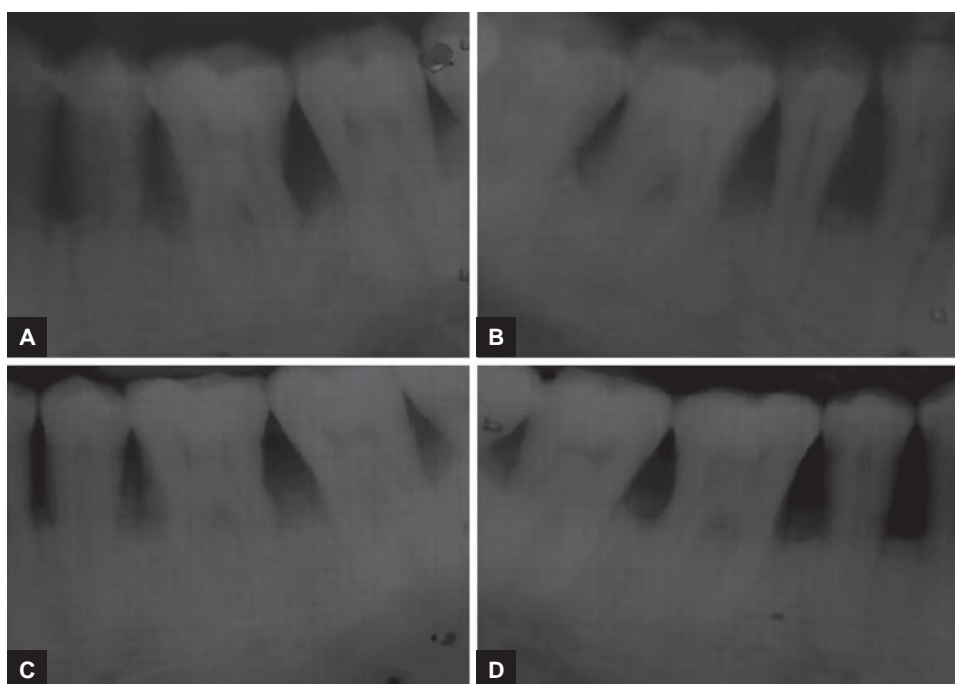
Postoperative care and plaque control instructions were given and analgesics (a combination of ibuprofen 325 mg and paracetamol 400 mg) prescribed. Periodontal dressing and sutures were removed after 7 days postsurgery. The patients were recalled every 3 months for the first year postsurgery when they received full-mouth professional prophylaxis. A complete postoperative evaluation was performed of the test and control sites at the end of 1 year (Figs 3 and 4). The clinical and radiographic data obtained were tabulated and statistical analysis was carried out.

Statistical Analysis

Descriptive statistics were computed for each parameter recorded at baseline and 1 year postsurgery for both the groups. Student's paired t-test was used to compare the data from the baseline to those at 1 year for each treatment group and between treatment groups at baseline and 1 year postsurgery. The level of significance of 0.05 was employed for all statistical comparisons.



Figs 2A to F: Management of control site. (A) Preoperative view of the control site showing occlusal stent and pressure-sensitive probe. The PD is 6 mm on mesial of the first molar. (B) Baseline radiograph showing intrabony defect with first molar. (C) Clinical view of a three-walled intrabony defect on flap reflection and debridement. (D) Bone grafting done. (E) One-year postoperative view showing PD reduced to 4 mm. (F) Postoperative radiograph. Note the reduction in the defect depth

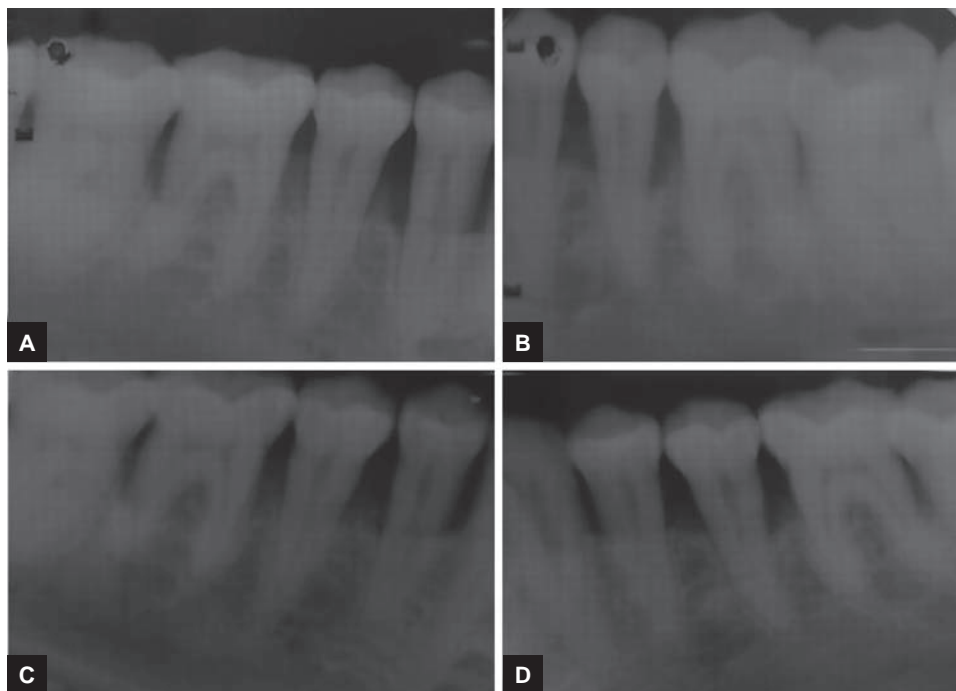


Figs 3A to D: Preoperative and postoperative radiographs of case 2. (A) Preoperative radiograph of test site showing angular defect with mandibular left first molar. (B) Preoperative radiograph of control site showing angular defects with mandibular right first molar. (C) One-year postoperative radiographs of the test site showing bone fill on the distal of the mandibular left first molar. (D) One-year postoperative radiographs of the control site showing bone fill on the mesial of the mandibular right first molar

Sample Size Calculation

Prior to the initiation of this study, power calculations performed indicated that a sample size of 17 evaluable sites was needed to detect a difference of 2.0 mm in change in attachment level with power of 80% and allowing α error of 0.05. The calculations were based on the assumptions

that equal number of subjects would be allotted to the test and control groups and the primary outcome variable would be gain in clinical attachment (continuous), the standard deviation (SD) of which was around 2.0 mm (estimated from previous studies with similar inclusion/exclusion criteria). A total sample size of 19 was taken to compensate for any loss to follow-up.



Figs 4A to D: Preoperative and postoperative radiographs of case 3. (A, B) Preoperative radiographs of test and control sites showing angular defects. (C, D) One-year postoperative radiographs of the test and control sites showing bone fill

Table 1: Baseline defect characteristics of test and control sites expressed in mm (n = 19 for each group)

Treatment	PD (mm) (mean ± SD)	CAL (mm) (mean ± SD)	R (mm) (mean ± SD)	IDD (mm) (mean ± SD)
HA/β-TCP+CM	7.579 (±1.953)	8.000 (±1.795)	0.474 (±0.513)	4.579 (±0.769)
HA/β-TCP	6.789 (±0.787)	7.263 (±0.733)	0.526 (±0.697)	4.474 (±0.697)

Table 2: Distribution of the type of defects (n = 19 for each group)

Type of defect	HA/β-TCP+CM group (No. of sites)	HA/β-TCP group (No. of sites)
Three-wall defects	10	8
Two-wall defects	6	6
One-wall defect	3	5

RESULTS

All patients completed the study. Healing was uneventful in all treatment groups. Baseline defect characteristics of the test and control sites are presented in Table 1. At baseline, no differences in the initial depth of the intrabony defects were found between the two groups. Likewise, there was no difference in the distribution of one-, two-, and three-wall defects among the groups as illustrated in Table 2.

The clinical parameters at baseline and 1 year after treatment are presented in Table 3. The scores of hygiene indices in both groups remained low throughout the study period. At 1 year after therapy, the test group showed a reduction in the mean PD from 7.579 ± 1.953 to 2.684 ± 0.82 mm and a change in the mean CAL from 8.0 ± 1.795 to 3.316 ± 1.204 mm. In the control group, the mean PD was reduced from 6.789 ± 0.787 to 4.316 ± 0.946 mm

and the mean CAL changed from 7.263 ± 0.733 to 5.000 ± 1.155 mm. The test treatment resulted in statistically higher PD reductions (p < 0.001) and CAL gains (p < 0.001) than the control one. In the test group, the RDD reduced from 5.842 ± 1.772 to 3.421 ± 1.502 mm with a mean radiographic defect fill of 2.421 mm at the end of 1 year, while for the HA / β-TCP group, RDD reduced from 5.000 ± 1.599 to 3.316 ± 1.003 mm with a mean defect fill of 1.684 mm. This difference was significant within the groups; however, between the groups it was not significant.

The frequency distribution of CAL gain for both treatment groups is shown in Table 4. In the test group, all sites (100%) gained at least 3 mm of CAL. In this group, a CAL gain of 3 to 4 mm was measured at 12 sites (63%), whereas at 7 sites (37%), the CAL gain was >5 mm. In the control group, no CAL gain occurred at two sites (11%), whereas at seven sites (36%), the CAL gain was only 1 to 2 mm. A CAL gain of 3 to 4 mm was measured in the remaining 10 defects (53%).

For the test group, the PBF scores ranged from 0.0 to 100% with a mean of 41.3% and for the control group it was between 0.0 and 60% with a mean of 30.0% (Table 5). When the mean PBF scores of both the treatment groups were compared at the end of 1 year, it was found to be



Table 3: Clinical parameters of test and control groups over time (n = 19 for each group)

Parameter	Baseline (mean ± SD)	One year (mean ± SD)	Difference	Within groups (p*)
<i>Plaque index</i>				
HA/β-TCP+CM	0.735 (±0.059)	0.711 (±0.096)	-0.024	0.346
HA/β-TCP	0.765 (±0.072)	0.745 (±0.124)	-0.020	0.557
Between groups (p*)	0.174	0.341		
<i>Gingival index</i>				
HA/β-TCP+CM	0.755 (±0.080)	0.736 (±0.082)	-0.019	0.476
HA/β-TCP	0.750 (±0.077)	0.730 (±0.086)	-0.020	0.457
Between groups (p*)	0.838	0.818		
<i>Probing depth (mm)</i>				
HA/β-TCP+CM	7.579 (±1.953)	2.684 (±0.820)	-4.895	<0.001
HA/β-TCP	6.789 (±0.787)	4.316 (±0.946)	-2.473	<0.001
Between groups (p*)	0.111	<0.001		
<i>CAL (mm)</i>				
HA/β-TCP+CM	8.000 (±1.795)	3.316 (±1.204)	-4.684	<0.001
HA/β-TCP	7.263 (±0.733)	5.000 (±1.155)	-2.263	<0.001
Between groups (p*)	0.106	<0.001		
<i>Recession (mm)</i>				
HA/TCP+CM	-0.474 (±0.513)	-0.579 (±0.962)	+0.105	0.597
HA/β-TCP	-0.526 (±0.697)	-0.737 (±0.733)	+0.211	0.370
Between groups (p*)	0.792	0.499		
<i>DD (mm)</i>				
HA/β-TCP+CM	5.842 (±1.772)	3.421 (±1.502)	-2.421	<0.001
HA/β-TCP	5.000 (±1.599)	3.316 (±1.003)	-1.684	<0.001
Between groups (p*)	0.132	0.801		

*Paired t-test

Table 4: Frequency distribution of CAL gain in the test and control groups (n = 19 for each group)

CAL gain (mm)	HA/β-TCP+CM		HA/β-TCP	
	No.	%	No.	%
0	0	0	2	11
1	0	0	3	15
2	0	0	4	21
3	2	11	8	42
4	10	52	2	11
5	4	21	0	0
6	1	5	0	0
>7	2	11	0	0

statistically significant (p = 0.016) for the HA/β-TCP+CM group as compared with HA/β-TCP group, thereby indicating a significantly greater PBF for the former group.

DISCUSSION

The periodontal literature mentions a variety of bone substitutes^{2-4,7,9,11,17-27} being used; however, the search for the optimal bone graft continues. The bone graft used in the present study is a combination of HA and β-TCP in a ratio of 70/30. It has 90% interconnected porosity, i.e., when placed in the defect it occupies only 10% of the defect space leaving 90% space for regeneration. It has a particle size of 0.25 to 1 mm. A smaller particle or larger pore size may be preferred to allow more rapid

Table 5: The mean PBF for the treatment groups (n = 19 for each group)

HA/β-TCP + CM (%)			HA/β-TCP (%)			p*-value
Mean ± SD	Min.	Max.	Mean ± SD	Min.	Max.	
41.3 ± 20.6	0.00	100.0	30.0 ± 20.5	0.0	60.0	0.016

* Paired t-test; Min: Minimum; Max: Maximum

bioabsorption, greater surface area, and increased osteogenesis.²⁸

Hydroxyapatite and β-TCP individually have shown significant clinical improvements in grafted sites compared with non-grafted sites in controlled clinical studies.¹⁸⁻²⁰ Animal studies have shown that β-TCP is compatible with host tissues^{29,30} and enhances bone deposition by triggering macrophages.³¹ The combination of HA and β-TCP with the resultant development of biphasic calcium phosphate has made it possible to control the resorbability of the material and at the same time maintain its osteoconductive property. Also, as it has no organic component, it is biocompatible, making it a safe material.

In the present study, the CM used is a bi-textured, resorbable, nonfriable membrane engineered from highly purified type 1 collagen derived from bovine Achilles tendon. Exogenous collagen is chemotactic for periodontal ligament fibroblasts and improves fibroblast migration and attachment through its scaffold-like

fibrillar structure.³² It also creates a thrombogenic surface that stimulates platelet attachment, which may accelerate fibrin and clot attachment.³³ These biological properties of collagen may aid in periodontal reconstructive procedures. When bone grafts are used in conjunction with GTR, they serve as good space makers and create an environment favorable for clot stabilization.²¹ The combination therapy is an approach aimed at combining the positive aspects of different regenerative principles in order to possibly enhance the healing.²²

The purpose of this split-mouth randomized clinical trial was to compare the clinical efficacy of the HA/ β -TCP bone substitute alone or combined with collagen barrier in the treatment of intrabony defects. To the best of our knowledge, there is no study in the literature comparing the effect of use of collagen barrier in combination with biphasic HA/ β -TCP vs HA/ β -TCP alone in the management of bilateral intrabony defects. Due to this lacunae in knowledge, comparisons were carried out with studies using similar bone substitute or with other bone graft-membrane studies.

One of the primary goals of periodontal therapy is to reduce the PD in order to limit the risk of local reinfection. At 1 year following therapy, the results of test group revealed a mean PD reduction of 4.895 mm and mean CAL gain of 4.684 mm while the control group showed mean PD reduction of 2.473 mm and mean CAL gain of 2.263 mm. The test group provided significantly ($p < 0.001$) greater PD reductions and CAL gains than the control sites. The results are in accordance with studies, which report that bone grafts in combination with membranes produce superior results.^{24,25}

The bone fill obtained was similar to or slightly less than other similar studies,^{11,26} but no definitive comparisons can be made due to the difference in bone graft material. The mean radiographic PBF calculated at the end of 1 year was 41.3% for the test group and 30% for the control group, with a statistically significant improvement for the former. The PBF is a more sensitive and reliable indicator of bone fill than defect depth as it shows amount of bone fill in relation to the initial depth of defect in terms of percentage without considering the discrepancy in the initial linear defect depth. Direct bone measurement, both linear and volumetric, by re-entry methods is frequently used as the primary endpoint variables in clinical trials of regenerative therapy. But a major disadvantage of this method is the need for a second surgical procedure to visualize the osseous defects; also it does not show the type of attachment that exists, i.e., long junctional epithelium or new attachment. To overcome this difficulty, radiographic monitoring of alveolar bone changes has been preferred in our study. Radiographic bone measurement is noninvasive, painless alternative to direct bone measurements.¹⁷

The favorable results observed in this study may be due, in part, to the defect shape. In our study, the majority of the defects were three-walled. A high potential of three-walled defects for bone regeneration, irrespective of the treatment modality used, has been previously reported.^{34,35} According to Selvig et al³⁶ and Tonetti et al,³⁷ the defects with greatest amounts of depth at baseline have greatest amounts of probing PD reductions, attachment gains, and bone fill.

The most reliable outcome variable for assessing periodontal regeneration is human histology. Because histologic specimens were not obtained in this study due to ethical considerations and patient management limitations, inferences about the quality of bone formation at any given time-point or the type of healing attachment gained cannot be made. Previous findings do indicate that the use of grafts or GTR or the combined use of both techniques may result in the formation of new histologic attachment.^{3,38}

However, there is no histologic evidence that synthetic graft materials support periodontal regeneration.

Another limitation of the present clinical study may lie in the fact that the sample size was small. Multiclinical trials with long-term analysis and larger sample sizes are required to determine the stability of the results. Ethical considerations and patient non-acceptance restricted direct bone measurements. The existence of an unknown bias cannot be excluded, although statistical analysis revealed that no significant difference in baseline parameters existed between the treatment groups. Nevertheless, attempts were made to minimize any bias as far as possible. Possible confounder like smoking was eliminated by selecting only nonsmokers in the study. The defect depth was standardized, and teeth exhibiting confounding factors, such as restorations in the defect area or furcation involvement, were excluded from the study.

REFERENCES

1. Rosenberg E, Rose LF. Biologic and clinical considerations for autografts and allografts in periodontal regeneration therapy. *Dent Clin North Am* 1998 Jul;42(3):467-490.
2. Bowers GM, Chadroff B, Carnevale R, Mellonig J, Corio R, Emerson J, Stevens M, Romberg E. Histologic evaluation of new attachment apparatus formation in humans. Part II. *J Periodontol* 1989 Dec;60(12):675-682.
3. Camelo M, Nevins M, Schenk R, Simion M, Rasperini G, Lynch SE, Nevins M. Clinical, radiographic, and histologic evaluation of human periodontal defects treated with Bio-Oss and Bio-Gide. *Int J Periodontics Restorative Dent* 1998 Aug;18(4):321-331.
4. Caplanis N, Lee MB, Zimmerman GJ, Selvig KA, Wikesjö UM. Effect of allogenic freeze-dried demineralized bone matrix on regeneration of alveolar bone and periodontal attachment in dogs. *J Clin Periodontol* 1998 Oct;25(10):801-806.

5. Yildirim M, Spiekermann H, Biesterfeld S, Edelhoff D. Maxillary sinus augmentation using xenogenic bone substitute material Bio-Oss in combination with venous blood. A histologic and histomorphometric study in humans. *Clin Oral Implants Res* 2000 Jun;11(3):217-229.
6. Sogal A, Tofe AJ. Risk assessment of bovine spongiform encephalopathy transmission through bone graft material derived from bovine bone used for dental applications. *J Periodontol* 1999 Sep;70(9):1053-1063.
7. Kenney EB, Lekovic V, Sa Ferreira JC, Han T, Dimitrijevic B, Carranza FA Jr. Bone formation within porous hydroxyapatite implants in human periodontal defects. *J Periodontol* 1986 Feb;57(2):76-83.
8. Jensen SS, Brogkini N, Hjørtting-Hansen E, Schenk R, Buser D. Bone healing and graft resorption of autograft, anorganic bovine bone and beta-tricalcium phosphate. A histologic and histomorphometric study in the mandibles of minipigs. *Clin Oral Implants Res* 2006 Jun;17(3):237-243.
9. Nery EB, LeGeros RZ, Lynch KL, Lee K. Tissue response to biphasic calcium phosphate ceramic with different ratios of HA/beta TCP in periodontal osseous defects. *J Periodontol* 1992 Sep;63(9):729-735.
10. Hashimoto-Uoshima M, Ishikawa I, Kinoshita A, Weng HT, Oda S. Clinical and histologic observation of replacement of biphasic calcium phosphate by bone tissue in monkeys. *Int J Periodontics Restorative Dent* 1995 Apr;15(2):204-213.
11. Kiliç RA, Efeoglu E, Yılmaz S. Guided tissue regeneration in conjunction with hydroxyapatite-collagen grafts for intrabony defects. A clinical and radiological evaluation. *J Clin Periodontol* 1997 Jun;24(6):372-383.
12. Al-Arrayed F, Adam S, Moran J, Powell P. Clinical trial of cross-linked human collagen type 1 collagen as a barrier material in surgical periodontal treatment. *J Clin Periodontol* 1995 May;22(5):371-379.
13. Bunyaratavej F, Wang HL. Collagen membranes: a review. *J Periodontol* 2001 Feb;72(2):215-229.
14. American Academy of Periodontology. Parameter on chronic periodontitis with advanced loss of periodontal support. *J Periodontol* 2000;71(5 Suppl):856-858.
15. Løe H. The gingival index, the plaque index and the retention index systems. *J Periodontol* 1967 Nov-Dec;38(6):610-616.
16. Clark DC, Quee TC, Bergeron MJ, Chan ECS, Lautar-Lemay C, De Gruchy K. Reliability of attachment level measurements using the cemento-enamel junction and a plastic stent. *J Periodontol* 1987 Feb;58(2):115-118.
17. Vouros I, Aristodimou E, Konstantinidis A. Guided tissue regeneration in intrabony periodontal defects following treatment with two bioabsorbable membranes in combination with bovine bone mineral graft. A clinical and radiographic study. *J Clin Periodontol* 2004 Oct;31(10):908-917.
18. Döri F, Arweiler N, Gera I, Sculean A. Clinical evaluation of an enamel matrix protein derivative combined with either a natural bone mineral or beta-tricalcium phosphate. *J Periodontol* 2005;76:2236-2243.
19. Meffert RM, Thomas JR, Hamilton KM, Brownstein CN. Hydroxyapatite as an alloplastic graft in the treatment of human periodontal osseous defects. *J Periodontol* 1985 Feb;56(2):63-73.
20. Yukna RA, Harrison BG, Caudill RF, Evans GH, Mayer ET, Miller S. Evaluation of durapatite ceramic as an alloplastic implant in periodontal osseous defects. II. Twelve month re-entry results. *J Periodontol* 1985 Sep;56(9):540-547.
21. Batista EL Jr, Novaes AB, Simonpietri JJ, Batista FC. Use of bovine derived anorganic bone associated with guided tissue regeneration in intrabony defects. Six-month evaluation at re-entry. *J Periodontol* 1999 Sep;70(9):1000-1007.
22. Tonetti MS, Cortellini P, Lang NP, Suvan JE, Adriaens P, Dubravec D, Fonzar A, Fourmouis I, Rasperini G, Rossi R, et al. Clinical outcomes following treatment of human intrabony defects with GTR/bone replacement material or access flap alone. A multicenter randomized controlled clinical trial. *J Clin Periodontol* 2004 Sep;31(9):770-776.
23. Chen CC, Wang HL, Smith F, Glickman GN, Shyr Y, O'Neal RB. Evaluation of a collagen membrane with and without bone grafts in treating periodontal intrabony defects. *J Periodontol* 1995 Oct;66(10):838-847.
24. Lekovic V, Camargo PM, Weinlaender M, Vasilic N, Kenney EB. Comparison of platelet-rich plasma, bovine porous bone mineral and GTR versus platelet-rich plasma and bovine porous bone mineral in the treatment of intrabony effects: a reentry study. *J Periodontol* 2002 Feb;73(2):198-205.
25. Reynolds MA, Aichelmann-Reidy ME, Branch-Mays GL, Gunsolley JC. The efficacy of bone replacement grafts in the treatment of periodontal osseous defects. A systematic review. *Ann Periodontol* 2003 Dec;8(1):227-265.
26. Yassibag-Berkman Z, Tuncer O, Subasioglu T, Kantarci A. Combined use of platelet rich plasma and bone grafting with or without guided tissue regeneration in the treatment of anterior interproximal defects. *J Periodontol* 2007 May;78(5):801-809.
27. Orsini M, Orsini G, Benlloch D, Aranda JJ, Sanz M. Long term clinical results on the use of bone replacement grafts in the treatment in intrabony periodontal defects. Comparison of the use of autogenous bone graft plus calcium sulfate to autogenous bone graft covered with a bioabsorbable membrane. *J Periodontol* 2008 Sep;79(9):1630-1637.
28. Shapoff CA, Bowers GM, Levy B, Mellonig JT, Yukna RA. The effect of particle size on the osteogenic activity of composite grafts of allogenic freeze-dried bone and autogenous marrow. *J Periodontol* 1980 Nov;51(11):625-630.
29. Levin MP, Getter L, Adrian J, Cutright DE. Healing of periodontal defects with ceramic implants. *J Clin Periodontol* 1974 Dec;1(4):197-205.
30. Nery EB, Lynch KL, Hirthe WM, Mueller KH. Bioceramic implants in surgically produced intrabony defects. *J Periodontol* 1975 Jun;46(6):328-347.
31. Langstaff S, Sayer M, Smith TJ, Pugh SM, Hesp SM, Thompson WT. Resorbable bioceramics based on stabilized calcium phosphates. Part I: Rational design, sample preparation and material characterization. *Biomaterials* 1999 Sep;20(18):1727-1741.
32. Postlethwaite AE, Seyer JM, Kang AH. Chemotactic attraction of human fibroblasts to type I, II, and III collagens and collagen-derived peptides. *Proc Natl Acad Sci (USA)* 1978 Feb;75(2):871-875.
33. Steinberg AD, LeBreton G, Willey R, Mukherjee S, Lipowski J. Extravascular clot formation and platelet activation on variously treated root surfaces. *J Periodontol* 1986 Aug;57(8):516-622.
34. Kim CS, Choi SH, Chai JK, Cho KS, Moon IS, Wikesjö UME, Kim CK. Periodontal repair in surgically created intrabony defects in dogs: influence of the number of bone walls on healing response. *J Periodontol* 2004 Feb;75(2):229-35.

35. Cortellini P, Pini Prato G, Tonetti MS. Periodontal regeneration of human intrabony defects. II. Re-entry procedures and bone measures. *J Periodontol* 1993 Apr;64(4):261-268.
36. Selvig KA, Kersten BG, Wikesjö UME. Surgical treatment of intrabony periodontal defects using expanded polytetrafluoroethylene barrier membranes: influence of defect configuration on healing response. *J Periodontol* 1993 Aug;64(8):730-733.
37. Tonetti MS, Pini Prato G, Cortellini P. Periodontal regeneration of human intrabony defects. IV. Determinants of healing response. *J Periodontol* 1993 Oct;64(10):934-940.
38. Nevins ML, Camelo M, Lynch SE, Schenk RK, Nevins M. Evaluation of periodontal regeneration following grafting intrabony defects with Bio-Oss collagen: a human histologic report. *Int J Periodontics Restorative Dent* 2003 Feb;23(1): 9-17.