

# Cutaneous Manifestations in Internal Malignancy

Navtej Singh

## ABSTRACT

**Introduction:** The skin is a mirror of the internal milieu of the body. As with other systemic disorders, many internal malignancies can be reflected in this mirror, provided we look carefully enough. Internal malignancies may lead to cutaneous manifestations in a number of ways. The tumor may invade the skin directly or do so by way of lymphatic or hematogenous dissemination, thereby giving rise to deposits in the skin (cutaneous metastases). As is evident from the foregoing, a knowledge of cutaneous manifestations in various internal malignancies can be extremely helpful in making a diagnosis, gauging the extent of the disease, assessing the progress and response to therapy of a neoplasm besides enabling one to prognosticate.

**Materials and methods:** The study comprised 225 cases with internal malignant disease of varying types and duration and involving different organs and organ systems, recorded over a period of 1 year and 8 months. A thorough history and examination with relevant laboratory investigations with skin biopsy were carried out where indicated.

**Results:** The patients studied comprised 130 males (58%) and 95 females (42%) with maximum number of patients in the age group of 61 years and above. Mucocutaneous manifestations were seen in 52 (23%) patients in the present study with a total of 73 skin lesions of various types. Specific skin lesions were seen in 11 patients, paraneoplastic skin syndromes/nonspecific skin lesions were seen in 27, genetic syndromes denoting increased susceptibility to cancer in 1 and skin lesions due to cancer therapy in 21 patients; 14 (8.6%) out of 163 patients given chemotherapy showed adverse effects of chemotherapy; 7 patients (7.1%) out of a total of 98 given radiotherapy showed features of radiodermatitis in the present work.

**Keywords:** Cutaneous, Malignancy, Metastases.

**How to cite this article:** Singh N. Cutaneous Manifestations in Internal Malignancy. *Int J Adv Integ Med Sci* 2017;2(4):161-168.

**Source of support:** Nil

**Conflict of interest:** None

## INTRODUCTION

The skin is a mirror of the internal milieu of the body. As with other systemic disorders, many internal malignancies can be reflected in this mirror, provided we look

carefully enough. Recognition of a skin lesion known or even suspected to have an association with one or more internal malignancies, such as a migratory erythema, acanthosis nigricans, or a painless nodule can lead to the discovery of a hitherto unknown neoplasm.

Internal malignancies may lead to cutaneous manifestations in a number of ways, e.g., carcinomas can influence the skin by substances that are produced by the tumor itself, such as hormones, tumor proteins, tumor necrosis products, or growth factors.<sup>1</sup> The tumor may invade the skin directly or by way of lymphatic or hematogenous dissemination, thereby giving rise to deposits in the skin (cutaneous metastases).

Exposure to a carcinogen may result in both skin lesions and the development of a malignancy, e.g., arsenic may induce palmoplantar keratosis as well as lead to the development of a malignancy, especially carcinoma of the lung. A heritable disorder like ataxia telangiectasia has skin lesions (telangiectasia) as one of its manifestations and has a definite association with internal malignancy, especially leukemia.<sup>2</sup> Bone marrow suppression caused by many a malignancy in the advanced stage can lead to purpura and increased incidence of infections and infestations among other manifestations.

In addition, therapy in the form of radiotherapy and/or chemotherapy exhibited to a patient with internal malignancy can lead to a variety of mucocutaneous manifestations including alopecia, hyperpigmentation, oral ulcers, or skin atrophy, among many others.<sup>3-5</sup>

As is evident from the foregoing, a knowledge of cutaneous manifestations in various internal malignancies can be extremely helpful in making a diagnosis, gauging the extent of the disease, assessing the progress and response to therapy of a neoplasm besides enabling one to prognosticate.

## MATERIALS AND METHODS

### Materials

The material for this study comprises 225 cases with internal malignant disease of varying types and durations and involving different organs and organ systems, recorded over a period of 1 year and 8 months from May 2000 to Jan 2002 who were hospitalized in the Malignant Diseases Treatment Centre, Command Hospital, Pune (MDTC, CH [SC], Pune), India. Some patients, who were investigated

Head

Department of Dermatology, Command Hospital (Western Command), Panchkula, Haryana, India

**Corresponding Author:** Navtej Singh, Head, Department of Dermatology, Command Hospital (Western Command) Panchkula, Haryana, India, e-mail: navtej07@gmail.com

**Table 1:** Cutaneous manifestations and internal malignancies

Internal malignancy	No. of cases					
	Males		Females		Total (combined)	No. with skin lesions (%)
	Total	No. with skin manifestations (%)	Total	No. with skin manifestations (%)		
Carcinoma of oral cavity	16	5 (31.2)	5	2 (40.0)	21	7 (33.3)
Carcinoma of upper respiratory tract	13	3 (23.1)	2	–	15	3 (20.0)
Carcinoma of the lung	12	2 (16.7)	2	–	14	2 (14.3)
Carcinoma of gastrointestinal tract	11	1 (9.1)	7	–	18	1 (5.6)
Carcinoma of breast	–	–	21	6 (28.6)	21	6 (28.6)
Carcinoma of cervix	–	–	26	5 (19.2)	26	5 (19.2)
Carcinoma of ovary	–	–	6	1 (16.7)	6	1 (16.7)
Carcinoma of testis	6	1 (16.7)	–	–	6	1 (16.7)
Carcinoma of liver and GB	5	3 (60.0)	1	–	6	3 (50.0)
Adenocarcinoma maxilla	–	–	2	1 (50.0)	2	1 (50.0)
Carcinoma of penis	3	1 (33.3)	–	–	3	1 (33.3)
Carcinoma of bladder	4	1 (25.0)	–	–	4	1 (25.0)
Bone sarcomas	9	1 (11.1)	6	2 (33.3)	15	3 (20.0)
Soft tissue sarcomas	8	2 (25.0)	2	–	10	2 (20.0)
Leukemias	14	4 (28.5)	6	3 (50.0)	20	7 (35.0)
Lymphomas	14	4 (29.6)	4	1 (25.0)	18	5 (27.8)
CNS tumors	15	3 (20.0)	5	–	20	3 (15.0)
Total	103	31 (23.8)	95	21 (22.1)	225	52 (23.1)

CNS: Central nervous system

for a malignancy on account of skin lesions that warranted such investigation but were found not to have any internal malignancy, were excluded from this study.

## Methodology

- History and examination. A thorough history was taken and relevant systemic and dermatological examination was carried out.
- Laboratory investigations. Results that confirmed the extent and diagnosis of internal malignancy were carried out.
- Skin biopsy. Skin biopsy was carried out to confirm the clinical diagnosis where it was indicated.

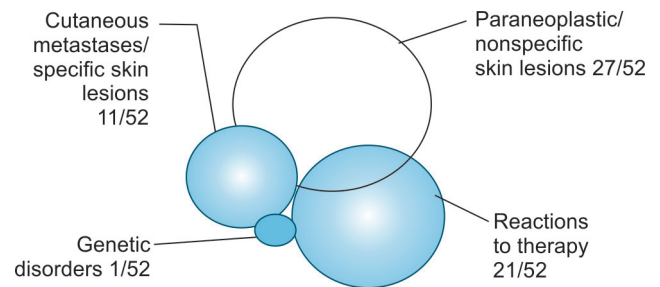
## RESULTS

### Age and Sex Distribution of Patients

A total of 225 patients with various malignancies were studied; 130 (58%) were males and 95 (42%) were females. The mean age of the patients was 45.6 years (4–75 years).

### Cutaneous Manifestations and Internal Malignancies

The incidence of cutaneous manifestations seen in various internal malignancies is as shown in Table 1. Carcinoma oral cavity (7.21, 33.3%) and leukemias (7.20, 35.0%) were the malignancies with the highest number of cutaneous manifestations, while 28.6% (6/21) of breast cancers gave rise to skin lesions.

**Flow Chart 1:** Types of skin lesions

### Types of Skin Lesions

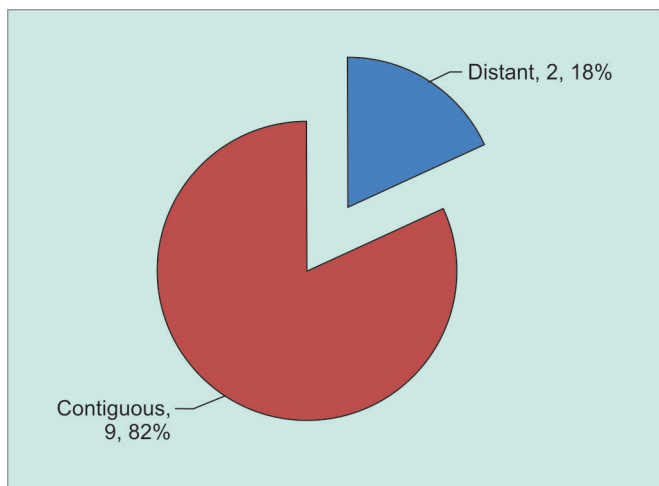
A total of 73 skin lesions of various types were seen in 52 (23.1%) patients of internal malignancy (Flow Chart 1), because of the disease itself or as a consequence of therapy or both.

### Cutaneous Metastases/Specific Lesions

Cutaneous metastases/specific skin lesions were seen in 11 (4.9%) patients. Out of these 11, 9 (82%) patients had contiguous or local metastases, while 2 (18%) patients had distant metastases (Graph 1); 7 (63.6%) of these 11 patients were males and 4 (36.4%) were females.

The commonest site of localization of these skin deposits in this study was the chest (39%) followed by the head neck (37%), abdomen (12%), extremities (8%) and the back and external genitalia (2% each).

In addition, while carcinoma of the oral cavity was the most common cause of cutaneous metastases in males,



Graph 1: Cutaneous metastases

i.e., in 3 (42.9%) out of 7 cases, in females, breast cancer was the most common cause, accounting for 3 (75.0%) of the 4 female cases with skin metastases.

**The Genetic Group**

One case (0.44%) had Gardner’s syndrome who developed multiple polyposis of the colon with adenocarcinoma of the descending colon.

**Paraneoplastic Cutaneous Syndromes/ Nonspecific Skin Lesions**

A total of 36 paraneoplastic cutaneous syndromes/ nonspecific skin lesions were seen in 27 (12.0%) patients (Graph 2).

**Mucocutaneous Reactions to Chemotherapy**

Fourteen (8.6%) out of 163 patients given chemotherapy showed adverse effects of chemotherapy. Thus, 14 (6.2%) out of total 225 cancer patients developed mucocutaneous

reactions due to chemotherapy. Alopecia (4.0%), hyperpigmentation (2.7%) of the nails or skin, and oral mucosal erosions (0.88%) were the commonest adverse effects observed.

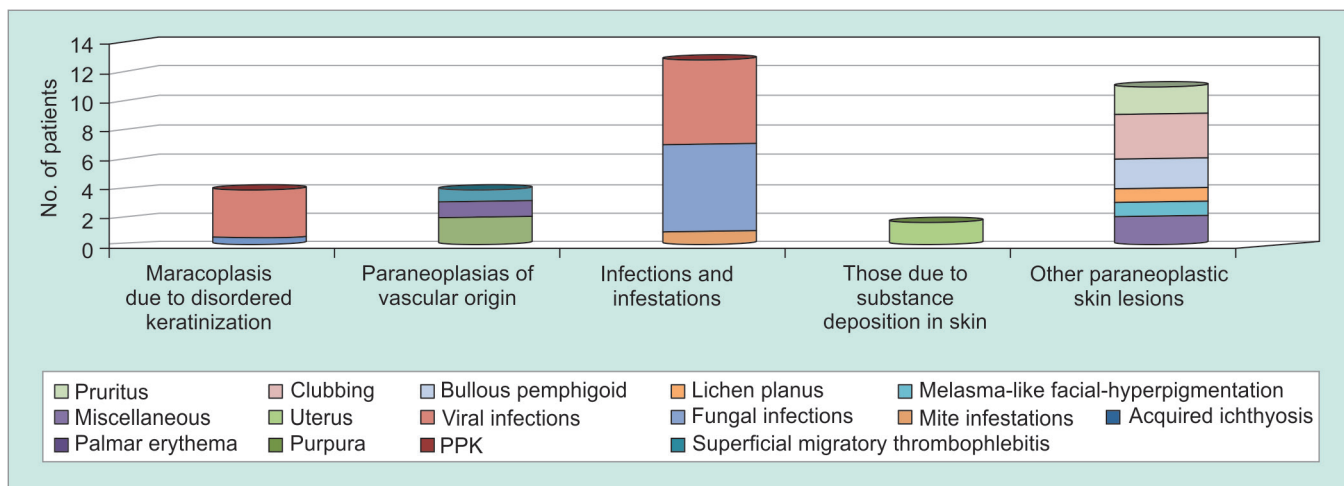
**Skin Changes due to Radiotherapy**

Seven patients (7.1%) out of a total of 98 given radiotherapy showed features of radiodermatitis in the present work. Thus, 7 (3.1%) out of total 225 cancer patients developed radiodermatitis; 3 (1.32%) patients showed acute (inflammatory) radiation reaction, while 4 (1.76%) had evidence of chronic radiation dermatitis in the form of poikilodermatous skin change.

**Skin Lesions seen prior to the Diagnosis of Internal Malignancy**

Skin lesions were present prior to the diagnosis of internal malignancy in 11 (4.9%) patients; 5 (2.2%) patients had specific involvement of the skin which preceded the diagnosis of their internal malignancy. Out of these 5 patients, 4 (80.0%) developed contiguous metastases (Hodgkin’s disease, sarcoma, giant cell tumor of the ribs, and carcinoma breast—1 case each) while 1 (20.0%) patient (carcinoma bladder) had evidence of distal cutaneous metastases.

Six patients (2.7%) had nonspecific lesions before the diagnosis of internal malignancy. They included two patients with icterus (later diagnosed to have carcinoma of liver and carcinoma of gallbladder respectively) and one patient each with seborrheic keratoses (non-Hodgkin’s lymphoma), lichen planus hypertrophicus (carcinoma larynx), multiple lipomas (carcinoma colon) and melasma-like hyperpigmentation of the face (who went on to develop carcinoma of the breast subsequently).



Graph 2: Groups of paraneoplastic skin lesions/syndromes

## DISCUSSION

An internal malignancy developing in an individual is no trivial matter. Many cancers are potentially curable if detected at an early stage. To this end, a physician's thorough knowledge of the skin lesions associated with an internal malignancy can be rewarding for the patient and immensely gratifying for the healer.

Besides being helpful in making an early diagnosis, a knowledge of cutaneous manifestations in various internal malignancies can be extremely helpful in gauging the extent of the disease, assessing the progress and response to therapy of a neoplasm besides enabling one to prognosticate. We can usefully divide the diverse skin manifestations of internal malignancy into five broad groups: Direct tumor spread, genetically determined syndromes, paraneoplastic syndromes, cutaneous markers of exposure to carcinogens, and cutaneous manifestations secondary to the therapy directed at the malignancy.

This study was an attempt to delineate the incidence, frequency, and severity of the various skin manifestations in the cancer patients.

## SPECIFIC SKIN LESIONS

### Cutaneous Metastases

The skin is a relatively uncommon site for metastatic deposits compared with organs, such as liver, lungs, and bones. The overall incidence of cutaneous metastases in patients with internal malignancy varies considerably in different studies, the range being 0.7 to 9.0%.<sup>1</sup>

In the present study, out of a total of 225 patients with internal malignancy studied, 11 (4.9%) patients developed cutaneous metastases, correlating well with various studies published.<sup>6,7</sup> For the purpose of this study, direct invasion of the skin by tumor cells is being considered a form of contiguous metastatic disease.

### Distant Metastases

The two patients who exhibited distant metastases had adenoid cystic carcinoma of the maxilla and carcinoma of the bladder respectively.

Study of the literature shows that bladder carcinoma is a rare cause of cutaneous metastases. Only 2% of male patients and 1% of female patients with cutaneous metastases are found to have carcinoma bladder as the primary malignancy.<sup>8</sup> However, Spencer and Helm<sup>6</sup> found skin metastases in 13 (5.6%) out of 232 cases with bladder and urethral cancer.

### Contiguous (Local) Metastases

Out of the nine patients with contiguous (local) cutaneous metastases, 3 (33.3%) had squamous cell carcinoma

(SCC) of oral cavity (all males), 3 (33.3%) were cases of carcinoma of breast (all females) while of the remaining 3 male patients, one had giant cell tumor (ribs), another had Hodgkin's lymphoma, and the third patient was a case of sarcoma chest wall.<sup>9</sup>

### Cutaneous Metastases as the First Sign of Cancer

In a review involving 7,316 cancer patients, Lookingbill et al<sup>10</sup> found that direct skin involvement was the first sign of an internal malignant neoplasm in 0.8% of patients with internal malignancy. Of this group, approximately equal numbers had direct invasion of the skin, local metastases, and distant skin metastases, which is in contrast to our study where distant metastases were seen in only 18.2% of cases with metastatic disease.

The present study shows that 5 (2.2%) patients presented with cutaneous/subcutaneous nodules as the first sign of malignancy. This correlates with the large study carried out by Lookingbill et al.<sup>10</sup>

Out of the 5 patients, 4 (1.76%) patients had developed contiguous cutaneous metastases that antedated the diagnosis of malignancy in them. These findings agree with published works in the literature.<sup>10</sup>

### Localization of Cutaneous Metastases

In the present study, the chest was the commonest site for specific skin lesions; 39% of all metastases/specific lesions seen in this study were localized to the anterior chest wall (Table 2). This is in accordance with the published studies of Brownstein and Helwig<sup>8</sup> and those of Tharakaram.<sup>11</sup> The head and neck accounted for approximately 37% and abdomen for 12% of the cutaneous metastases in the present work.

### Site of Origin (Primary Malignancy) of the Skin Metastases

In a study involving 724 patients with cutaneous metastases, Brownstein and Helwig<sup>8</sup> had concluded that the most frequent primary neoplasms leading to skin metastases

**Table 2:** Localization sites of cutaneous metastases: comparison with two studies done earlier

Site of the specific skin lesion/s	Brownstein and Helwig <sup>8</sup> (%)	Bansal and Naik <sup>9</sup> (%)	Present study (%)
Head and neck	23	30	37
Chest	31	27	39
Upper extremities	6	—	5
Abdomen	20	36	12
Back	8	3	2
Lower extremities	4	4	3
Perineum/external genitalia	8	—	2
Total	100	100	100



in men were carcinoma of the lung (24%), whereas in women, they were carcinoma of the breast (69%).

In this work, SCC of the oral cavity was the commonest malignancy in men that gave rise to specific skin lesions (direct extension and/or cutaneous metastases), while carcinoma of breast was the commonest in women being the primary malignancy in 3 (75%) of 4 women. These findings correlate well with various studies for the figures in women.

One of the studies authored by Lookingbill et al<sup>7</sup> has shown that carcinoma of the breast is both a common cancer in women and a frequent one to involve the skin, cutaneous lesions in 23.9% of patients with breast cancer.

In the present study, out of a total of 21 cases of breast cancer studied, 3 had specific involvement of the skin. This correlates well with the study conducted by Lookingbill et al<sup>7</sup> quoted earlier.

#### *Size and Consistency of Cutaneous Metastases*

Study of the literature on the subject reveals that most of the cutaneous metastases arise as dermal or subcutaneous nodules with an intact, overlying epidermis. The most common clinical finding is clusters of discrete, firm or hard, painless nodules.

The metastases seen in this study were also painless which correlates well with earlier works on the subject.<sup>8</sup>

### **PARANEOPLASTIC CUTANEOUS MANIFESTATIONS**

#### **Acquired Ichthyosis**

In the present work, acquired ichthyosis was seen in three (1.32%) patients, two cases of Hodgkin's lymphoma, and one of acute myeloblastic leukemia (AML). This is a positive correlation also reported in the literature by various workers.<sup>12,13</sup>

Out of a total of 18 cases of lymphoma seen in this study (11 Hodgkin's and 7 non-Hodgkin's lymphoma), acquired ichthyosis developed in 2 (11% of all lymphomas and 18% of those with Hodgkin's disease). Ichthyosis developed 24 and 6 months after the onset of Hodgkin's disease and 30 months after the onset of AML. This pattern of acquired ichthyosis developing after the onset of Hodgkin's disease conforms to the findings reported by other workers.<sup>12,13</sup>

#### **Superficial Migratory Thrombophlebitis (Trousseau's Sign)**

The presence of Trousseau's sign in patients with lymphoma, migratory superficial thrombophlebitis involving veins of upper extremity and trunk, and the associated tumor being highly malignant with a poor prognosis as

was seen in one patient with Hodgkin's disease are all findings which are in accordance with the studies available in the literature.<sup>14</sup>

### **Infections and Infestations**

#### *Herpes Zoster*

Only a small percentage of patients with localized herpes zoster have an associated malignant disease, and investigation for malignant disease in otherwise healthy patients is not indicated. Patients with leukemia and lymphoma do have an increased risk of herpes zoster, the incidence being about 10%.<sup>15</sup> Disseminated herpes zoster is more commonly associated with malignant disease, again especially with leukemias/lymphomas.

In the present study, herpes zoster was seen in 3 (1.32%) patients. The associated malignancies were Hodgkin's lymphoma, acute lymphoblastic leukemia and astrocytoma—1 (0.44%) case each. In all three cases, herpes zoster was typical dermatomal (localized) zoster. Thus, the overall incidence of herpes zoster in cases of lymphomas and leukemias was found to be 2 (5.3%) out of 33 cases. Though the figures for herpes zoster obtained in this study are marginally on the lower side, they do inform to the earlier works on the subject.<sup>15,16</sup>

#### **Icterus**

Though in this study, icterus was the presenting symptom in two cases, it was seen that the malignancy, especially in the case of hepatocellular carcinoma, was quite advanced by the time the patients presented. This is in accordance with the studies in literature that suggest that icterus usually occurs late in the course of a malignancy.<sup>14</sup>

#### **Clubbing**

More typically associated with chronic lung disease, clubbing can also be a paraneoplastic phenomenon. The malignancy most commonly associated with clubbing is bronchogenic carcinoma (5–10% of all cases),<sup>17</sup> though it has also been observed in mesothelioma, diffuse intestinal lymphoma, and hepatocellular carcinoma.<sup>17,18</sup>

In the present study, clubbing was observed in 3 (1.32%) patients; 2 had bronchogenic carcinoma, while the third was a case of carcinoma gallbladder. Thus, 2 (14.3%) of 14 cases of lung cancer had clubbing. This correlates positively with the earlier works on this subject available in literature.<sup>17,18</sup>

#### **Pruritus**

Pruritus is most commonly associated with leukemia and lymphoma, especially Hodgkin's disease, and is usually seen in late disease.<sup>19</sup>

Two patients in the present study had pruritus—a case of carcinoma of gallbladder, and a known case of Hodgkin's lymphoma, who developed generalized pruritus, most severe on the extremities 6 months after diagnosis and later also developed ichthyosis.

### **Bullous Pemphigoid**

The malignancies reported in association with bullous pemphigoid include those from the breast, lung, thyroid, larynx, skin, soft tissue, stomach, colon, lymphoreticular stem, prostate, cervix, bladder, kidney, and uterus.<sup>20,21</sup>

In this study, two patients, a case of SCC of the penis and a case of carcinoma of the pyriform fossa, developed lesions of bullous pemphigoid.

### **Pityriasis Lichenoides et Varioliformis Acuta**

Pityriasis lichenoides et varioliformis acuta (PLEVA) was seen in one patient in this study, who was a known case of chronic lymphocytic leukemia (CLL) for the past 2 years.

The cause of PLEVA is not known for sure. One hypothesis says that PLEVA is a lymphoproliferative disorder rather than an inflammatory process.<sup>22</sup>

The internal malignancy in the patient with PLEVA seen in the present study was CLL, a lymphoproliferative disorder. The association between the two, therefore, is likely if we consider PLEVA to be a lymphoproliferative as opposed to an inflammatory process.

### **Drug Eruptions**

A maculopapular dense erythematous rash was seen on the trunk and proximal parts of extremities in 1 (0.44%) patient, in a case of recurrence of astrocytoma (operated), 2 weeks after he was put on tab phenytoin. Review of the literature on the subject shows that exanthematic maculopapular rashes are seen in 8.5 to 19% of the patients receiving phenytoin, usually within 3 weeks of starting treatment.<sup>23</sup> This correlates positively with the history and findings in this patient, and possibly had nothing to do with the malignancy per se.

## **MUCOCUTANEOUS REACTIONS TO CHEMOTHERAPY**

### **Alopecia**

Alopecia is the most common adverse cutaneous manifestation of chemotherapeutic treatment.<sup>24</sup>

In the present study, alopecia was seen in 9 (5.5%) of total 163 patients given chemotherapy.

In this study, vincristine, etoposide, bleomycin, ifosfamide, mesna, cyclophosphamide, epirubicin, cytarabine, idarubicin, and paclitaxel were found to cause alopecia. These findings correlate well with studies in the literature on the subject.

### **Hyperpigmentation**

Hyperpigmentation of the skin—mostly involving the acral parts (skin over pressure points/bony prominences and/or over palmar creases) and/or the nails—was seen in 6 (3.7%) of 163 patients given chemotherapy.

The chemotherapeutic agents seen to cause hyperpigmentation of the skin and nails in the present study were bleomycin, etoposide, cisplatin, hydroxyurea, cytarabine, mitoxantrone, paclitaxel, and cyclophosphamide. These findings agree with the published work of Bronner and Hood<sup>25</sup> on this subject.

### **Stomatitis**

Oral and labial mucosal erosions secondary to chemotherapy were seen in 2 (1.2%) patients out of 163 managed with chemotherapeutic drugs in this study.

Thus, mucosal erosions were seen in this study as the side effects of the following chemotherapeutic agents: ifosfamide, cisplatin, bleomycin, idarubicin, cytarabine, and vincristine.

### **Extravasation**

In this study, extravasation injury was seen in 1 (0.61%) patient, in a case of astrocytoma, as the result of extravasation of vincristine and/or etoposide. Both these agents are well known to cause such injury.<sup>26,27</sup>

## **SKIN CHANGES DUE TO RADIOTHERAPY**

In this study, radiotherapy was exhibited by 98 patients in all and out of these, 7 (7.1%) developed radiation dermatitis. Thus, radiation dermatitis was seen in 7 (3.1%) out of 225 cancer patients. Study of literature shows that the incidence of radiodermatitis in cancer patients is very variable and depends on many factors including the type of radiation used, dose fractionation, the total time over which it is given, individual (genetic variations, age, sex, part of the body, treated, degree of differentiation of the malignancy being treated, skin hydration, presence or absence of preexisting inflammation or other skin disease, and concurrent chemotherapy) among others.<sup>28,29</sup>

### **Acute Radiation Reaction**

Acute radiation reaction was seen in 3 (3.1%) out of 98 patients given radiotherapy.

Study of the literature reveals that increases in the total dose of radiation, erythema may be replaced by a severe inflammatory reaction.<sup>28,29</sup>

### **Chronic Radiodermatitis**

Chronic radiodermatitis was seen in 4 (4.1%) out of 98 patients given radiation, all females.

Study of literature on chronic radiodermatitis reveals that the first signs of radiation-induced atrophy are usually noted weeks to months after the exposure to radiation has ended, although further atrophic changes may evolve over 1 or 2 more years.<sup>29</sup> Thus, the findings of the present work correlate well with those of the published works on the subject.<sup>28,29</sup>

### SKIN LESIONS SEEN PRIOR TO DIAGNOSIS OF INTERNAL MALIGNANCY

These were seen in 11 (4.9%) patients; 5 (2.2%) patients had specific involvement of the skin which preceded the diagnosis of their internal malignancy. Out of these 5 patients, 4 (80.0%) developed contiguous metastases, while 1 (20.0%) patient (carcinoma bladder) had evidence of distal cutaneous metastases. These findings agree with those of Lookingbill et al<sup>10</sup> who have reported that specific skin lesions/cutaneous metastases may be the presenting sign in 0.8% of the patients with cancer.

Six patients (2.7%) had nonspecific lesions before the diagnosis of internal malignancy.

### SUMMARY AND CONCLUSIONS

- A total of 225 patients with internal malignancy were studied over a period of about 1 year and 8 months to determine the incidence and types of cutaneous lesions that these patients may have.
- The patients studied comprised 130 males (58%) and 95 females (42%).
- The maximum number of patients (26.2%) were in the age group of 61 years and above, while the least (2.7%) were in the group 10 years and younger.
- Mucocutaneous manifestations were seen in 52 (23%) patients in the present study with a total of 73 skin lesions of various types.
- Specific skin lesions were seen in 11 (4.9%) patients, paraneoplastic skin syndromes/nonspecific skin lesions were seen in 27 (12%), genetic syndromes denoting increased susceptibility to cancer in 1 (0.44%) and skin lesions due to cancer therapy in 21 (9.3%) patients.
- Specific skin lesions comprised 2 (0.88%) cases with distant and 9 (4.0%) with contiguous metastases. The malignancies causing distant metastases were carcinoma of bladder and adenoid cystic carcinoma of the maxilla (1 case each). Contiguous metastases were from carcinoma of oral cavity (3 cases—all 3 males), carcinoma of breast (3 cases—all 3 females) and from giant cell rib tumor, soft tissue sarcoma and Hodgkin's lymphoma (1 case each—all 3 males). The chest was the commonest site of localization of cutaneous metastases (39%) followed by the head and neck (37%). The skin metastases were painless in ten cases and mildly painful in one.

- Paraneoplastic syndromes/nonspecific lesions included acquired ichthyosis in 3 (1.32%) cases, Trousseau's sign in 1 (0.44%), clubbing in 3 (1.32%), and bullous pemphigoid in 2 (0.88%) cases, among others. Infections and infestations, however, constituted the largest group with 12 (5.3%) patients showing evidence of some or the other mucocutaneous infection or infestation. Among these, herpes zoster was seen in 3 (1.32%) patients.
- Gardner's syndrome was seen in 1 (0.44%) patient. He had multiple lipomas, adenomatous polyposis of the colon, and adenocarcinoma involving the descending colon.
- No patient belonging to the group "exposure to carcinogens (that are implicated both in the causation of skin lesions and in that of a malignancy)" was seen in the present study.
- Fourteen (8.6%) out of 163 patients given chemotherapy showed adverse effects of chemotherapy. Thus, 14 (6.2%) out of total 225 cancer patients developed mucocutaneous reactions due to chemotherapy. Alopecia (4.0%), hyperpigmentation (2.7%) of the nails or skin, and oral mucosal erosions (0.88%) were the commonest adverse effects observed.
- Seven patients (7.1%) out of a total of 98 given radiotherapy showed features of radiodermatitis in the present work. Thus, 7 (3.1%) out of a total of 225 cancer patients developed radiodermatitis; 3 (1.32%) patients showed acute (inflammatory) radiation reaction, while 4 (1.76%) had evidence of chronic radiation dermatitis in the form of poikilodermatous skin change.
- Eleven (4.9%) patients had developed skin lesions before the diagnosis of malignancy. These included, among others, Trousseau's sign in 1 (0.44%) patient who was subsequently detected to have Hodgkin's lymphoma, cutaneous metastatic nodule over glans penis in 1 (0.44%) patient found to have carcinoma bladder or investigation, icterus in 2 (0.88%) patients found to have hepatocellular carcinoma and carcinoma gallbladder respectively, during investigation, and multiple lipomas in 1 (0.44%) patient who subsequently developed colonic carcinoma.

### REFERENCES

1. Ellis DL, Kafka SP, Chow JC, Nanney LB, Inman WH, McCadden ME, King LE Jr. Melanoma, growth factors, acanthosis nigricans, the sign of Leser-Trelat, and multiple acrochordons: a possible role for alpha-transforming growth factor in cutaneous paraneoplastic syndromes. *N Engl J Med* 1987 Dec;317(25):1582-1587.
2. Swift M, Morrell D, Massey RB, Chase CL. Incidence of cancer in 161 families affected by ataxia-telangiectasia. *N Engl J Med* 1991 Dec;325(26):1831-1836.
3. Fischer, D.; Knobf, M.; Durivage, H. The cancer chemotherapy handbook. St. Louis (MO): Mosby; 1997. pp. 514-526.

4. Susser WS, Whitaker-Worth DL, Grant-Kels JM. Mucocutaneous reactions to chemotherapy. *J Am Acad Dermatol* 1999 Mar;40(3):367-398.
5. Goldschmidt H, Sherwin WK. Reactions to ionizing radiation. *J Am Acad Dermatol* 1980 Dec;3(6):551-579.
6. Spencer PS, Helm TN. Skin metastases in cancer patients. *Cutis* 1987 Feb;39(2):119-121.
7. Lookingbill DP, Spangler N, Helm KF. Cutaneous metastases in patients with metastatic carcinoma: a retrospective study of 4020 patients. *J Am Acad Dermatol* 1993 Aug;29(2 Pt 1):228-236.
8. Brownstein MH, Helwig EB. Patterns of cutaneous metastasis. *Arch Dermatol* 1972 Jun;105(6):862-865.
9. Bansal R, Naik R. A study of 70 cases of cutaneous metastases from internal carcinoma. *J Indian Med Assoc* 1998; 96: 10-12.
10. Lookingbill DP, Spangler N, Sexton FM. Skin involvement as the presenting sign of internal carcinoma: a retrospective study of 7316 cancer patients. *J Am Acad Dermatol* 1990 Jan;22(1):19-26.
11. Tharakaram S. Metastases to the skin. *Int J Dermatol* 1988 May;27(4):240-242.
12. Kato N, Yasukawa K, Kimura K, Yoshida K. Anaplastic large-cell lymphoma associated with acquired ichthyosis. *J Am Acad Dermatol* 2000 May;42(5 Pt 2):914-920.
13. Rand RE, Baden HP. The ichthyosis: a review. *J Am Acad Dermatol* 1983 Mar;8(3):285-305.
14. McLean, DL.; Haynes, HA. Cutaneous manifestations of internal malignant disease. In: Freedberg IM, Eisen AZ, Wolff K, Austen KF, Goldsmith LA, Katz SI, Fitzpatrick TB, editors. *Fitzpatrick's dermatology in general medicine*. 5th ed. New York: McGraw-Hill; 1999. pp. 2106-2120.
15. O'Bryan-Tear CG, Burke M, Coulston IH, Marsden RA. Hodgkin's disease presenting in the skin. *Clin Exp Dermatol* 1987 Jan;12(1):69-71.
16. Smith JB, Fenske NA. Herpes zoster and internal malignancy. *South Med J* 1995 Nov;88(11):1089-1092.
17. Minna, JD. Neoplasms of the lung. In: Fauci AS, Braunwald E, Isselbacher KJ, Wilson JD, Martin JB, Kasper D, Hauser SL, Longo DL, editors. *Harrison's principles of internal medicine*. 14th ed. New York: McGraw-Hill; 1998. pp. 552-561.
18. Kiszka-Kanowitz M, Nielsen NA. Hypertrophic pulmonary osteoarthropathy. A paraneoplastic syndrome associated with lung cancer. *Ugeskr Laeger* 2000 Jan;162(4):503-504.
19. Freedman, AS.; Nadler, LM. Malignancies of lymphoid cells. In: Fauci AS, Braunwald E, Isselbacher KJ, Wilson JD, Martin JB, Kasper D, Hauser SL, Longo DL, editors. *Harrison's principles of internal medicine*. 14th ed. New York: McGraw-Hill; 1998. pp. 695-712.
20. Lindelof B, Islam N, Eklund G, Arfors L. Pemphigoid and cancer. *Arch Dermatol* 1990 Jan;126(1):66-68.
21. Dahl MV, Ristow S. Bullous pemphigoid and ovarian cystadenocarcinoma: immunologic studies. *Arch Dermatol* 1978 Jun;114(6):903-905.
22. Daoud, MS.; Pittelkow, MR. Pityriasis lichenoides. In: Freedberg IM, Eisen AZ, Wolff K, Austen KF, Goldsmith LA, Katz SI, Fitzpatrick TB, editors. *Fitzpatrick's dermatology in general medicine*. 5th ed. New York: McGraw-Hill; 1999. pp. 553-560.
23. Litt, JZ. Drug eruption reference manual. New York: Parthenon Publishing; 1998. p. 564.
24. Tosi A, Misciali C, Piraccini B, Peluso AM, Bardazzi F. Drug-induced hair loss and hair growth. Incidence, management and avoidance. *Drug Saf* 1994 Apr;10(4):310-317.
25. Bronner AK, Hood AF. Cutaneous complication of chemotherapeutic agents. *J Am Acad Dermatol* 1983 Nov;9(5):645-663.
26. Hood AF. Cutaneous side effects of cancer chemotherapy. *Med Clin North Am* 1986 Jan;70(1):187-209.
27. Boyle DM, Engelking C. Vesicant extravasation: myths and realities. *Oncol Nurs Forum* 1995 Jan-Feb;22(1):57-67.
28. Malkinson, FD. Radiobiology of the skin. In: Freedberg IM, Eisen AZ, Wolff K, Austen KF, Goldsmith LA, Katz SI, Fitzpatrick TB, editors. *Fitzpatrick's dermatology in general medicine*. 5th edn. New York: McGraw-Hill; 1999. pp. 1514-1523.
29. Goldschmidt H, Breneman JC, Bareneman DL. Ionizing radiation therapy in dermatology. *J Am Acad Dermatol* 1994 Feb;30(2 Pt 1):157-182.