

Heel Defect Reconstruction using Local Vascularized Flaps: Results and Clinical Outcomes in 16 Patients

¹Kuldeep Singh, ²Zile S Kundu, ³Bikramjit Singh, ⁴Pramod Dakshinamurthy, ⁵Sudhanshu Punia, ⁶Raj S Potalia

ABSTRACT

Introduction: The defects in the heel result mainly from trauma followed by burns, infections, and tumor resections. If allowed to heal by secondary intention, it will cause pain, difficulty in shoe wear, and be prone to injuries with trivial trauma. Thus, it becomes a difficult situation for the patient. There has always been a challenge to reconstruct heel for decades for the reconstructive surgeon. It is because of lack of tissue of the same thickness, consistency, and texture to match the heel pad, which is required for the proper propelling action of it. We have reconstructed 16 heels with the help of local flaps, which showed satisfactory results.

Keywords: Flap, Heel defect, Medial plantar artery, Sural artery, V–Y advancement.

How to cite this article: Singh K, Kundu ZS, Singh B, Dakshinamurthy P, Punia S, Potalia RS. Heel Defect Reconstruction using Local Vascularized Flaps: Results and Clinical Outcomes in 16 Patients. *J Foot Ankle Surg (Asia-Pacific)* 2018;4(3):16-20.

Source of support: Nil

Conflict of interest: None

INTRODUCTION

Defects of the heel occur mainly as a result of trauma that severely affects its function.¹ Burns, infections, and tumors are among the other causes of soft tissue damage to the heel. Trauma to the heel most of the times causes soft tissue damage, but may be complicated when it is associated with fracture of bones or the exposure of tendoAchilles. In the cases of isolated soft tissue injuries, which are of the avulsion type, immediate reconstruction can be performed with medial plantar artery (MPA) flap after proper wound debridement.^{2,3} Due to the site bearing the body weight and the need to tolerate frequent friction by footwear, cover has to be done with a flap that has good

vascularity, sensations, and resemblance as far as possible to the texture of the heel pad, which the MPA flap does.⁴

If heel defect is associated with fractures of the underlying bones, then there is a high probability of injury to the posterior tibial artery as well, and that excludes the reconstruction process with the MPA flap. Then, the distally based sural artery (DBSA) flap¹ becomes the option for the coverage. Thus, the coverage of heel with a particular type of flap depends on the nature, type, and extent of the wound. We have done heel reconstruction with the DBSA flap in seven cases, MPA flap in six, and V–Y advancement flap in three cases. In this article, we have discussed the different scenarios and options for flaps as well as strategies for heel reconstruction along with the clinical outcomes in these patients.

MATERIALS AND METHODS

A total of 16 patients with soft tissue loss at weight-bearing heel were treated in the Department of Burns and Plastic Surgery and the Department of Orthopaedics at our institute from January 2013 to September 2015. There were 14 males and 2 female patients, with age range between 8 and 55 years. In this series of patients, trauma was the only cause of heel pad injury.

Out of these 16 patients, 7 were treated with DBSA flap, 6 were with MPA flap, and the rest 3 with V–Y advancement flap. The MPA flap was performed in patients whose defects were between 5 and 8 cm in length and breadth, instep area of the sole of the foot was intact, and posterior tibial artery with its continuation into the MPA was patent. The DBSA flap was done in patients where the defect was 9 to 15 cm in dimension, with no injury on the lateral aspect of the lower third of the leg, which could interrupt the vascularity of the flap.

All wounds were prepared by wound excision and debridement, antibiotics administration according to culture, and performing the sensitivity test and dressing. When the wound was adequately prepared, these were resurfaced with flaps. Techniques to raise the flaps are mentioned as below.

Raising the DBSA Flap

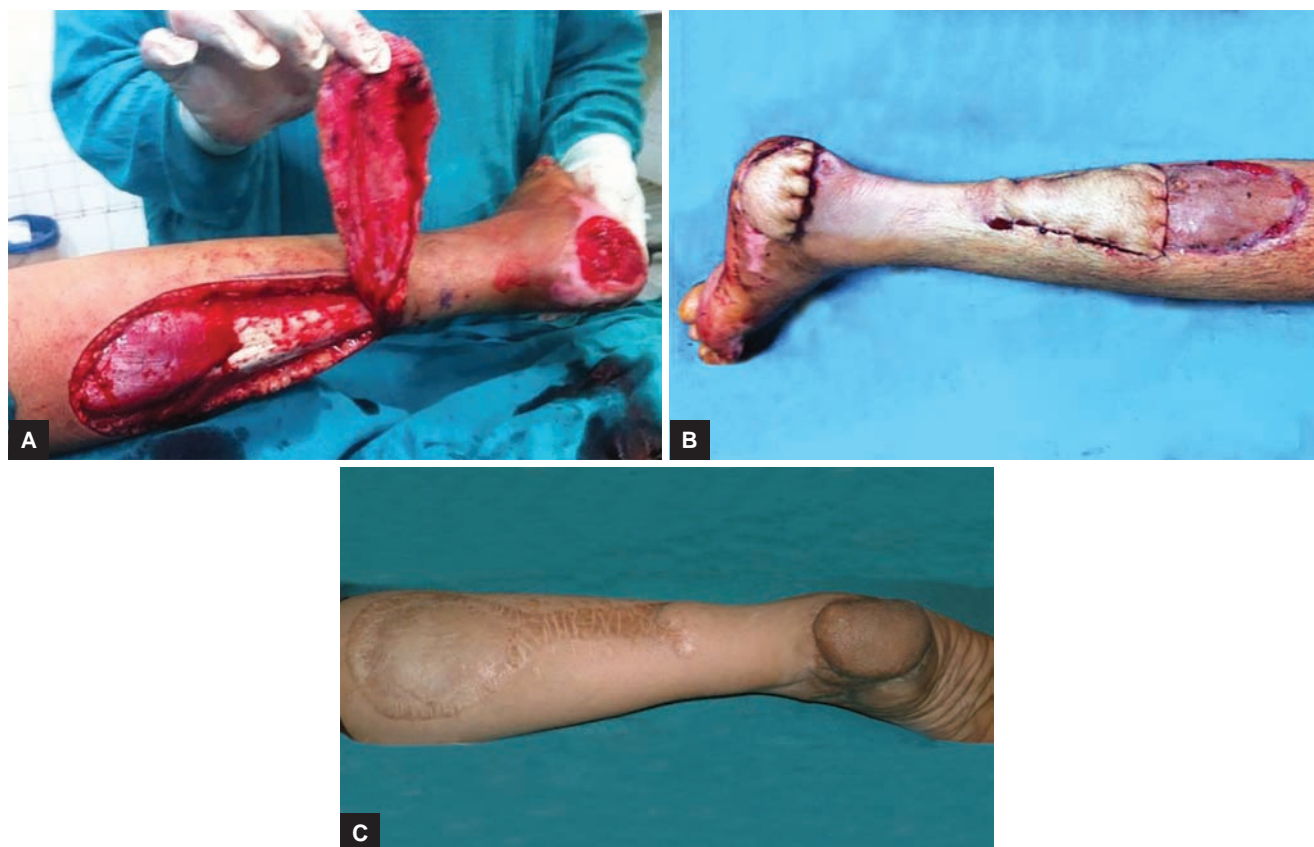The DBSA flap was described by Masquelet et al.¹ It is the most common local flap being used nowadays for the reconstruction of the defects of the lower third leg, ankle, and heel. It is a fasciocutaneous flap, which is harvested from the

^{1,6}Associate Professor, ²Professor, ³⁻⁵Resident

^{1,3-6}Department of Burns and Plastic Surgery, Pt. Bhagwat Dayal Sharma Post Graduate Institute of Medical Sciences, Rohtak Haryana, India

²Department of Orthopaedics, Pt. Bhagwat Dayal Sharma Post Graduate Institute of Medical Sciences, Rohtak, Haryana, India

Corresponding Author: Zile S Kundu, Professor, Department of Orthopaedics, Pt. Bhagwat Dayal Sharma Post Graduate Institute of Medical Sciences, Rohtak, Haryana, India, Phone: +911262274200, e-mail: zskundu2003@rediffmail.com



Figs 1A to C: (A) Raised DBSA flap; (B) DBSA flap divided at 3 weeks; and (C) well-settled DBSA flap at 2-years follow-up

posterior aspect of the middle third of the leg (Fig. 1). Since the upper limit of the flap is taken at the junction of upper and middle third of the leg, delay is required, if further extension is needed. This flap is based on the reverse flow in the median superficial sural artery that communicates with the perforators of the peroneal artery distally.

Pivot point was marked at least 6 cm above the lateral malleolus, and then the flap was marked with the reverse planning on the middle third of the leg. Then, the dissection was started from the proximal end of the flap. Incision was deepened and fascia was cut and included with the flap on its superior, medial, and lateral sides. Sural nerve was identified and cut after giving proper traction, so that the proximal cut end of the nerve retrieved well into the muscle. Lesser saphenous vein was identified, ligated, and tacked with the skin. Median superficial sural artery was identified in the gastrocnemius raphe, ligated, and included in the flap. The flap was raised up to the level of 6 to 8 cm proximal to the lateral malleolus and then transposed to cover the heel defect. Donor area was reduced with the advancement of skin from all around, and the rest was skin grafted. Patient was advised constant foot care and special shoe despite adequate padding by the flap over the heel.^{1,5}

Raising the MPA Flap

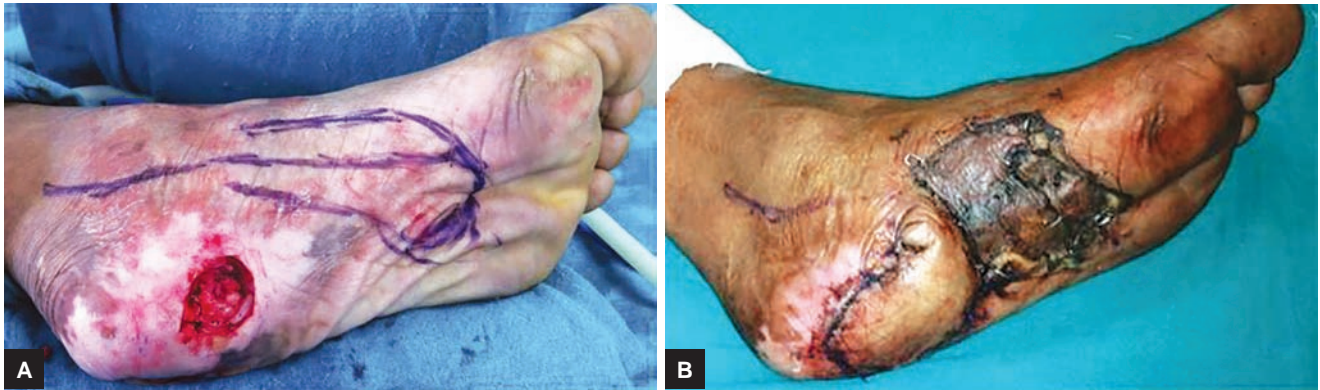
This flap was originally described by Shanahan and Gingrass² and later modified by Harrison and Morgan³

for reconstruction of heels due to trauma. The flap is harvested from the instep of the foot. The size of the flap is limited by the size of the defect and, hence, cannot be used for the larger defects. The flap was raised from distal to proximal, incision was made deep to the fascia, and planter fascia was included with the flap (Fig. 2). The MPA with its venae comitantes and medial plantar nerve was identified in between the abductor hallucis and flexor digitorum brevis and dissected proximally beneath the flap up to the defect in the heel. The nerve supplying the flap was teased off the medial plantar nerve. Then, the flap was transposed and inset was done. Split-thickness skin graft was applied on the donor site.^{2,3}

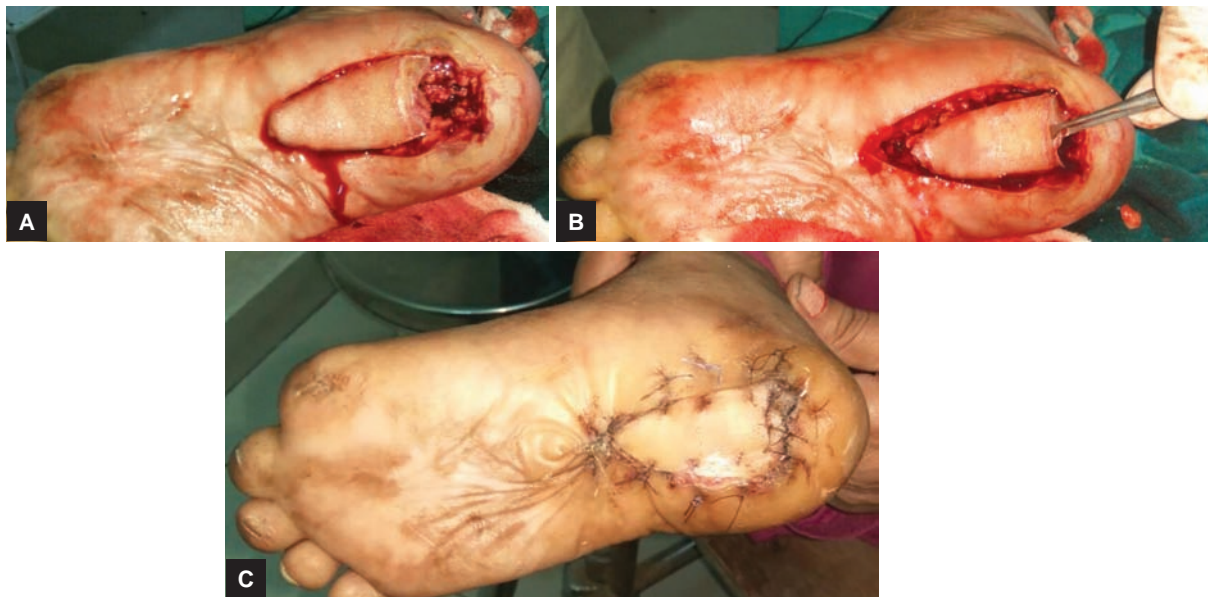V-Y Advancement Flap

A V-Y advancement flap was created by making a V-shaped incision and advancing the broad base of the V into the defect (Fig. 3). The resulting defect was closed primarily in a Y-shape.

All advancement flaps should be under minimal tension. Further undermining, although relieving the excessive tension may compromise vascularity. If a larger flap is required, then it should be done in two stages. It is raised in the first procedure and after waiting for 5 to 7 days, advancement is done taking the advantage of the delay phenomenon, which increases the chances of flap survival.



Figs 2A and B: (A) Defect and marked MPA flap; (B) medial artery flap inset



Figs 3A to C: (A) The heel defect after debridement and V-Y advancement flap marking; (B) V-Y advancement flap after inset; (C) well-settled V-Y advancement flap

Postoperative Care and Follow-up

Dressing was done separately for the donor site and tie over dressing at the skin-grafted recipient site. Plaster of Paris splint was given for immobilization with a window to observe the flap. Dressing at the skin-grafted site was done on the fifth day. Sutures were removed after 2 weeks, patients were taken off splint after 3 weeks, and supported ambulation was started afterward.

RESULTS

Results were measured in terms of flap survival and functional outcome, i.e., uneventful walking, and were graded as excellent, good, and poor (Table 1). Two DBSA flaps had minor complications in the form of distal marginal necrosis, which was managed by excision followed by secondary suturing. One patient showed venous congestion, which improved with loosening of sutures and multiple superficial incisions. One flap had superficial skin necrosis, which healed with dressings only.

In this flap group, excellent results were observed in four patients and the rest showed good results that had tip necrosis and superficial skin necrosis.

One medial plantar island flap was lost because of compression/kinking of pedicle in the postoperative period. This complication can be avoided by constant monitoring of the flap in the postoperative period. This was subsequently managed by the DBSA flap. Poor result was seen in this patient, the rest had excellent results. Three patients with V-Y advancement flaps had shown excellent results with one requiring delay before final closure.

DISCUSSION

Reconstruction of the heel has been a difficult problem to deal with because of lack of local tissue with same texture and skin thickness, so it does create a difficult situation for the reconstructive surgeon.⁶ Hence, many options and ways have come up to overcome this problem of heel

Table 1: Details and outcome of the patients

Age/sex	Etiology	Size (cm)	Flap used	Complications	Management of complications	Outcome
26, M	Trauma	10 × 6	DBSA	Uneventful	–	Excellent
32, M	Trauma	6 × 5	MPA	Uneventful	–	Excellent
35, F	Trauma	12 × 10	DBSA	Distal tip necrosis	Debridement and secondary suturing	Good
20, M	Trauma	4 × 5	V–Y	Uneventful	–	Excellent
28, M	Trauma	10 × 5	DBSA	Venous Congestion	Loosening of sutures and multiple superficial incisions	Excellent
55, M	Trauma	6 × 4	MPA	Uneventful	–	Excellent
14, M	Trauma	8 × 4	MPA	Uneventful	–	Excellent
22, F	Posttraumatic contracture	7 × 5	MPA	Uneventful	–	Excellent
52, M	Trauma	3 × 3	V–Y	Uneventful	–	Excellent
8, M	Trauma	10 × 12	DBSA	Uneventful	–	Excellent
14, M	Trauma	10 × 13	DBSA	Uneventful	–	Excellent
44, M	Trauma	5 × 7	MPA	Flap necrosed	Debridement and cover with DBSA	Poor
28, M	Unstable traumatic scar	9 × 9	DBSA	Distal tip necrosis	Debridement and secondary suturing	Good
18, M	Trauma	5 × 4	MPA	Uneventful	–	Excellent
24, M	Trauma	10 × 15	DBSA	Superficial skin necrosis	Conservative	Good
34, M	Traumatic unstable scar	3 × 4	V–Y	Uneventful	–	Excellent

coverage.⁷ Though many ways have been mentioned to deal with heel defects, none have shown satisfactory results in the long term. If skin graft is used as a reconstructive option, it does break up repeatedly and easily with the stress of weightbearing and shows poor results.⁴

Many pedicled flaps from the foot and the leg do fall short of length to cover the whole heel. “Free flap” is another option to cover the heel, but it is very demanding and requires special instruments and expertise of the surgeon to execute it. Nonetheless, transferred tissue is bulky and a failure of around 5 to 7% in the best of hands and centers is observed.⁷ But, it is of great value when no other local flap is available for reconstruction of heel. Local random flaps have high incidence of failure. Cross-leg flap may also be used in the options where all local flaps are not available and facilities for doing free flaps are not present. It does carry significant morbidity as it is a staged procedure and as the patient is immobilized with both legs attached with each other by the flap, for more than 3 weeks.⁸

Most of the patients in our series are young and active in their life and lose their weight-bearing heel due to trauma. In cases of traumatic loss, the option of flap depends on the size of the defect and associated fractures and availability of vascular pedicle.⁸ In this series, small defects, where posterior tibial artery was present with patent MPA, were covered with MPA flap and in larger defects, DBSA flaps were used. There was not much difference in the procedural aspects as both are relatively easy and simple to raise with good arc of rotation.

We have chosen three types of flaps for reconstruction of heel: MPA flap, DBSA flap, and V–Y advancement of the local heel tissue according to the size of defect. The MPA flap is selected for those cases in whom the defect is between 5 and 8 cm with intact instep area of the sole

and MPA is patent. The DBSA flap is done for defects with injury to the instep area of sole and the patency of MPA is absent or doubtful or larger defects with no injury to lower lateral part of the leg are present.¹

In our series, six heels were reconstructed with MPA Flap, with five excellent and one poor result. Seven heels were reconstructed with DBSA flaps where excellent results were obtained in four patients and good in the rest three. One medial plantar island flap got necrosed because of compression or kinking of pedicle in postoperative period and was further managed by DBSA flap later. There was partial loss in two DBSA flaps possibly because of known venous congestion in distally based flaps, which were managed by advancement and secondary suturing. Flap survival was comparable with other series in all these three types of flaps.⁸

Early weight bearing was feasible in MPA flap cases, because these were sensate flaps. The MPA flap is an excellent flap for small defects, which provides similar tissue of the heel, and preserves all the function in the postreconstructive period. The DBSA flap is a good method for large defects and provides relatively better heel pad. In the three cases we did V–Y advancement flaps with fairly good results. Therefore, all the three flaps fulfilled the requirements of heel reconstruction as per their indications and feasibility, which could be tailored according to the need. But, despite good to excellent results, these reconstructed heels require regular follow-up, adequate care, and proper footwear.

CONCLUSION

In our study, we have applied three types of flaps, viz., DBSA, MPA, and V–Y advancement flaps, in heel

defect reconstruction. All types of these flaps were easy to raise and execute and showed good to excellent recovery. For long-term results, these patients need to be followed up regularly and proper footwear has to be worn lifelong.

REFERENCES

1. Masquelet AC, Romana MC, Wolf G. Skin island flaps supplied by vascular axis of the sensitive superficial nerves: Anatomic study and clinical experience in the leg. *Plast Reconstr Surg* 1992 Jun;89(6):1115-1121.
2. Shanahan RE, Gingrass RP. Medial plantar sensory flap for coverage of heel defects. *Plast Reconstr Surg* 1979 Sep;64(3):295-298.
3. Harrison DH, Morgan BDG. The instep island flap to resurface plantar defects. *Br J Plast Surg* 1981;34:315-318.
4. Lister GD. Use of an innervated skin graft to provide sensation to the reconstructed heel. *Plast Reconstr Surg* 1978 Aug;62(2):157-160.
5. Meland NB. Microsurgical reconstruction: the weight bearing surface of the foot. *Ann Plast Surg* 1990;11(1):54-58.
6. Hartrampf CR Jr, Schefflan M, Bostwick J 3rd. The flexor digitorum brevis muscle island flaps: a new dimension in heel reconstruction. *Plast Reconstr Surg* 1980 Aug;66(2):264-267.
7. Goldberg JA, Adkin P, Tsai TM. Microvascular reconstruction of the foot: weight-bearing pattern gait analysis and long-term follow up. *Plast Reconstr Surg* 1993 Oct;92(5):904-911.
8. Kalam MA, Faruquee SR, Rahman SA, Uddin HN. Reconstruction of heel: options and strategies. *Bangladesh J Plast Surg* 2010;1(1):14-18.