

# Role of Calcaneoplasty and Correlation of Haglund's Bump and Spur in Insertional Achilles Tendinopathy and Degenerative Achilles Tendon Rupture

<sup>1</sup>Sundararajan S Ramasamy, <sup>2</sup>Ramakanth Rajagopalakrishnan, <sup>3</sup>Balaji Sambandam, <sup>4</sup>Shanmuganathan Rajasekaran

## ABSTRACT

**Introduction:** Patients with degenerative Achilles tendon rupture and those with a chronic nonresponding Achilles tendinopathy form a major surgical population in foot and ankle surgery. Simple debridement and repair of the tendon will not be sufficient in these patients because the Haglund bump and retrocalcaneal spur, which is seen in both groups, is an important contributing factor. Calcaneoplasty and spur excision are required in addition to get good results. In this study, the clinical significance of Haglund bump and the role of calcaneoplasty and spur excision in treating these related pathologies are discussed.

**Materials and methods:** This is a retrospective study of two groups of patients. The first group comprised 20 patients with chronic Achilles tendinopathy, who underwent tendo-achilles (TA) detachment debridement and reattachment after calcaneoplasty. The second group comprised 19 patients with degenerative TA rupture, who underwent tendon repair with calcaneoplasty. Postoperative outcomes at 6 months follow-up were compared between these groups, and a multinomial logistic regression was done to analyze the preoperative variables to predict the strong factor that causes tear.

**Results:** Mean pre- and postoperative American Orthopedic Foot & Ankle Society (AOFAS) score of the tendinopathy group was 54.25 [standard deviation (SD) = 13.1] and 95.15 (SD = 6.13), whereas it was 45.68 (SD = 13.33) and 93.11 (SD = 4.90) in the tendon rupture group. In both the groups, there was a marked increase in postoperative outcome, but there was no significant difference in between the two groups ( $p$ -value = 0.259). Multinomial logistic regression proved Haglund bump, measured using Vega angle, to be the only significant predictor of tendon rupture.

**Conclusion:** Haglund bump and spur are the significant lesions of the posterior heel pathologies. Surgical treatment of these pathologies should always include calcaneoplasty and spur

excision when there is an abnormally prominent Haglund bump as predicted by Vega angle.

**Keywords:** Calcaneoplasty, Chronic achilles tendinopathy, Degenerative tendo-achilles rupture, Haglund's bump.

**How to cite this article:** Ramasamy SS, Rajagopalakrishnan R, Sambandam B, Rajasekaran S. Role of Calcaneoplasty and Correlation of Haglund's Bump and Spur in Insertional Achilles Tendinopathy and Degenerative Achilles Tendon Rupture. *J Foot Ankle Surg (Asia-Pacific)* 2018;4(3):5-12.

**Source of support:** Nil

**Conflict of interest:** None

## INTRODUCTION

Posterior heel pain is the most common symptom related to Achilles tendon pathology, which can be due to Achilles tendinopathy, retrocalcaneal bursitis, Haglund's deformity (the prominent posterosuperior calcaneal process), and degenerative rupture. Disorders of Achilles tendon insertion account for 20 to 25% of heel pathology.<sup>1</sup> The various predisposing factors are age, inflammatory disorders, steroid use, diabetes mellitus (DM), hypertension (HT), overweight, hypercholesterolemia, use of quinolone antibiotic,<sup>2</sup> protease inhibitor intake (iopinavir/ritonavir),<sup>3</sup> genetic susceptibility,<sup>4,5</sup> increased repetitive loading,<sup>6</sup> foot wear related,<sup>7</sup> and malalignment in lower limbs.<sup>8</sup> Posterosuperior calcaneal prominence (Haglund's bump) has been associated with pain, tendon attrition, and swelling. They are thought to be an adaptive change to tendon microtears or inflammation. Their role in insertional tendinopathy is not fully understood.<sup>9</sup> Similarly, two main theories for Achilles tendon rupture are degenerative and mechanical. According to degenerative theory, chronic degeneration of Achilles tendon leads to rupture without excessive stress. Degeneration can be related to age, chronic overloading with microtrauma, drug treatment, and systemic disease, such as inflammatory diseases, autoimmune diseases, genetically inherited collagen disorders, neurogenic diseases, and high serum lipid levels, which are prone to have increased incidence of spontaneous Achilles tendon ruptures. Also, local and systemic corticosteroids are considered as risk factors for TA rupture. Injecting steroids was found to induce necrosis in 45 minutes at the site of injection. These tendons also

<sup>1</sup>Senior Consultant, <sup>2</sup>Senior Registrar, <sup>3</sup>Fellow, <sup>4</sup>Director and Chief

<sup>1,3</sup>Department of Foot and Ankle, Ganga Hospital, Coimbatore Tamil Nadu, India

<sup>2</sup>Department of Arthroscopy and Foot and Ankle, Ganga Hospital, Coimbatore, Tamil Nadu, India

<sup>4</sup>Department of Orthopedics, Ganga Hospital, Coimbatore Tamil Nadu, India

**Corresponding Author:** Sundararajan S Ramasamy, Senior Consultant, Department of Foot and Ankle, Ganga Hospital Coimbatore, Tamil Nadu, India, Phone: +919843256545, e-mail: sundarbone70@hotmail.com

showed a delayed healing response. In 1928, Haglund<sup>10</sup> was the first to describe the role of posterolateral part of the calcaneus in a painful heel. Various authors have measured the prominence of Haglund's bump and spur; however, its correlation in Achilles tendinopathy and degenerative rupture needs to be studied. Further, role of calcaneoplasty and functional outcome in these conditions is our secondary objective of our study.

## MATERIALS AND METHODS

This is a retrospective study and data were retrieved from the institutional database, hospital records, and from picture archiving communication system. All the patients with retrocalcaneal pain were reviewed from our database and for the study, patients were divided into two groups. In group I (Table 1), there were 20 patients, who underwent surgery for chronic Achilles tendinopathy and in group II (Table 2), 19 patients underwent surgery for degenerative Achilles tendon rupture (January 2014 to September 2016). We excluded patients with traumatic Achilles tendon rupture with no evidence of degeneration and open injuries of Achilles tendon. Informed consent was taken from all patients to participate in the study. They were followed up with a minimum of 6 months after the procedure. Patients' details like age, sex, prior history of steroid injection, medical comorbidities like DM and HT were documented. All patients were evaluated with preoperative and follow-up AOFAS ankle hind foot scale. They were examined clinically for assessing swelling (Fig. 1A), retrocalcaneal tenderness

suggestive of bursitis, range of ankle movements, Thompson's test and tip-toe standing. Preoperative radiographs in patients were looked for Haglund's bump deformity using parallel pitch lines (PPL) (Fig. 2B), Fowler Philip angle (FPA), and angle of Vega to quantify the radiological measurement of the bump. Presence of retrocalcaneal TA spur and insertional calcification (Figs 1 and 2) were also measured. After getting a written informed consent, all the patients were given spinal anesthesia and positioned semiprone on an operating table with posterior surface of leg facing up. Group I patients underwent TA detachment, calcaneoplasty (Haglund's bump excision), retrocalcaneal bursectomy and spur excision, and reattachment of TA using suture anchor. The wound then was closed using nonabsorbable sutures and a below-knee cast was applied with ankle in neutral position. Postoperatively, the patient was initially put in a below-knee cast with a window opened for inspection of the wound. Patient was mobilized nonweight bearing for a period of 6 weeks in the cast. Later, they were progressed to partial and full weight bearing over the next 4 weeks, and then weight bearing in a modified foot wear with a high heel counter. In group II degenerative TA rupture patients, with similar approach, the torn tendon was identified and the degenerated tendon was debrided and the calcific Achilles spur was excised from retrocalcaneal region; the calcaneoplasty was completed. The tendon close to the insertion site of the calcaneum was reattached to the calcaneum using suture anchors. Wound closed and below-knee cast applied in neutral

**Table 1:** Chronic TA tendinopathy: patients' data, functional outcome, and radiological measurements

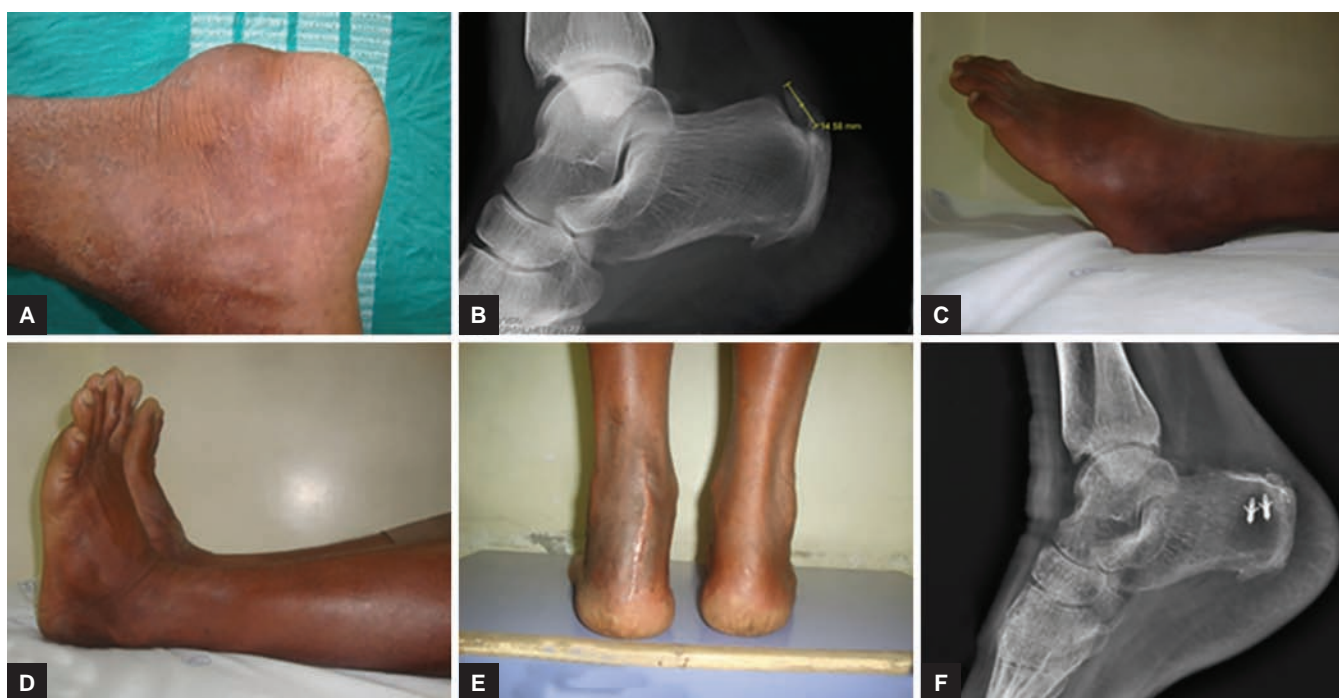Age	Sex	Side	Comorbidities	H/O steroid injection	Surgical technique	AOFAS preoperative	AOFAS postoperative	FPA	Vega angle	PPL (+)	Tendon calcification	Spur size (mm)
36	F	R	Nil	Nil	SA	41	96	59	90	No	Yes	15
58	M	R > L	Nil	1 year back	SA	55	94	74	92	No	Yes	14
48	F	R	HT	Nil	SA	61	94	60	71	No	Yes	11
40	F	R	Nil	Nil	SA	68	96	56	70	Yes	Yes	25
55	M	R	Nil	Nil	SA+ V Y	61	96	66	86	Yes	Yes	13
53	F	R > L	Nil	Nil	SA	30	96	62	82	Yes	Yes	15
56	F	R > L	Nil	Nil	SA	43	98	65	85	No	Yes	11
56	M	L	Nil	Nil	SA + VY	66	100	51	74	Yes	Yes	9
42	F	L > R	Nil	Nil	SA	55	100	53	73	Yes	Yes	9
53	M	R	Nil	nil	SA	38	98	67	87	Yes	Yes	12
52	F	R > L	HT	nil	SA	62	71	55	76	No	Yes	15
50	F	L > R	DM	nil	SA	50	94	64	92	No	Yes	13
45	M	L	Nil	nil	SA	29	94	65	90	Yes	Yes	20
59	F	R	Nil	nil	SA	75	100	69	80	No	Yes	15
43	M	L > R	Nil	nil	SA	66	94	58	72	Yes	Yes	8
60	F	L	Nil	nil	SA	71	96	57	90	Yes	Yes	5
58	M	R > L	Nil	nil	SA	51	94	43	64	Yes	Yes	5
53	M	R > L	DM + HT	Thrice/year	SA	50	98	61	90	Yes	Yes	12
53	F	R > L	Nil	Nil	SA	63	94	62	82	No	Yes	18

R: Right; L: Left; SA: Suture anchor; Spur: Retrocalcaneal spur

**Table 2:** Degenerative TA rupture: patients' data, functional outcome, and radiological measurements

Age	Sex	Comorbidities	H/O steroid	Surgical technique	AOFAS preoperative score	AOFAS postoperative	FPA	Vega angle	PPL	Spur size (mm)
34	M	OOCHRONoSIS	Nil	VY + SA	28	90	54	89	Positive	15
53	M	Nil	2 months	VY + SA	30	100	55	88	Positive	11
53	M	IHD	Nil	SA	55	84	68	87	Positive	32
59	M	Nil	Nil	VY + SA	52	87	74	99	Positive	16
51	F	Nil	Nil	SA	54	90	75	90	Positive	20
49	M	Nil	1 month	VY + SA	65	90	77	98	Positive	16
47	F	Nil	Nil	VY + SA + FHL	56	97	57	95	Positive	18
65	M	DM + HT	Nil	VY + SA	48	100	54	94	Positive	14
46	M	DM	Nil	SA	34	90	63	87	Negative	10
70	M	DM	Nil	SA	50	97	70	91	Positive	8
64	M	DM + HT	Nil	Ethibond	28	100	59	90	Positive	5
47	M	Nil	Nil	SA	65	90	70	91	Negative	5
58	M	DM + HT	Nil	VY + SA	56	94	60	90	Positive	10
42	F	Nil	Nil	SA	36	94	63	83	Negative	15
67	F	DM + HT	Nil	Vicryl	28	97	77	94	Positive	14
57	M	HT	Nil	VY + SA	34	94	64	92	Positive	30
40	M	Nil	Nil	SA	48	96	65	86	Negative	7
67	F	DM	1 month	SA + FHL	65	85	77	90	Positive	10
57	M	DM	Nil	SA	36	94	79	92	Negative	12

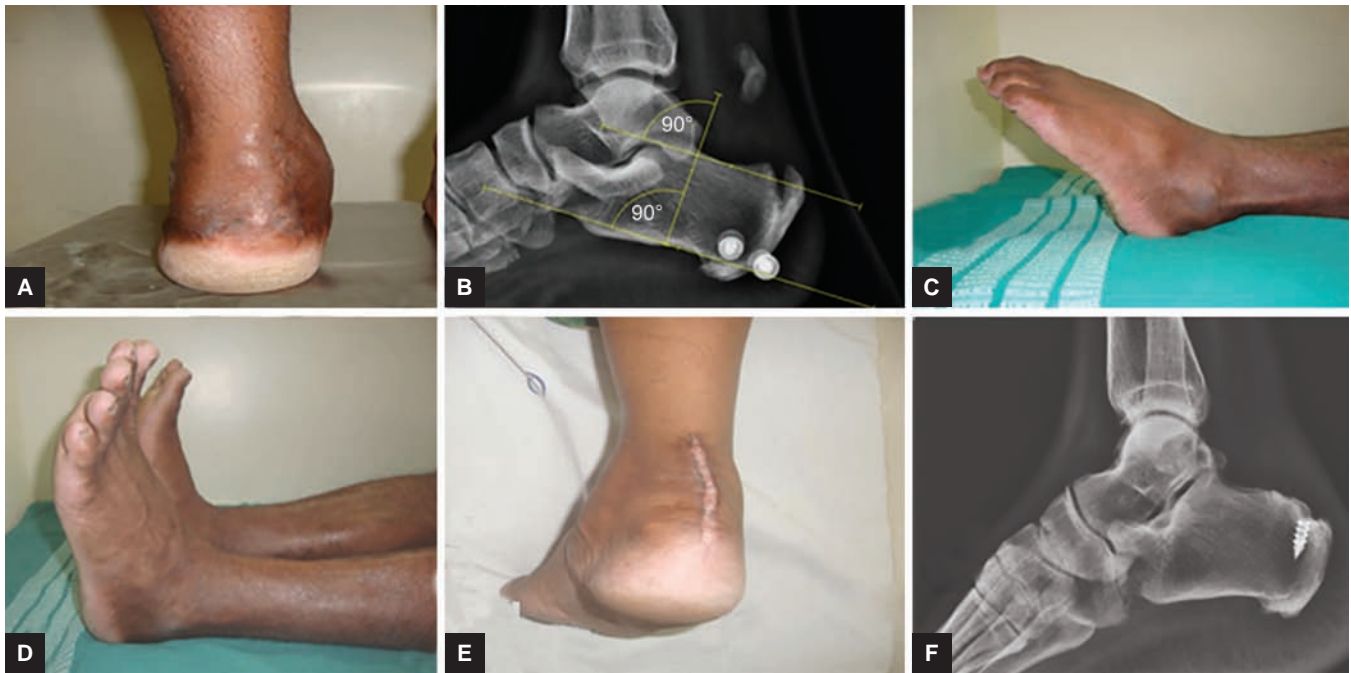
R: Right; L: Left; SA: Suture anchor; Spur: Retrocalcaneal spur



**Figs 1A to F:** Chronic TA tendinopathy: (A) preoperative clinical photo of dorsal prominence; (B) preoperative X-ray showing Haglund's bump and retrocalcaneal spur; (C–E) movements and clinical photos at final follow-up; and (F) follow-up X-ray showing suture anchor

position. However, in few cases, where after debridement, the tendon approximation was unsatisfactory/unyielding and, if the gap is less than 2 cm, a V-Y plasty of the Achilles tendon at the musculotendinous junction was done and then TA was mobilized and reattached with suture anchors. If the retraction gap was more than 2 cm, tendon was augmented with flexor hallucis longus (FHL)

augmentation transfer. Postoperatively, the patient was initially put on a below-knee plaster cast with a window for wound inspection and was mobilized nonweight bearing for a period of 6 weeks and then partial weight bearing for another 6 weeks. At the end of 12 weeks, patient was allowed to full weight bear with a modified foot wear (pneumatic walking boot). Patients were



**Figs 2A to F:** Degenerative TA rupture: (A) preoperative photo showing swelling and gap on weight bearing; (B) preoperative X-ray showing Haglund's bump, retrocalcaneal spur, and degenerative calcification in TA; and (C–F) clinical photo and X-ray at the time of final follow-up

evaluated every 6 weeks for first 3 months and then after 6 months. After 6 months of follow-up, they were given a questionnaire based on AOFAS hind foot score to evaluate the pain, function, and alignment of the foot. Total of 100 points were generated based on the answers and clinical examination. Statistical analysis was done using Statistical Package for the Social Sciences version 20 and Student's *t*-test was used to compare the outcome scores between the groups; multinomial logistic regression was used to analyze the variables to predict the strong factor that causes tear.

## RESULTS

**Group I (n = 20) (Table 1):** Most of the patients in group I were 50 to 60 years old, average age was 51.35 years (60–36 years) with a slight female predominance, with 8 male and 12 female patients. A total of 14 patients had right-side pathology and 6 on left side. Only 4 patients had medical comorbidities and 2 patients had history of prior steroid injection in group I. Preoperative analysis showed presence of retrocalcaneal tenderness along with pain and swelling of the calcaneum along the sides of tendon attachment suggestive of Haglund's bump and retrocalcaneal bursitis. On analyzing the postoperative functional outcome with AOFAS ankle hind foot scale, most of them had excellent-to-good outcome with mean score of 95.15 (SD = 6.13) There was a statistically significant increase in the outcome when compared with the mean preoperative score, which was 54.25 (SD = 13.1). All patients in the group returned to activities of daily living by end of 3 months. No postoperative complication

was noted in the average follow-up of 25 months. About 95% of our patients were satisfied with the postoperative status and the functional outcome.

**Group II (n = 19) (Table 2):** The average age was 54 years (70–34 years) with 14 males and 5 female patients and 11 patients had right-side complaints and 8 on left side. A total of 11 patients had medical comorbidities and 3 patients had history of prior steroid injection in group II. Of 19 patients, 17 had a distal Achilles tendon rupture, which was reattached with suture anchors and the results were consistent with the literature with good functional outcome and good patient satisfaction. A total of 8 of the 17 patients had to undergo V-Y plasty of the Achilles tendon in order to attach to calcaneum and 3 of them underwent an augmentation with FHL tendon transfer. Two of the 19 patients had tear more proximally and end-to-end repair could be done using traditional technique. Mean postoperative score in this group was 93.11 (SD = 4.90). This was a significant improvement from the average preoperative score of 45.68 (SD = 13.33).

Though the mean postoperative score in the first group was 2 points higher than the second, this difference was not found to be statistically significant ( $p = 0.259$ ) as analyzed by Student's *t*-test. Tendinopathy and degenerative tendon rupture are the continuum of the same degenerative pathology. Using our data, we did a multinomial logistic regression analysis to find out the factors, which can predict the occurrence of tendon rupture from the tendinopathy stage. We took into account three groups of factors. One group of factors includes various patient-specific factors like age, sex, associated comorbid illness,

and history of (H/O) steroid injection. Second group of factors is the measurement of Haglund's bump—PPA and Vega angle. Third group is the measurement of calcification—length of bony spur. Multinomial logistic regression results showed that of all the factors, the one which significantly predicted the occurrence of tendon rupture is the measurement of Haglund's bump by Vega angle. Average Vega angle in group I (tendinopathy group) was 81.2 (SD = 8.53). Average Vega in group II (tear group) was 90.84 (SD = 3.99). The difference in mean was very significant with a p-value of 0.00. The odds ratio for Vega score is 1.278. It denotes the relative risk ratio for a patient with tendinopathy developing tendon rupture when 1 unit increase in Vega angle occurs when all the other variables are held constant. If a subject were to increase his/her Vega score by 1 unit, the relative risk for developing a tear would be expected to increase by a factor of 1.278 provided the other variables are held constant. More generally, we can say that if two subjects have every other factor as the same, the subject with the higher Vega angle is more likely to develop tear.

## DISCUSSION

Currently, for chronic Achilles tendinopathy, a trial of conservative treatment is given for a period of 3 to 6 months and patients are operated only if they have persistent symptoms.<sup>11</sup> Conservative treatment involves rest, ice packs, nonsteroidal anti-inflammatory drugs, physiotherapy, and in sole modification of footwear. All patients in group I had undergone a conservative primary treatment for a period of 6 months and those who had continuous symptoms were selected for surgery. The patients were operated with a central tendon-splitting approach and, after detaching the tendon, retrocalcaneal bursae, TA spur, Haglund's prominence (calcaneoplasty) was excised and the tendon was debrided and reattached with suture anchor and fiber wire into the calcaneum. Wound was closed with nonabsorbable sutures and a below-knee cast in neutral position applied. Choice of surgical technique is a controversial topic in literature. Now, the preferred method among many authors is to debride with detachment of the tendon and reattaching with suture anchors.<sup>12</sup> In a study by Anderson et al,<sup>13</sup> which compared the central tendon-splitting approach with the lateral approach, they found no difference in relation to pain, outcome score, and complications;<sup>14</sup> however, the central tendon-splitting group could return to function much more quickly.<sup>13,15,16</sup> There is no consensus in the literature regarding the best approach. In a study by Johnson et al,<sup>17</sup> they found that a central tendon-splitting approach yielded good relief of pain with improved function, shoe wear, and ability to work

without painful postoperative scars. All patients in group I underwent central tendon-splitting approach. Calder and Saxby<sup>15</sup> suggested that if more than 50% of the tendon was detached, it should be reattached. Earlier studies were done by Wagner et al<sup>18</sup> and Maffuli et al.<sup>19</sup> Both studies suggested the disinsertion of the Achilles tendon for complete debridement of the calcific deposits, bony prominences, and reattachment with suture anchor as a recommended surgical procedure for calcific Achilles tendinopathy. Using similar technique, the first large study with long follow-up was done by Greenhagen et al.<sup>20</sup> They followed up 30 patients for an average period of 28 ± 16 months. They had excellent outcome with 97% satisfaction rate and a significant improvement in the functional outcome. None of the patients had wound-related complication or infections.

The functional outcome for the patients in our study was inconsistent with the literature with a statistically significant difference in the preoperative and postoperative AOFAS ankle hindfoot score. Also, the patient satisfaction rate of 95% was similar to the current literature. Thus, to get optimum results, debridement and excision of bony prominences (calcaneoplasty) yield good results.

In a most recent study by McAlister and Hyer,<sup>21</sup> where they followed up 100 heels, they found 9% wound-related complications and 4% revision surgery. In our study with 20 patients, none of them had wound-related complications and none underwent revision surgeries.

Group II patients with Achilles tendon rupture were treated surgically and no conservative trial was advised. There are various surgical treatments in the literature describing the techniques of Achilles tendon repair. The distal end of the Achilles tendon rupture is still a challenging case to surgeons because end-to-end suturing is not possible in them. There was always a debate in literature regarding whether to choose operative or nonoperative treatments for Achilles tendon rupture. Recent studies have shown that the trend is toward surgical intervention. In an analysis of 12,570 patients in the health database by Wang et al,<sup>23</sup> 61% underwent surgery. Rate of rerupture was comparable in both groups and the rate of infection was 2.3% in the operated group. Surgical treatments for Achilles tendon rupture in group II patients were consistent with the literature with excellent functional outcome and patient satisfaction.

In 1993, Hanna et al<sup>22</sup> described the technique of reattachment with suture anchor in a 59-year-old male who sustained a rupture of distal Achilles tendon. They had good results with no complication at a 16-month interval period. From then on, studies have come up with this technique by authors like Maniscalco et al,<sup>24</sup> Lui,<sup>25</sup> and Liu et al<sup>26</sup> all showing good outcomes with minimal complications. Importance is not only given to reattachment

of the tendon, but also need for debridement and excision of bony prominence (calcaneoplasty and retrocalcaneal spur excision) is stressed for optimum results. In this study, all group II patients had good surgical outcome and none reported with wound-related complications or rerupture in the follow-up period. Although steroid injection is widely known to cause tendon rupture, none of the studies were done in human patients to truly quote its incidence in rupture of the tendons. Animal studies have enough evidence to suggest that intratendinous steroid injection would result in tendon degeneration and predispose to rupture.<sup>27-30</sup> Upon collecting the retrospective data, 3 of the 19 patients underwent previous local steroid administration prior to the rupture. Incidence of local steroid injection prior to rupture was 15% in our study. All of them had undergone steroid injection within a period of 2 months prior to rupture. There was no difference in the functional outcome and no complications in the wound healing in these patients.

Raikin<sup>31</sup>, in an analysis of 404 patients with Achilles tendon rupture, found that 3% had previous steroid injection and 4% had DM.<sup>25</sup> In our study, we had a higher number of patients with DM who sustained rupture. A total of 7 out of 19 patients (35%) had DM. Although certain studies have given concern about the wound healing and outcome of the patients with DM,<sup>32,33</sup> we had comparable results for patients with comorbidities and those without comorbidities (Table 3), and none had wound-related complications.

On radiological assessment of the Haglund's deformity in the cases operated for Achilles tendinopathy and degenerative Achilles tendon rupture using FPA, PPLs, and angle of Vega, we found that 60% met the criteria to be called positive for having a significant Haglund's bump deformity for angle of Vega, 30% positive for PPLs, and 5% for FPA in the tendinopathy group. In the degenerative Achilles tendon rupture group, 75% met the criteria of significant Haglund's bump using PPL and angle of Vega and 55% were positive for FPA. Existing literature shows very high false negative values for these measurements.<sup>34</sup> Using FPA, 100% false negative was reported by Heneghan et al<sup>35</sup>, more than 30% false negative was reported by the author who described the PPLs, and only Vega et al<sup>36</sup> found a less false negative value of 10% in their limited study with 10 foot.<sup>10,33</sup> Although clinically all of our patients had evidence of Haglund's

bump, radiological measurement gave varied results. Our finding was correlating with the literature considering the high number of false negativities in the technique of measurement and its clinical reliability. In this study, we did a comparative analysis of these radiological measurements and attempted to predict the significance of Haglund's bump between the two groups. Our results denote the relative risk for developing a tear rather at a later date with tendinopathy when patient had high Vega angle. If a subject were to have increased Vega angle by 1 unit, the relative risk for developing a tear rather than tendinopathy would be expected to increase by a factor of 1.278 provided the other variables are held constant. More generally, we can say that if two subjects have every other factor as the same, the subject with the higher Vega angle is more likely to develop tear than tendinopathy.

On radiological measurement of the calcific spur of the TA in two groups (Table 4), we found that all patients in group II (rupture group) and group I (tendinopathy group) had radiological evidence of calcific TA, showing their degeneration. We also measured the length of the TA spur and found that in group I (tendinopathy), the average length was 12.5 mm. Women had average length of 13 mm and men had 11 mm. About 75% of the total patients had a significant TA spur (more than 10 mm). Although the mean postoperative score of patients with less than 10 mm length of the spur was higher when compared with the patients with more than 10 mm spur, the difference was not statistically significant. In the degenerative Achilles tendon rupture group of 19 patients, 75% had a significant spur measuring more than 10 mm and the average length of the spur was 14 mm. Women in the group had an average spur length of 13 mm and males had an average of 11 mm. The mean postoperative AOFAS score of patients with short spur was higher than the patients with a spur of more than 10 mm length. The difference, however, was not statistically significant. Thus, adequate posterior debridement and excision of bony prominences are necessary to obtain good postoperative results as seen in both the groups. Since Haglund's bump measured by Vega angle is the only significant factor predicting a tear from a tendinopathy, calcaneoplasty during surgery should always be performed. The limitation of our study was the retrospective data collection. The number of the

**Table 3:** Correlation of functional outcome in patients with comorbidities and no comorbidities

	No comorbidity	Comorbidity
Mean AOFAS score	95.42	92.13
SD	3.57	7.53
p-value	0.074	

**Table 4:** Assessment of TA spur in group I (tendinopathy) and group II (tear)

	Spur	No. of patients	Mean AOFAS
Group I (tendinopathy)	More than 10 mm	15	94.6
	Less than 10 mm	5	96.8
Group II (tear)	More than 10 mm	15	92
	Less than 10 mm	4	95.4

patients and total follow-up period are also of concern to draw a general conclusion of the results. We recommend the future studies to be prospective with more number of cases and, i.e., to be followed for a longer period. Studies comparing with other techniques of surgery to establish a gold standard procedure are needed, as it is lacking in the present literature. True incidence of significant Haglund's deformity in Achilles tendinopathy should be measured by a newer, reliable technique and, thus, facilitate the study of the necessity of routine excision of postero-superior prominence of calcaneum during surgery.

## CONCLUSION

Surgical treatment of chronic Achilles tendinopathy with detachment of the tendon for adequate debridement, calcaneoplasty, spur excision, and reattachment of the tendon with suture anchors is a safe and effective procedure with good functional outcome and satisfaction among the patients.

Surgical management of degenerative Achilles tendon rupture provides good results with early mobilization and no reruptures. In the tear of distal part of Achilles tendon, reattachment with suture anchor is a safe and effective option for the surgeons. Thus, the role of calcaneoplasty is justified as in both the cases for optimum results.

Patients with less amount of calcific spur had slightly better functional outcome in both the groups although it was not proved statistically.

Haglund's with higher Vega angle and positive PPLs are liable to develop degenerative tendon rupture.

## REFERENCES

1. Kvist M. Achilles tendon injuries in athletes. *Ann Chir Gynaecol* 1991;80(2):188-201.
2. Holmes GB, Lin J. Etiologic factors associated with symptomatic Achilles tendinopathy. *Foot Ankle Int* 2006 Nov;27(11):952-959.
3. Cresswell FV, Tomlins J, Churchill DR, Walker-Bone K, Richardson D. Achilles tendinopathy following Kaletra (lopinavir/ritonavir) use. *Int J STD AIDS* 2014 Oct;25(11):833-835.
4. Nell EM, van der Merwe L, Cook J, Handley CJ, Collins M, September AV. The apoptosis pathway and the genetic predisposition to Achilles tendinopathy. *J Orthop Res* 2012 Nov;30(11):1719-1724.
5. Björklund E, Forsgren S, Alfredson H, Fowler CJ. Increased expression of cannabinoid CB receptors in Achilles tendinosis. *Plos One* 2011 Sep;6(9):e24731.
6. Fahlström M, Lorentzon R, Alfredson H. Painful conditions in the Achilles tendon region in elite badminton players. *Am J Sports Med* 2002 Jan-Feb;30(1):51-54.
7. Paavola M, Kannus P, Järvinen TA, Khan K, Józsa L, Järvinen M. Achilles tendinopathy. *J Bone Joint Surg Am* 2002 Nov;84-A(11):2062-2076.
8. Reule CA, Alt WW, Lohrer H, Hochwald H. Spatial orientation of the subtalar joint axis is different in subjects with and without Achilles tendon disorders. *Br J Sports Med* 2011 Oct;45(13):1029-1034.
9. Benjamin M, Rufai A, Ralphs JR. The mechanism of formation of bony spurs (enthesophytes) in the Achilles tendon. *Arthritis Rheum* 2000 Mar;43(3):576-583.
10. Kang S, Thordarson DB, Charlton TP. Insertional achilles tendinitis and Haglund's deformity. *Foot Ankle Int* 2012 Jun;33(6):487-491.
11. Irwin TA. Current concepts review: insertional Achilles tendinopathy. *Foot Ankle Int* 2010 Oct;31(10):933-939.
12. Watson AD, Anderson RB, Davis WH. Comparison of results of retrocalcaneal decompression for retrocalcaneal bursitis and insertional achilles tendinosis with calcific spur. *Foot Ankle Int* 2000 Aug;21(8):638-642.
13. Anderson JA, Suero E, O'Loughlin PF, Kennedy JG. Surgery for retrocalcaneal bursitis: a tendon-splitting versus a lateral approach. *Clin Orthop Relat Res* 2008 Jul;466(7):1678-1682.
14. van Dijk CN, van Sterkenburg MN, Wiegerinck JJ, Karlsson J, Maffulli N. Terminology for Achilles tendon related disorders. *Knee Surg Sports Traumatol Arthrosc* 2011 May;19(5):835-841.
15. Calder JD, Saxby TS. Surgical treatment of insertional Achilles tendinosis. *Foot Ankle Int* 2003 Feb;24(2):119-121.
16. Nunley JA, Ruskin G, Horst F. Long-term clinical outcomes following the central incision technique for insertional Achilles tendinopathy. *Foot Ankle Int* 2011 Sep;32(9):850-855.
17. Johnson KW, Zalavras C, Thordarson DB. Surgical management of insertional calcific achilles tendinosis with a central tendon splitting approach. *Foot Ankle Int* 2006 Apr;27(4):245-250.
18. Wagner E, Gould JS, Kneidel M, Fleisig GS, Fowler R. Technique and results of Achilles tendon detachment and reconstruction for insertional Achilles tendinosis. *Foot Ankle Int* 2006 Sep;27(9):677-684.
19. Maffulli N, Del Buono A, Testa V, Capasso G, Oliva F, Denaro V. Safety and outcome of surgical debridement of insertional Achilles tendinopathy using a transverse (Cincinnati) incision. *J Bone Joint Surg Br* 2011 Nov;93(11):1503-1507.
20. Greenhagen RM, Shinabarger AB, Pearson KT, Burns PR. Intermediate and long-term outcomes of the suture bridge technique for the management of insertional achilles tendinopathy. *Foot Ankle Spec* 2013 Jun;6(3):185-190.
21. McAlister JE, Hyer CF. Safety of achilles detachment and reattachment using a standard midline approach to insertional enthesophytes. *J Foot Ankle Surg* 2015 Mar-Apr;54(2):214-219.
22. Hanna JR, Russell RD, Giacomelli JA. Repair of distal tendo Achillis rupture with the use of the Mitek Anchor System. *J Am Podiatr Med Assoc* 1993 Dec;83(12):663-668.
23. Wang D, Sandlin MI, Cohen JR, Lord EL, Petrigliano FA, SooHoo NF. Operative versus nonoperative treatment of acute Achilles tendon rupture: an analysis of 12,570 patients in a large healthcare database. *Foot Ankle Surg* 2015 Dec;21(4):250-253.
24. Maniscalco P, Bertone C, Bonci E, Donelli L, Pagliantini L. Titanium anchors for the repair of distal achilles tendon ruptures: preliminary report of a new surgical technique. *J Foot Ankle Surg* 1998 Mar-Apr;37(2):96-100.
25. Lui TH. Fixation of tendo Achilles avulsion fracture. *Foot Ankle Surg* 2009 Feb;15(2):58-61.
26. Liu LL, Xie BJ, Wang WL, Dai MH, Yang GJ, Tang CX. Therapeutic effects of suture anchors for the reconstruction of distal tendo Achilles rupture. *Zhongguo Gu Shang* 2010 Mar;23(3):177-179.

27. Notarnicola A, Maccagnano G, Tafuri S, Forcignanò MI, Panella A, Moretti B. CHELT therapy in the treatment of chronic insertional Achilles tendinopathy. *Lasers Med Sci* 2014 May;29(3):1217-1225.
28. Mahler F, Fritschy D. Partial and complete ruptures of the Achilles tendon and local corticosteroid injections. *Br J Sports Med* 1992 Mar;26(1):7-14.
29. Clark SC, Jones MW, Choudhury RR, Smith E. Bilateral patellar tendon rupture secondary to repeated local steroid injections. *J Accid Emerg Med* 1995 Dec;12(4):300-301.
30. Checa A, Chun W, Pappu R. Ultrasound-guided diagnostic and therapeutic approach to retrocalcaneal bursitis. *J Rheumatol* 2011 Feb;38(2):391-392.
31. Raikin SM, Garras DN, MD, Krapchev PV. Achilles tendon injuries in a United States population. *Foot Ankle Int* 2013 Apr;34(4):475-480.
32. Ahmed AS, Li J, Schizas N, Ahmed M, Ostenson CG, Salo P, Hewitt C, Hart DA, Ackermann PW. Expressional changes in growth and inflammatory mediators during Achilles tendon repair in diabetic rats: new insights into a possible basis for compromised healing. *Cell Tissue Res* 2014 Jul;357(1):109-117.
33. Maffulli N, Longo UG, Maffulli GD, Khanna A, Denaro V. Achilles tendon ruptures in diabetic patients. *Arch Orthop Trauma Surg* 2011 Jan;131(1):33-38.
34. Chauveaux D, Liet P, Le Huec JC, Midy D. A new radiologic measurement for the diagnosis of Haglund's deformity. *Surg Radiol Anat* 1991 Feb;13(1):39-44.
35. Heneghan MA, Pavlov H. The Haglund painful heel syndrome. Experimental investigation of cause and therapeutic implications. *Clin Orthop Relat Res* 1984 Jul-Aug;(187):228-234.
36. Vega MR, Cavolo DJ, Green RM, Cohen RS. Haglund's deformity. *J Am Podiatry Assoc* 1984 Mar;74(3):129-135.