

Nontraumatic Atlanto-occipital Dislocation: Rare Experience of Two Cases

¹Alok M Uppar, ²Nupur Pruthi, ³Sunil Malagi, ⁴Sandeep Kandregula, ⁵Mustafa I Chandshah

ABSTRACT

Introduction: Spontaneous or nontraumatic atlanto-occipital dislocation (AOD) is a rare entity and has been sparsely reported till now. These cases can either present in its exclusive form (AOD alone) or in association with atlanto-axial instability (AAI). In this study, the authors report two cases of spontaneous AOD: (a) AOD with AAI with basilar invagination (BI) and (b) AOD presenting as hypoglossal nerve palsy, both of which were surgically managed and followed up.

Materials and methods: CASE 1: A 12-year-old girl presented with neck pain, restricted neck movements, and head tilt. There was no history of trauma. A diagnosis of AOD with associated AAI and BI was made using X-ray, computed tomography (CT), and magnetic resonance imaging (MRI) of craniovertebral junction (CVJ). After realigning the dislocated joints using skull traction, occipitocervical fusion was performed through a posterior approach. CASE 2: A 41-year-old male presented with neck pain and restricted neck movements for 2 years and deviation of the tongue to the right side for 3 months. There was no history of trauma. A diagnosis of posterior AOD was made based on X-ray, CT, and MRI of CVJ. After realigning the dislocated joints using skull traction, occipitocervical fusion was performed through a posterior approach.

Results: Both patients were stable at follow-up. Both patients had resolution of presenting symptoms and had no fresh complaints or deficits. Imaging shows proper alignment with bony fusion in both cases.

Conclusion: The present case series, to the best of authors' knowledge, is the first article to report nontraumatic AOD presenting with isolated hypoglossal nerve palsy and nontraumatic AOD with coexisting AAI and BI, along with their surgical management and outcomes with follow-up. Reduction of dislocation and occipitocervical fusion is paramount in treating these rare cases.

Keywords: Atlanto-axial dislocation, Atlanto-occipital dislocation, Basilar invagination, Hypoglossal nerve palsy, Nontraumatic, Occipitocervical fusion.

How to cite this article: Uppar AM, Pruthi N, Malagi S, Kandregula S, Chandshah MI. Nontraumatic Atlanto-occipital Dislocation: Rare Experience of Two Cases. *J Spinal Surg* 2018;5(2):93-99.

^{1,3,4}Senior Resident, ²Additional Professor, ⁵Junior Resident

¹⁻⁵Department of Neurosurgery, National Institute of Mental Health and Neurosciences, Bengaluru, Karnataka, India

Corresponding Author: Nupur Pruthi, Additional Professor Department of Neurosurgery, National Institute of Mental Health and Neurosciences, Bengaluru, Karnataka, India, e-mail: pruthi_nupur@yahoo.co.in

Source of support: Nil

Conflict of interest: None

INTRODUCTION

Literature and reports on cases of traumatic AOD are abundant. However, nontraumatic AOD is rare, with only a few cases reported. Atlanto-occipital dislocation associated with AAI in the same patient is much rarer. Some noteworthy predisposing conditions to nontraumatic AOD with AAI are infections of head and neck,¹ congenital disorders like Down's syndrome,² inflammatory conditions like rheumatoid arthritis, and neoplastic lesions. The common mechanisms include either ligamentous laxity or bony instability caused as a result of these predisposing factors.

Patients with AOD may be neurologically intact, or present with high cervical myelopathy, or lower cranial palsy with or without brainstem involvement.

Relevant Anatomy: Joints

The atlanto-occipital (AO) joint is formed between the inferiorly convex occipital condyle and the concave superior articular facet of the atlas along with the articular capsule. The atlanto-axial joint includes an anterior atlanto-dental joint and bilateral lateral mass articulations. The atlanto-axial joint allows axial rotation of up to 30° with minimal flexion and extension. However, the AO joint mainly allows flexion and extension up to 25° and minimal axial rotation.^{3,4}

Ligaments

The alar ligaments run from lateral part of foramen magnum of the skull to dens. They serve to check contralateral flexion. The apical ligament extends from the tip of dens to basion stabilizing the AO joint. The cruciate ligament lies posterior to odontoid. While the superior and inferior portions help in the stabilization of odontoid to basion, the transverse band, which is the strongest portion of the ligament, stabilizes the odontoid to the lateral mass of atlas, preventing posterior displacement of dens. The posterior longitudinal ligament runs behind the cruciate ligament and checks both flexion and extension. The posterior AO membrane

extends frominion to C7 spinous process. It limits excessive neck flexion.^{3,4}

Radiography

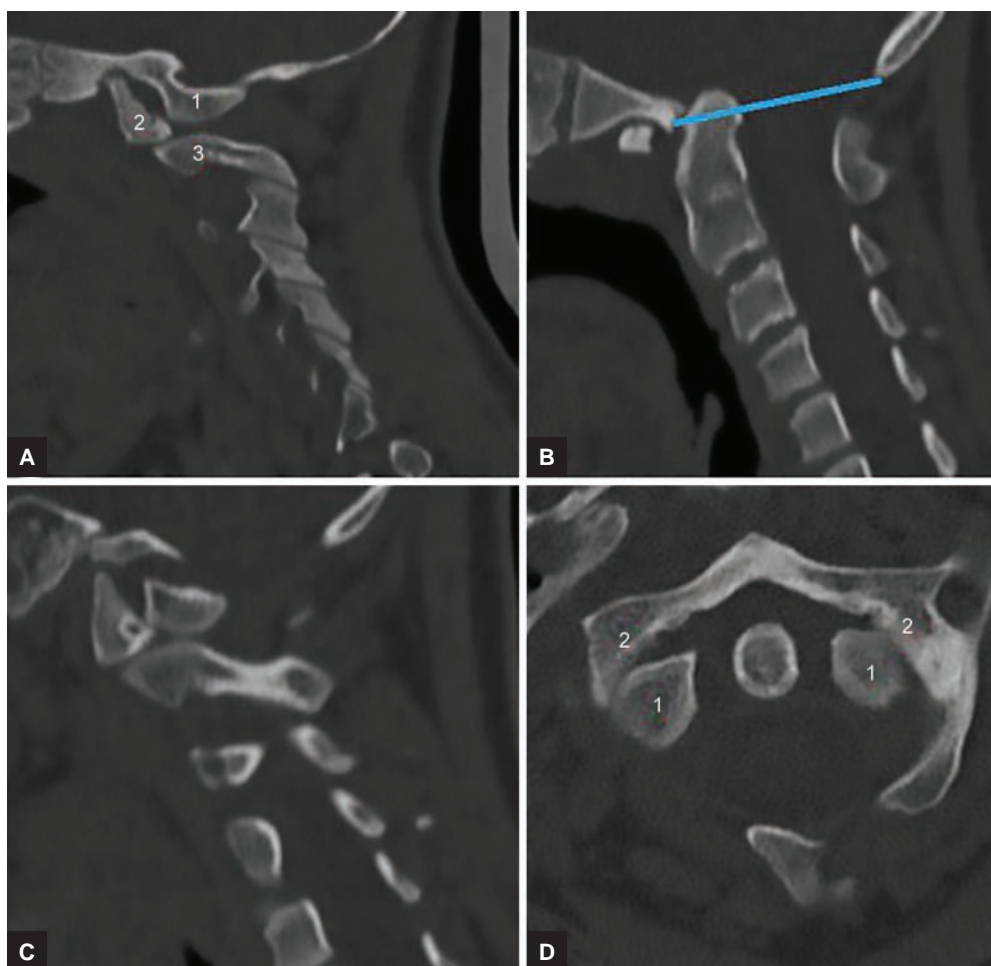
The Traynelis classification⁵ divides AOD into three groups: Type I— anterior dislocation of occiput relative to the atlas; type II—longitudinal dislocation (distraction); type III—posterior dislocation of occiput. Combinations like anterior-distracted AOD may also occur.⁶ Numerous methodologies exist to radiographically diagnose AOD. Important methods and criteria are: Basion-dens interval and basion-axis interval (BAI) (Harris lines), Powers' ratio, X-line method, and atlanto-occipital interval (AOI).⁴⁻⁹

In this series, we report surgical management and outcomes with follow-up of (1) nontraumatic AOD with AAI and BI, and (2) nontraumatic AOD presenting with hypoglossal nerve palsy, both of which, to the best of authors' knowledge, have never been reported in English literature.

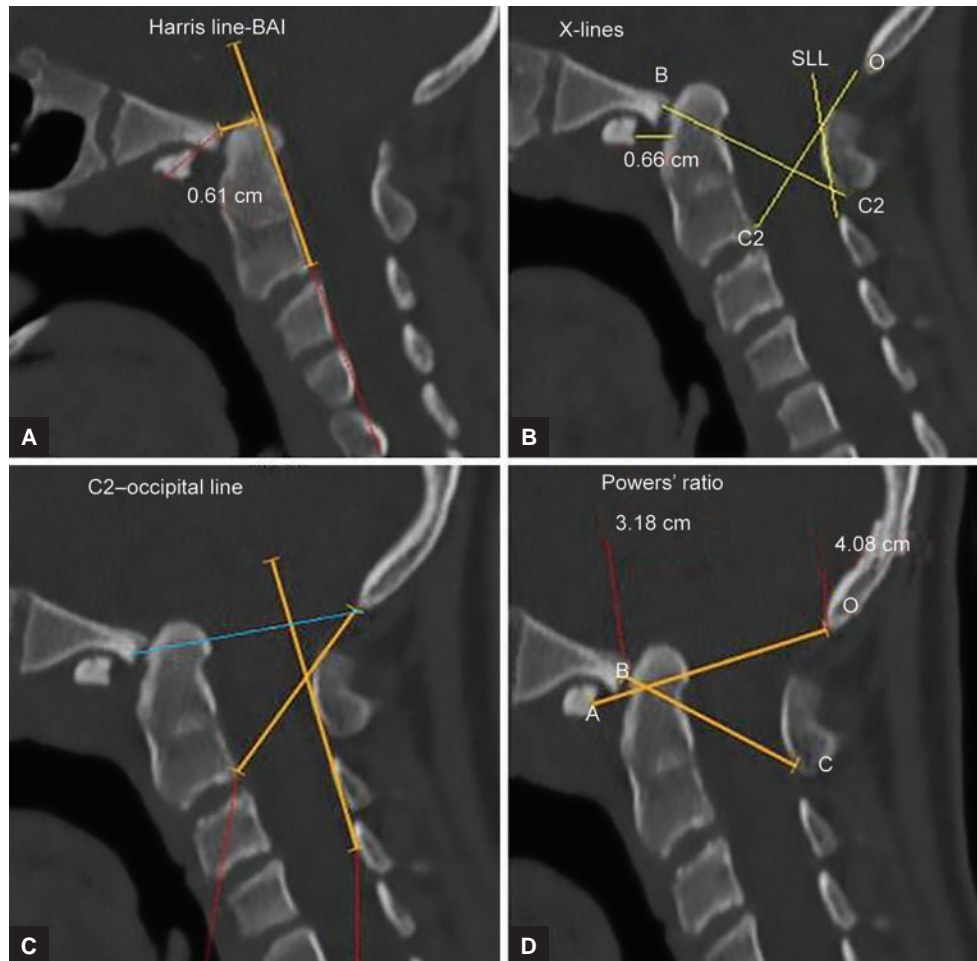
CASE REPORTS

Case 1

A 12-year-old girl presented with neck pain, restricted neck movements, and head tilt. There was no history of trauma. Her clinical examination was unremarkable except for a short neck with a head tilt to the right side and a high arched palate. A diagnosis of type III AOD with associated AAI and BI was made using X-ray, CT, and MRI of CVJ (Fig. 1). Harris line (BAI) was normal. X lines method showed that basion-C2 line was abnormal and was an indicator of AOD. Powers' ratio was normal. There was increased anterior ADI of 0.66 cm (Fig. 2). After re-aligning the dislocated joints using skull traction, occipitocervical fusion was performed through a posterior approach. On the right side, occipital condylar screw and c2 pedicle screw were placed. On the left side, c1 lateral mass screw and c2 pedicle screw were placed. An occipital single-hole plate was used to place a bicortical occipital screw. Contour rods were placed bilaterally



Figs 1A to D: Preoperative CT imaging of case 1. (A) Right side type III AOD with AAD, note the posterior location of the occipital condyle in relation to the c1 lateral mass. Note the flat articulating surface of C1. (B) Increased ADI in the mid-sagittal plane. Also, note the BI. Dens tip above the blue McRae's line. (C) Type III AOD with AAD on the left side. (D) Axial images showing the anterior displacement of c1 lateral mass in relation to occipital condyles. 1 = occipital condyles. 2 = c1 lateral mass. 3 = c2 superior articular facet



Figs 2A to D: Applying radiographic methods: case 1. (A) Harris line measurement was normal. (B) X-lines: Basion-c2 (BC2) line is seen passing through odontoid process which is abnormal. The c2-spinolaminar line was normal and was tangentially touching the c1 posterior arch. Increased anterior atlanto-dental interval of 0.66 cm is also shown. (C) The c2-spinolaminar line is normal. Also, note the blue McRae's line and BI. (D) Powers' ratio. BC/AO is <1

and the joints were distracted, and chips of cancellous bone were placed between all articulating joints after removing articular cartilages to aid bony fusion. A bony construct (rib graft) was wedged snugly between the occipital bone (after exposing the cancellous part by drilling gently) and cancellous bone of c2 spinous process adjoining the lamina to aid posterior bony fusion. The patient was doing well at 21 months follow-up with no neck pain, with no head tilt, and no neurological deficits. Bony fusion, both anterolaterally and posteriorly, between occiput and c1 to c2 with good alignment was seen on follow-up imaging. Reduction of atlanto-axial dislocation (AAD) and BI was clearly seen (Fig. 3).

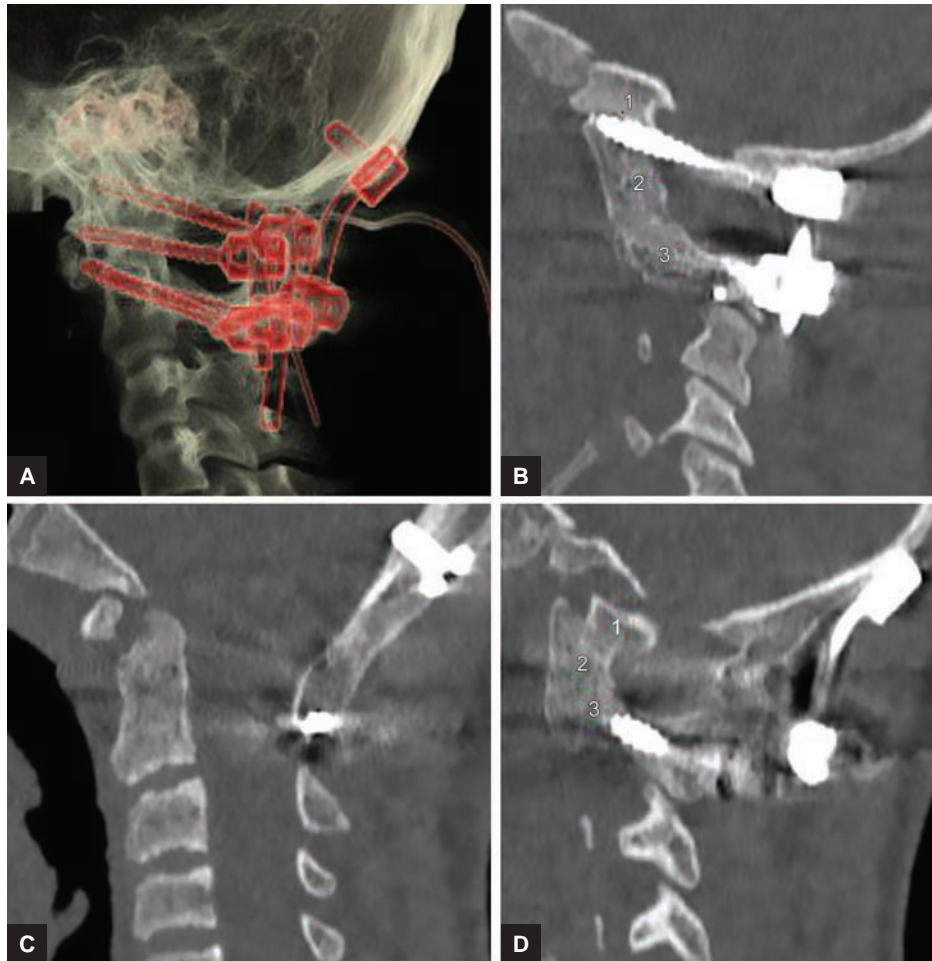
Case 2

A 41-year-old male presented with neck pain and restricted neck movements for 2 years and deviation of the tongue to the right side for 3 months. There was no history of trauma. Clinical examination revealed a right hypoglossal nerve palsy (Fig. 4). No other neurological

abnormalities were detected. A diagnosis of posterior AOD was made based on X-ray, CT, and MRI of CVJ (Fig. 5). Powers' ratio was greater than 1 indicating AOD. X lines method also showed AOD. Harris lines (BAI) was not suggestive of AOD (Fig. 6). After re-aligning the dislocated joints using skull traction, occipitocervical fusion was performed through a posterior approach. A three-hole occipital plate with three bicortical screws were placed along with left c1 lateral mass and bilateral c3 lateral mass screws. Patient was doing well at 4 months follow-up. Neck pain had significantly decreased, hypoglossal nerve palsy was still persisting clinically although patient reported better tongue movements than earlier. Imaging showed bony fusion and good alignment (Fig. 7).

DISCUSSION

Nontraumatic AOD is rare and only a few cases have been reported. Predisposing conditions have been described earlier. Nontraumatic AOD with AAI is rarer and only one case report is available describing such a case.¹⁰ We



Figs 3A to D: Follow-up CT imaging of case 1 showing bony fusion and alignment. (A) Scout image showing instrumentation and fusion screws and occipital plate and contour rod from occiput to c2. (B) Bony fusion that has occurred between occipital condyle (1), c1 lateral mass (2), and c2 (3) on right side. (C) Posterior bony fusion from occiput to c1. Note the bicortical purchase of occipital screw. Note the reduction of AAD and BI. (D) Bony fusion that has occurred between occipital condyle (1), c1 lateral mass (2), and c2 (3) on left side. Note the proper alignment and bony fusion with implants *in situ*

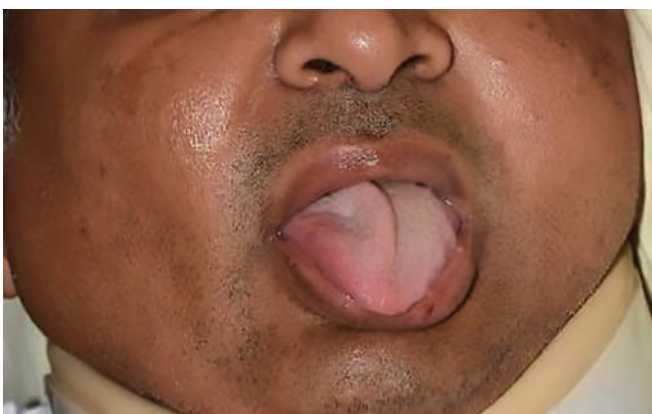
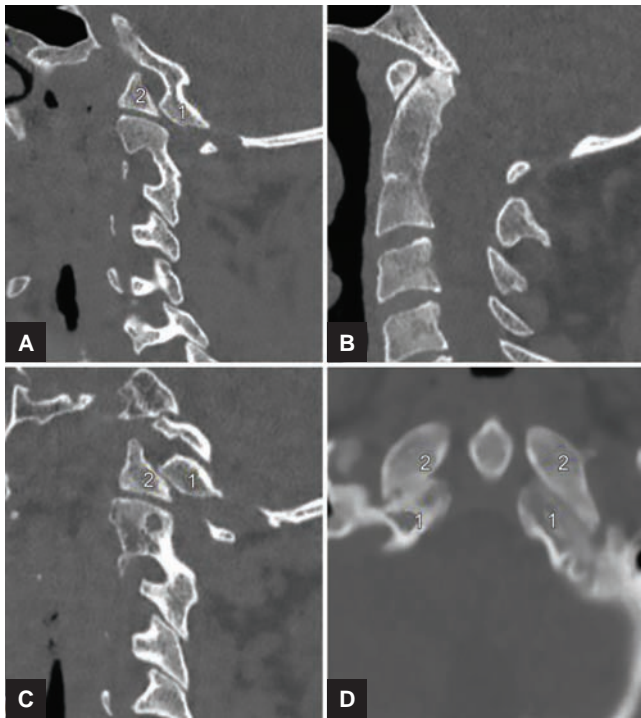

Fig. 4: Clinical image of right hypoglossal nerve palsy of case 2

had a 12-year-old child who had AOD with AAI and BI, which has never been described. Most case reports which described AOD till now were in adults. Although AOD cases are known to present with brainstem signs and lower cranial palsy, there has been no reported case of

isolated hypoglossal palsy in spontaneous AOD as seen in our case.

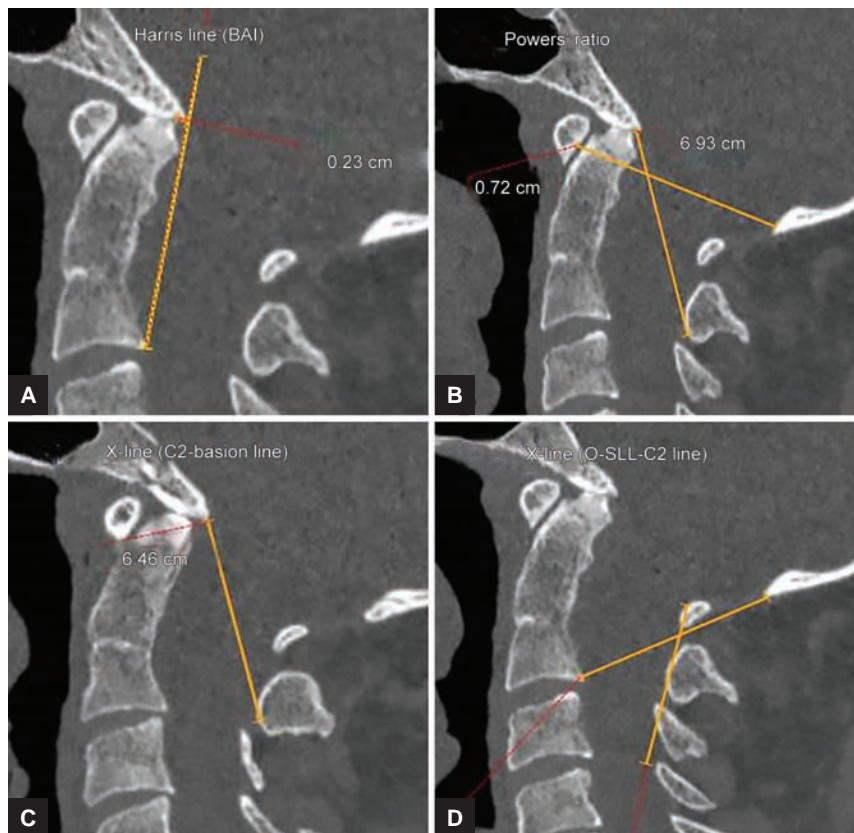
Abumi et al¹¹ reported a spontaneous posterior dislocation with a rotatory component. Interestingly, this AOD was seen only in extension position. Chowdhury et al¹² have reported two cases of spontaneous AOD in neutral position and both were posterior dislocations. A flat articulating plane between occiput and c1 lateral mass was described. They also described block c1 to c2 vertebra, thereby decreasing the movements at the c1 to c2 junction and making the AO joint more liable for dislocation. Takechi et al¹³ have described a case with spontaneous type III AOD, also associated with the flatness of c1 to c2 articular surfaces. Wu et al,¹⁰ in their case of AOD associated with AAI, also described a flatness of the occipito-c1 articulating surfaces. Most cases of spontaneous AOD described till now have been Traynelis type III or posterior dislocations. Both our cases showed posterior dislocations. It is interesting to note that a posteriorly



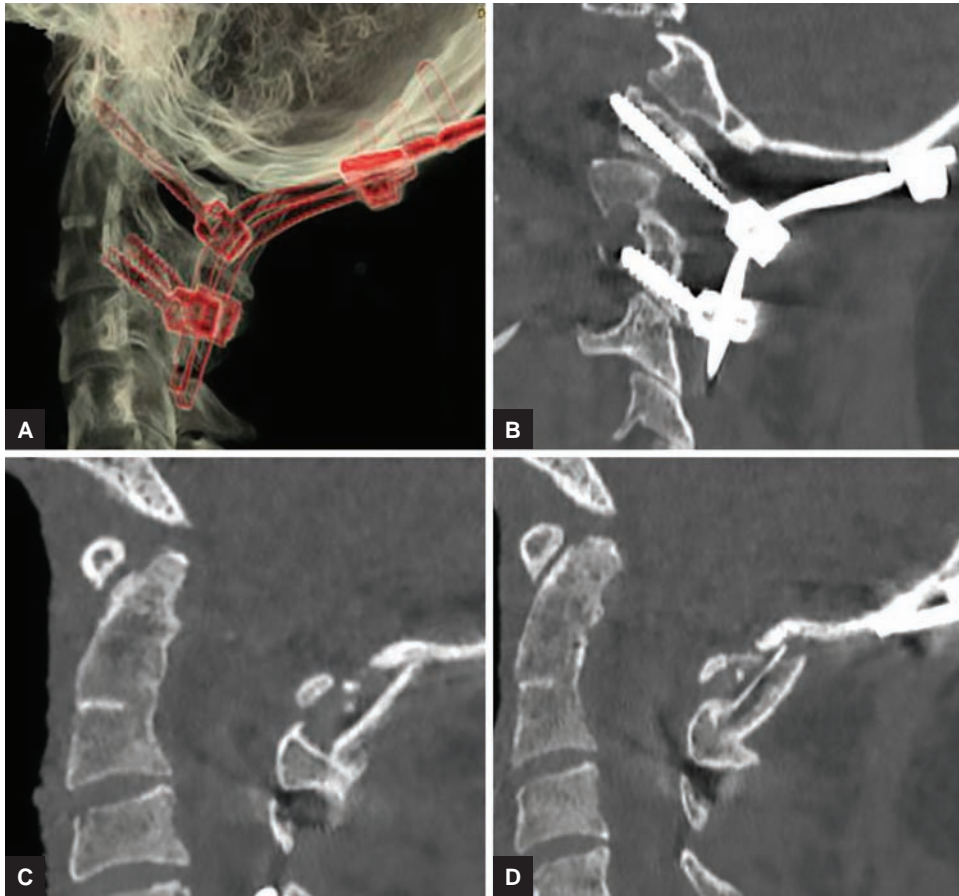
Figs 5A to D: Preoperative CT imaging of case 2. (A) Type III AOD. Note the posteriorly placed occipital condyle (1) behind the c1 lateral mass (2). Also, notice the flat articular surface between occipital condyle and c1 lateral mass. (B) Mid-sagittal section. (C) Left AO joint showing type III AOD. (D) Axial images showing the posteriorly placed occipital condyle behind the c1 lateral mass

sloping c1 lateral mass is seen in most cases, which may predispose posterior movement of occipital condyle over c1 lateral mass resulting in posterior dislocations. Both our cases showed loss of the concavo-convex articulating architecture. Also, case 2 showed c2 to c3 block vertebra which could have possibly exaggerated the movements at CVJ due to increased workload, resulting in dislocation.

We applied the described radiological criteria for AOD on our cases. In case 1, Harris line was within normal limits. X-lines—basion-c2 was abnormal, pointing toward AOD. The c2-spinolaminar line was normal. Powers’ ratio was 0.77 (normal). In case 2, both the X-lines were abnormal and Powers’ ratio was 1.03, both indicating AOD. Harris line was normal. It is to be kept in mind that most of the radiographic parameters have been described for traumatic AOD. As seen in our cases, all methods may not indicate AOD in all patients. Harris line method is the most commonly used technique and is recommended by “Guidelines for the Management of Acute Cervical Spine and Spinal Cord Injuries” on a plain lateral cervical X-ray in adults.¹⁴ However, Harris lines were normal in both our cases. Pang et al⁸ have reported that the occipital condyle–c1 distance as the most sensitive index to assess AOD and CT was their investigation of choice. Powers’ ratio cannot be used with any fracture involving the



Figs 6A to D: Applying radiographic methods : case 2. (A) The BAI is within the normal limits. (B) Powers’ ratio is >1, suggestive of AOD. (C) The Basion-c2 line is not passing tangentially on dens, indicating AOD. (D) The opisthion (O)-spinolaminar (SLL)-c2 line is not passing tangentially on posterior arch of c1, indicating AOD



Figs 7A to D: The CT images of case 2 at 4 months follow-up showing bony fusion and alignment. (A) Scout image showing bilateral c1 and c3 screws with a triple bicortical screw plate in the occipital bone with contour rods. (B) Left occipito-c1 joint showing reduction of AOD and ongoing process of bony fusion. (C) and (D) Posterior bony fusion between occiput and C2

atlas or foramen magnum, or with congenital anomalies and applies only to anterior AOD. Similarly, AOI is best reserved for type II AOD. Measurements on CT scans are more accurate than plain radiographs as landmarks are easier to identify and there is less magnification or rotation error.¹⁵ We and most other authors prefer using CT sagittal reconstruction images to define bony details.^{8,12} In fact, in the modern era where CT imaging is easily available, an obvious abnormal anatomy between the atlas and the occiput maybe the only thing necessary to diagnose AOD.

Surgery is the recommended choice of management unless the patient is not a good candidate for surgery. Immobilization in halo cast and successful preoperative reduction has been described by Ogihara et al.¹⁶ Occipitocervical fusion with proper alignment must be achieved for good outcomes. Till now, various authorities have described different ways of achieving occipitocervical fusion.

Surgery for AOD can be broadly grouped into occipitocervical fusion techniques with or without involving the condyle-c1 joint. Abumi et al have described c0 to c1 wiring and fusion.¹¹ Gonzalez et al¹⁷ described c0 to

c1 transarticular screw placement across the AO joint in 2003 and the same idea was used for fusion in traumatic AOD by Grob.¹⁸ Condyle-c2 fixation with condylar screws and c2 screws and fusion with rods has been described by La Marca et al¹⁹ in their cadaveric study. Chowdhury et al¹² have recently described a condyle-c1 fusion with screws and plates after mobilizing the vertebral artery in two cases. Takechi et al¹³ have reported posterior atlanto-occipital fusion using the Axon system and posterior iliac graft. Wu et al¹⁰ have reported occipitocervical fusion (c0-c2) performed using occipitocervical fixation system in a case of combined AOD with AAI.

In case 1, which had associated AAI and BI, we used condylar screw on one side. In case 2, we used bilateral c3 lateral mass screws with c1 lateral mass screw on one side only as the vertebral artery was passing between c1 and c2 on the other side. We feel that the instrumentation options are to be customized for each patient depending on the anatomy. Difficult steps like mobilization of vertebral artery and condylar screw placement may not be necessary in all cases if reduction and alignment is achieved and adjacent segments are properly fused with the usage of contour rods.

The method of occipito-c1 to c2 fusion, with occipital plate and screws with contour rods would be particularly helpful in a case of AOD with AAI and BI. Other advantages include fewer chances of vertebral artery injury, hypoglossal nerve injury, decreased venous blood loss, and the familiarity with usual c1 and c2 instrumentation. It may be the only option available in a case with hypoplastic condyles.

We did not experience any difficulty in occipital plate and screw placement, even in the pediatric age group. Also, a longer segment fusion, anterolaterally as well as posteriorly, using a rib graft construct, adds to the stability.

Our follow-up is comparable with any of the previous case reports and both cases successfully achieved bony fusion and clinical stabilization.

CONCLUSION

This study, to the best of authors' knowledge, is the first article to describe spontaneous (a) AOD presenting with hypoglossal nerve palsy and (b) AOD with AAI and BI in a single institute series with long follow-up and good outcomes. We feel that the occipitocervical fusion with c1, c2 screws, occipital plate, and screws and contour rods is an excellent, simple method to achieve fusion in such rare and complicated cases.

REFERENCES

1. Washington ER. Non-traumatic atlanto-occipital and atlanto-axial dislocation; a case report. *J Bone Joint Surg Am* 1959 Mar;41-A(2):341-344.
2. Hungerford GD, Akkaraju V, Rawe SE, Young GF. Atlanto-occipital and atlanto-axial dislocations with spinal cord compression in Down's syndrome: a case report and review of the literature. *Br J Radiol* 1981 Sep;54(645):758-761.
3. Tubbs RS, Hallock JD, Radcliff V, Naftel RP, Mortazavi M, Shoja MM, Loukas M, Cohen-Gadol AA. Ligaments of the craniocervical junction. *J Neurosurg Spine* 2011 Jun;14(6):697-709.
4. Hall GC, Kinsman MJ, Nazar RG, Hruska RT, Mansfield KJ, Boakye M, Rahme R. Atlanto-occipital dislocation. *World J Orthop* 2015 Mar;6(2):236-243.
5. Traynelis VC, Marano GD, Dunker RO, Kaufman HH. Traumatic atlanto-occipital dislocation. Case report. *J Neurosurg* 1986 Dec;65(6):863-870.
6. Harris JH Jr, Carson GC, Wagner LK, Kerr N. Radiologic diagnosis of traumatic occipitovertebral dissociation: 2. Comparison of three methods of detecting occipitovertebral relationships on lateral radiographs of supine subjects. *AJR Am J Roentgenol* 1994 Apr;162(4):887-892.
7. Powers B, Miller MD, Kramer RS, Martinez S, Gehweiler JA Jr. Traumatic anterior atlanto-occipital dislocation. *Neurosurgery* 1979 Jan;4(1):12-17.
8. Pang D, Nemzek WR, Zovickian J. Atlanto-occipital dislocation—part 2: the clinical use of (occipital) condyle-C1 interval, comparison with other diagnostic methods, and the manifestation, management, and outcome of atlanto-occipital dislocation in children. *Neurosurgery* 2007 Nov;61(5):995-1015, discussion 1015.
9. Pang D, Nemzek WR, Zovickian J. Atlanto-occipital dislocation: part 1—normal occipital condyle-C1 interval in 89 children. *Neurosurgery* 2007 Sep;61(3):514-521, discussion 521.
10. Wu TL, Jia JY, Chen WC, He DW, Cheng XG. Nontraumatic posterior atlantooccipital dislocation associated with atlanto-axial instability. *Eur Spine J* 2015 May;24(Suppl 4):S619-S622.
11. Abumi K, Fujiya M, Saita M, Kaneda K. Occipitoatlantal instability associated with articular tropism. *Eur Spine J* 1998 Feb;7(1):76-79.
12. Chowdhury FH, Haque MR, Alam SM, Khaled Chowdhury SM, Khan SI, Goel A. Condylar joint fusion and stabilization (by screws and plates) in nontraumatic atlanto-occipital dislocation: technical report of 2 cases. *World Neurosurg* 2017 Nov;107:54-62.
13. Takechi Y, Iizuka H, Sorimachi Y, Ara T, Nishinome M, Takagishi K. Non-traumatic posterior atlanto-occipital joint dislocation. *Eur Spine J* 2011 Jul;20(Suppl 2):S172-S175.
14. Theodore N, Aarabi B, Dhall SS, Gelb DE, Hurlbert RJ, Rozzelle CJ, Ryken TC, Walters BC, Hadley MN. The diagnosis and management of traumatic atlanto-occipital dislocation injuries. *Neurosurgery* 2013 Mar;72(Suppl 2):114-126.
15. Dziurzynski K, Anderson PA, Bean DB, Choi J, Levenson GE, Marin RL, Resnick DK. A blinded assessment of radiographic criteria for atlanto-occipital dislocation. *Spine (Phila Pa 1976)* 2005 Jun;30(12):1427-1432.
16. Ogiyama N, Takahashi J, Hirabayashi H, Hashidate H, Mukaiyama K, Kato H. Stable reconstruction using halo vest for unstable upper cervical spine and occipitocervical instability. *Eur Spine J* 2012 Feb;21(2):295-303.
17. Gonzalez LF, Crawford NR, Chamberlain RH, Perez Garza LE, Preul MC, Sonntag VK, Dickman CA. Craniovertebral junction fixation with transarticular screws: biomechanical analysis of a novel technique. *Journal of Neurosurgery: Spine (Phila Pa 1976)* 2003 Mar;98(2 Suppl):202-209.
18. Grob D. Transarticular screw fixation for atlanto-occipital dislocation. *Spine (Phila Pa 1976)* 2001 Mar;26(6):703-707.
19. La Marca F, Zubay G, Morrison T, Karahalios D. Cadaveric study for placement of occipital condyle screws: technique and effects on surrounding anatomic structures. *J Neurosurg Spine* 2008 Oct;9(4):347-353.