

Surgical Outcome of Spinal Intradural Extramedullary Tumors: A Single-center Prospective Study of 92 Cases—Assessment using Nurick's Grade and Visual Analog Scale

¹Vivek K Kankane, ²Neha Gupta, ³Vivek Sharma

ABSTRACT

Introduction: To account the surgical outcome of 92 patients who underwent an entire removal of intradural extramedullary tumors (IDEMs) and evaluate the factors that have an influence on the neurological symptoms and prospects of spinal IDEM tumors.

Materials and methods: Ninety-two cases of histopathologically confirmed IDEM tumors were treated surgically between July 2008 and July 2016.

There were 32 females and 60 males with a mean age of 41.52 years. The mean postoperative follow-up period was 40.27 months. The histopathological result, locations of the tumors, and clinical outcome were analyzed. Backache was assessed by the visual analog scale (VAS) and the neurologic purpose was evaluated by Nurick's grade.

The preoperative symptoms duration and the proportion of mass hold of the intradural space were evaluated. In adding up, all these factors were analyzed in relation to the degree of the preoperative symptoms and the prognosis. On the last follow-up, the magnetic resonance imaging (MRI) evaluated the tumor recurrence.

Results: The histopathological outcomes are as follows: 28 cases of meningioma, 48 cases of nerve sheath tumors (40 cases schwannoma and 8 cases neurofibroma) (in our study, we included only non-dumbbell-shaped with no extracanalicular extended, posteriorly situated nerve sheath tumors, so these groups of tumors were excised completely with only posterior approach with preservation of facet), 10 cases of an arachnoid cyst, 2 case of Tarlov cyst, 1 case of benign cystic teratoma, and 3 cases were metastasis, and our study included only posteriorly situated tumors.

The locations of the tumors were as follows: 64 cases in the thoracic region, 16 cases in the cervical region, and 12 cases in the lumbar region; postoperatively, there were two cases of cerebrospinal fluid (CSF) leakage; the majority of

diagnosis consisted of nerve sheath tumors (52.1%), followed by meningioma (30.40%). The proportion of mass occupying the intradural space was $81.65 \pm 9.01\%$. The VAS score was reduced in all cases from 7.56 ± 0.72 to 1.30 ± 0.47 ($p = 0.001$) and the Nurick's grade improved in all cases from 3.69 ± 0.92 to 1.35 ± 0.57 ($p = 0.001$).

The preoperative symptoms were correlated with only the proportion of mass occupying the intradural space (VAS; $r = 0.496$, $p = 0.016$, Nurick's grade; $r = 0.431$, $p = 0.040$). The Statistical Package for the Social Sciences (SPSS) version 22 was used for statistical study, and the Spearman correlation test and paired Student's t-test were performed. Two cases of schwannoma recurred.

Conclusion: The IDEM tumors detected by MRI are frequently benign, and excellent clinical outcome can be obtained when treated surgically.

The extent of neurologic symptoms was associated with the proportion of mass occupying the intradural space. All the tumors were capable of being excised through the posterior approach. The postoperative neurological improvement was outstanding in the entire cases. Consequently, violent surgical excision is suggested even for cases with a long period of symptoms or a rigorous neurologic deficit.

Keywords: Intradural extramedullary tumor, Nurick's grade, Prognosis, Schwannoma, Surgical outcome.

How to cite this article: Kankane VK, Gupta N, Sharma V. Surgical Outcome of Spinal Intradural Extramedullary Tumors: A Single-center Prospective Study of 92 Cases—Assessment using Nurick's grade and Visual Analog Scale. *J Spinal Surg* 2018;5(2):63-68.

Source of support: Nil

Conflict of interest: None

INTRODUCTION

Intradural extramedullary tumors are infrequent central nervous system tumors that are found only in 0.3 out of 100,000 patients each year. Even with their rarity, there are many reports of these tumors in the literature.

This study examined 92 patients who were followed up for more than 1 year after the diagnosis and underwent a total excision of the IDEM tumor.

Particularly, myelography, computed tomography (CT), and MRI allow making an easy diagnosis and accurate identification of the location of a tumor in the dura mater and its dural attachment before surgery, and a drastically better surgical outcome can be expected

¹Assistant Professor, ^{2,3}Senior Resident

¹Department of Neurosurgery, Sawai Man Singh Medical College, Jaipur, Rajasthan, India

²Department of Obstetrics and Gynecology, Ananta Institute of Medical Science and Research Centre, Udaipur, Rajasthan India

³Department of Neurosurgery, Rabindra Nath Tagore Medical College, Udaipur, Rajasthan, India

Corresponding Author: Vivek K Kankane, Assistant Professor Department of Neurosurgery, Sawai Man Singh Medical College Jaipur, Rajasthan, India, Phone: +918955337812, e-mail: vivekkankane9@gmail.com

with the use of an operating microscope.¹⁻³ We surgically managed with the pathological diagnosis, the preoperative medical history, and the clinical symptoms, the surgical management outcome and recurrence, the prognostic factors, and the reasons for a misdiagnosis.

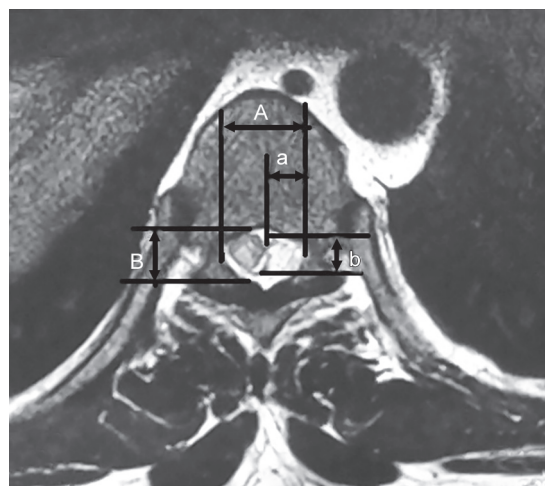
MATERIALS AND METHODS

Among the patients who had been surgically treated for IDEM tumors between July 2008 and July 2016, those patients who were available for MRI reexaminations after at least 1-year follow-up period were included in this prospective study. Every patient’s medical history, radiological assessment documentation, and the findings of the physical examination that were performed in an outpatient setting were investigated. There were 92 patients (92 cases; male:female = 60:32) and their mean age was 41.52 years (12–70 years).

Preoperative lower extremity ache was assessed by using a 10-point VAS. For the evaluation of the preoperative neurological function, the patients’ ambulation ability was graded into five levels according to the Nurick’s grading system (Table 1).⁴

For the assessment of postoperative improvement, the patients’ neurological symptoms were observed during a query and the objective examinations were graded. The proportion of the mass that occupied the intradural space was investigated to find any relations and to decide the statistical significance with the preoperative symptoms and the final surgical outcome.

The proportion of tumor occupying the intradural space was calculated on the axial image showing the maximum size as follows (Fig. 1): [(the transverse width of the tumor mass + the longitudinal width of the tumor mass)/(the transverse width of the intradural space + the longitudinal width of the intradural space)] × 100. The analysis of recurrence was based on the MRI scans that were performed at the last follow-up. The SPSS ver. 22 was used for statistical analysis and the Spearman correlation test and paired Student’s t-test were performed. In our study, we included only non-dumbbell-shaped with no extracanalicular extended nerve sheath tumors so these groups of tumors were excised completely with



Figs 1A and B: Calculation of the percentage of tumor occupying the intradural space on an axial MRI film: $\{(a + b)/(A + B)\} \times 100$. (A) Transverse diameter of the intradural space; (B) longitudinal diameter of the intradural space

only posterior approach with preservation of facet.²² Laminectomy with preservation of facet and tumor resection was performed through a posterior approach in all cases because of all tumors of study group situated posteriorly with no extracanalicular extension. Excisions were performed in all cases.

A complete excision was made, when a nerve fiber was attached to a tumor, and a nerve stimulator was used to determine if it was a sensory or motor nerve branch. The sensory nerve branch was excised while the motor nerve branch was preserved through careful detachment and then finished the excision of the IDEM tumors between the nearby ordinary structures and the tumor.

Nerve root scarification was required mostly in nerve sheath tumor in 48 cases , 26 nerve sheath tumors were situated in dorsal region and 16 tumors situated in cervical region; we did dorsal nerve root excision in only 10 cases; all were situated in dorsal region, and we excised all tumor completely so only two patients had recurrences. Closure of the dura mater was performed with Vicryl 4-0 RB in all cases. Negative pressure drainage was performed in all the cases.

The drain was removed on the 2nd postoperative day and gait training was started on the 5th postoperative day. Results: The pathological diagnoses included 48 cases of nerve sheath tumors (52.1%), 28 cases of meningioma (30.4%), and 10 cases of arachnoid cyst (10.86%), 1 case of benign cystic teratoma (1.086%), 2 cases of Tarlov cyst (2.1%), and 3 cases of metastasis (3.26%). There were two cases of recurrence of schwannomas.

As observed on the sagittal plane images, 16 tumors were situated in the cervical spine (17.39%), 64 in the thoracic spine (69.56%), and 12 in the lumbar spine (13.04%) (Table 2). The percentage of mass occupying

Table 1: Nurick’s grading system

Grade	Description
1	Normal walk, possible clinical spinal irritation
2	Slight difficulty in walking with normal domestic and working life
3	Functional disability limiting normal work and domestic activities
4	Significant weakness making walking impossible without help
5	Bedridden or wheelchair bound

Table 2: Clinical data of all patient and histological demographic and anatomical consideration of IDEM

	All type of IDEM	Nerve sheath tumor	Meningioma	Arachnoid cyst	Metastasis	Others
Total no. (%)	92	48 (52.17%)	28 (30.43%)	10 (10.86%)	3 (3.26%)	3 (3.26%)
Male:female ratio	60/32 (1.875)	39/9 (4.33)	9/19 (0.47)	8/2 (4)	2/1 (2)	2/1 (2)
Mean age	41.52	42.03	43.38	26.45	51. 21	33.42
<i>Age group (years)</i>						
<40	23 (25%)	16 (33.33%)	2 (7.14%)	5 (50%)	0 (0%)	0 (0%)
40–60	46 (50%)	24 (50%)	16 (57.14%)	3 (33.3%)	1 (33.33%)	2 (66.66%)
>60	23 (25%)	8 (16.66%)	10 (35.57%)	2 (20%)	2 (66.66%)	1 (33.33%)
<i>Tumor location</i>						
Cervical	16 (17.39%)	16 (33.33%)	0 (0%)	0 (0%)	0 (0%)	0 (0%)
Thoracic	64 (69.56%)	26 (54.16%)	14 (100%)	5 (50%)	2 (66.66%)	1 (33.33%)
Lumbar	12 (13.04%)	6 (12.5%)	0 (0%)	5 (50%)	1 (33.33%)	2 (66.66%)
Tumor situation	All situated to post. To spinal cord	Non-dumbbell-shaped with no extracanalicular extended, posteriorly situated	Post. To spinal cord	Post. To spinal cord	Post. To spinal cord	Post. To spinal cord
<i>Symptoms</i>						
Radicular/local pain	84 (91.30%)	44 (91.66%)	26 (92.85%)	10 (100%)	2 (66.66%)	2 (66.66%)
Muscle weakness	84 (91.30%)	48 (100%)	23 (82.14%)	8 (80%)	3 (100%)	2 (66.66%)
Sensory dysfunction	72 (78.26%)	40 (83.33%)	22 (78.57%)	6 (60%)	2 (66.66%)	2 (66.66%)
Sphincter dysfunction	24 (30.43%)	12 (25%)	8 (28.57%)	2 (20%)	1 (33.33%)	1 (33.33%)
Treatment	Laminectomy with preservation of facet	Laminectomy with preservation of facet	Laminectomy with preservation of facet	Laminectomy with preservation of facet	Laminectomy with preservation of facet	Laminectomy with preservation of facet

the intradural space was $81.65 \pm 9\%$. The software, SPSS version 22, was used for statistical analysis and the Spearman correlation test and paired Student's t-test were performed.

SYMPTOMS

The mean duration of symptoms was 23.47 months (1–60 months) and the mean postoperative follow-up period was 40.27. Months (6–96 months). The most common symptoms were lower extremity ache and numbness, which were observed in 91.30% cases 9 (Table 2). The symptoms tended to be augmented during walking relatively than during bed rest and sitting. Motor weakness was also observed in 21 patients (91.30%), sensory disturbance in 18 patients (78.26%), and sphincter involvement in 7 patients (30.43%). All the case symptoms were better postoperatively.

The VAS score decreased in all the cases from an average of 7.56 ± 0.727 (6–9) preoperatively to an average of 1.30 ± 0.470 (1–2) at the last follow-up ($p = 0.001$). The average Nurick's grade improved from 3.69 ± 0.926 (2–5) preoperatively to 1.34 ± 0.572 (1–3) at the last follow-up ($p = 0.001$) (Table 3).

The preoperative symptoms measured by the VAS and the Nurick's grading system were extremely associated with the proportion of the mass occupying the intradural

Table 3: Clinical improvement

	Preoperative	Last follow-up	p-value
VAS	7.56 ± 0.72	1.30 ± 0.47	0.001
Nurick's grade	3.69 ± 0.92	1.35 ± 0.57	0.001

Table 4: Influencing factor to clinical improvement

Influencing factor	VAS	Nurick's grade	Statistical method
Occupancy (%)	0.016 ($r = 0.496$)	0.040 ($r = 0.431$)	Spearman correlation test
Symptoms duration (month)	0.564 ($r = 0.127$)	0.137 ($r = 0.320$)	Spearman correlation test

space. However, no statistically significant association or difference was found between the preoperative symptoms and the duration of symptoms and (Table 4). A significant improvement in symptoms was obtained in all the cases after surgery.

Duraplasty using a fat with fibrin glue was performed in two cases with a pseudomeningocele as a complication at the 15th postoperative day. There was no deterioration of the neurological symptoms after surgery. Signs of instability were not observed in the cases of laminectomy with facet preservation without spinal fusion.

DISCUSSION

Previous reports have stated that about 5 females and 3 males out of 1,000,000 people are affected by primary spinal tumors every year and only 2/3 of them are IDEM tumors.² Due to the infrequency of IDEM tumors, it is not easy to register a large enough study population to assess a surgical procedure for treating such tumors.

Meningiomas account for 25 to 46% of all primary intraspinal neoplasms and spinal meningioma are only 7.5 to 12.5% of all meningiomas because most meningiomas are found in the brain.⁵ Spinal meningioma is frequently located in the thoracic region and they are more common in females, which is most probably due to the influence of female hormones.⁵

With look up to the management of the dural attachment of a meningioma, there are three common procedures: (1) Some portion of the dura mater is resected with the tumor to excise any remaining tumor cells and then duraplasty is performed, (2) some of the internal dura mater is peeled off and the rest of it is sutured, or (3) the dural attachment is cauterized.⁶ In this study, the closures were performed without added procedures because all the tumors were easily divided from the dura mater and no recurrence was observed at the last follow-up.

With regard to the patient with multiple schwannomas, the 6-year preoperative medical history showed that the Nurick's grade changed from 1 to 2 over the period and the tumor size on the sagittal MRI images increased 2.38% per year at the level of T12 and 12.96% per year at the level of L3, which is contrary to the previous studies that described these schwannomas as benign, slow-growing tumors.⁷

Most authors have emphasized that the protection of nerve roots compromises achieving complete tumor removal.⁸⁻¹⁰ Yet, according to Kim et al,¹¹ only 23% of the total removal of schwannomas with functionally important nerve roots resulted in the development of neurological symptoms (not severe ones) because the nerve roots involved in the tumors had already become dysfunctional. In our study, a complete excision was made, and when a nerve fiber was attached to a tumor, a nerve stimulator was used to determine if it was a sensory or motor nerve branch.

The sensory nerve branch was excised while the motor nerve branch was preserved through careful detachment and then we finished the excision of the IDEM tumors between the nearby ordinary structures. In our study, a posterior approach was used in all the cases regardless of the location of a tumor in and relative to the spinal cord.

According to the literature, 31% of the tumors are located ventral to the spinal cord¹² and Slin'ko and Al-Qashqish¹³ claimed that an extreme lateral or an anterior

approach was necessary for the removal of these tumors. However, extreme lateral approaches require spinal fusion due to the removal of the lamina and the facet joint, and the anterior approaches are difficult to use due to the epidural venous bleeding, the limited field of view and the removal of several vertebral bodies.

Spinal cord tumors have usually been excised through total laminectomy, and this method is still used widely.¹⁴ Seppala et al¹⁵ analyzed 187 patients who had total laminectomy for spinal cord tumors and reported satisfactory prognoses. However, total laminectomy may cause spinal instability and kyphosis due to the damage to the musculoligamentous structures and posterior bony elements.

And these complications may produce neurologic symptoms by compressing the spinal cord or nerve roots. In order to prevent such complications, a total laminectomy with arthrodesis or a unilateral limited laminectomy, which was reported to be useful by Yasargil et al¹⁶ and Sim et al,¹⁷ often has to be performed.

In this study, we describe our experiences in the use of unilateral limited laminectomy to intradural-extramedullary spinal cord tumors, along with a review of the literature. In this current study, a laminectomy of the bilateral facet joints without spinal fusion was performed and patients did not have any of the above-mentioned complications. But dumbbell-shaped and extracanalicular neuroma's surgical strategy is different. Asazuma et al¹⁸ reported a new system to identify optimal surgical strategies for cervical dumbbell-shaped spinal neurinomas classified based on their shape and three-dimensional location on diagnostic MRI.¹⁹ Their categorization includes nine main axially determined groups. This categorization is based on the anatomical landmarks, such as dura mater and intervertebral foramen. The C1 and C2 vertebral body has no intervertebral foramina.

Therefore, this is used for identification of optimal surgical strategy for cervical dumbbell-shaped spinal neurinomas located below the C3 region. Surgical strategy for cervical non-dumbbell-shaped spinal neurinomas in the intradural region is different from tumors that are small, and intradural can be approached posteriorly and do laminectomy without facetectomy and spinal instrumentation. This approach can be utilized with laminoplasty hemilaminectomy to prevent postoperative subcutaneous fluid collection caused by CSF leakage, kyphotic deformity, and infection.

On the contrary, ventrally located tumors may require partial facetectomy.²⁰ Ito et al²¹ series showed that subtotal excision of dumbbell-shaped neurinomas using a posterior approach is a safer, more successful, and more minimally invasive treatment. In this study, the degree of preoperative neurological symptoms was not linked

with the duration of symptoms, the location of a tumor, or the relative location of a tumor to the spinal cord.

However, the preoperative neurological symptoms measured by the VAS and the Nurick's grading system were significantly related to the proportion of tumor mass occupying the intradural space. Our study is similar to Ahn et al,²² but our study has prospective study group with huge sample size with prolonged follow-up with minimal recurrence and postoperative complications with strong statistical analysis which make a major difference to our study. Another large study of IDEM by Byvaltsev et al²³ retrospectively investigated the clinical appearance and results of patients with spinal IDEM tumors. A total of 97 consecutive patients were evaluated including the waiting period before surgery, neurological symptoms including motor, sensory, urinary, and rectal dysfunction, modified McCormick scale, Macnab's outcome assessment of patient satisfaction, surgical procedure, tumor location, and histological diagnosis.

Surgical outcomes were not influenced by tumor location, extent of lamina resection, or histological diagnosis, but there was a correlation between greater patient improvement and a shorter waiting period before surgery. As such, the authors recommend early total resection for symptomatic spinal IDEM tumors.²³ According to el-Mahdy et al,² the postoperative recurrence rate of IDEM tumors was 16%. According to Asazuma et al,⁸ the recurrence rate of intraspinal neoplasms was 7.2 and 46% of recurrent masses were IDEM spinal tumors, which recur more commonly than other intraspinal tumors. They also reported that the ventral location of a tumor, extradural invasion, neurogenic tumors, and ependymomas were the risk factors for recurrence.

According to the study on the treatment of ependymomas by Klekamp and Samii,²⁴ the recurrence rate was 29.5% at 5 years after complete resection, and this rate was higher than that of other tumors. We believed incomplete removal of the dura mater, which is the origin of the tumor, caused the high rate of recurrence of meningioma.

In this study, the recurrence rate was found to be 2.17%. However, it is our understanding that our obtained recurrence rate is not reliable because the mean follow-up period (40.27 months) was little short and various pathological findings were included.

Earlier than the beginning of MRI, spinal cord tumors were often misdiagnosed as multiple sclerosis, syringomyelia, or a herniated nucleus pulposus.²⁵ The recent development of radiological examinations has helped to avoid such misdiagnoses, according to Shin et al.²⁶ While some authors reported that pedicle erosion, vertebral body erosion, foraminal widening, neural foramen widening, and scoliosis were found on plain radiographs in approximately 38 to 56% of patients with

an IDEM tumor,²⁷ normal findings were observed in 80 cases except for 12 cases of neural foraminal widening.

Recently, MRI was regarded as being a helpful tool with regard to tumors: In assessing the size, shape, and anatomical relations with the adjacent structures, particularly with the dura mater and spinal cord; and in determining the basic treatment guidelines and surgical approaches by allowing early detection of a metastatic tumor.²⁸ The degree of preoperative symptoms was linked with the proportion of tumor mass occupying the intradural space.

Postoperatively, remarkable improvements in neurological deficits were achieved regardless of the proportion of tumor mass occupying the intradural space, the degree of preoperative symptoms and the duration of symptoms. Therefore, surgical treatment is also recommended for spinal IDEM tumors with prolonged or severe neurological symptoms.

For making the diagnosis of IDEM tumors, taking a detailed history, a thorough physical examination and performing MRI scans on the proximal regions are suggested because the symptoms of IDEM tumors can be like those of lumbar herniated nucleus pulposus and spinal stenosis.

CONCLUSION

The IDEM tumors detected by MRI are mostly benign and good clinical outcome can be obtained when managed surgically. The extent of neurologic symptoms was correlated with the proportion of mass occupying the intradural space. All the tumors were able to be removed through the posterior approach. The postoperative neurologic recovery was outstanding in all the cases regardless of any condition. Therefore, aggressive surgical excision is recommended even for cases with a long duration of symptoms or a severe neurologic deficit.

REFERENCES

1. Albanese V, Platania N. Spinal intradural extramedullary tumors: personal experience. *J Neurosurg Sci* 2002 Mar;46(1):18-24.
2. el-Mahdy W, Kane PJ, Powell MP, Crockard HA. Spinal intradural tumours: part I-extramedullary. *Br J Neurosurg* 1999 Dec;13(6):550-557.
3. Tredway TL, Santiago P, Hrubes MR, Song JK, Christie SD, Fessler RG. Minimally invasive resection of intradural extramedullary spinal neoplasms. *Neurosurgery* 2006 Feb;58(1 Suppl):ONS52-ONS58.
4. Nurick S. The natural history and the results of surgical treatment of the spinal cord disorder associated with cervical spondylosis. *Brain* 1972 Jan;95(1):101-108.
5. Solero CL, Fornari M, Giombini S, Lasio G, Oliveri G, Cimino C, Pluchino F. Spinal meningiomas: review of 174 operated cases. *Neurosurgery* 1989 Aug;25(2):153-160.

6. Saito T, Arizono T, Maeda T, Terada K, Iwamoto Y. A novel technique for surgical resection of spinal meningioma. *Spine (Phila Pa 1976)* 2001 Aug;26(16):1805-1808.
7. Ahn DK, Jung KW, Lee S, Choi DJ, Park JS, Cha SG. A 6-year observation of multiple spinal schwannomas before excision: 1 case report. *J Korean Soc Spine Surg* 2003 Sep;10(3):277-282.
8. Asazuma T, Toyama Y, Watanabe M, Suzuki N, Fujimura Y, Hirabayashi K. Clinical features associated with recurrence of tumours of the spinal cord and cauda equina. *Spinal Cord* 2003 Feb;41(2):85-89.
9. Parsa AT, Lee J, Parney IF, Weinstein P, McCormick PC, Ames C. Spinal cord and intradural-extraparenchymal spinal tumors: current best care practices and strategies. *J Neurooncol* 2004 Aug-Sep;69(1-3):291-318.
10. Prevedello DM, Koerbel A, Tatsui CE, Truite L, Grande CV, Ditzel LF, Araújo JC. Prognostic factors in the treatment of the intradural extramedullary tumors: a study of 44 cases. *Arq Neuropsiquiatr* 2003 Jun;61(2A):241-247.
11. Kim P, Ebersold MJ, Onofrio BM, Quast LM. Surgery of spinal nerve schwannoma: risk of neurological deficit after resection of involved root. *J Neurosurg* 1989 Dec;71(6):810-814.
12. Gottfried ON, Gluf W, Quinones-Hinojosa A, Kan P, Schmidt MH. Spinal meningiomas: surgical management and outcome. *Neurosurg Focus* 2003 Jun;14(6):e2.
13. Slin'ko EI, Al-Qashqish II. Intradural ventral and ventrolateral tumors of the spinal cord: surgical treatment and results. *Neurosurg Focus* 2004 Jul;17(1):ECP2.
14. Cervoni L, Celli P, Cantore G, Fortuna A. Intradural tumors of the cauda equina: a single institution review of clinical characteristics. *Clin Neurol Neurosurg* 1995 Feb;97(1):8-12.
15. Seppala M, Haltia M, Sankila R, Jääskeläinen J, Heiskanen O. Long-term out-come after removal of spinal neurofibroma: a clinicopathological study of 187 cases. *J Neurosurg* 1995 Oct;83(4):621-626.
16. Yasargil MG, Tranmer BI, Adamson TE, Roth P. Unilateral partial hemi-laminectomy for the removal of extra- and intramedullary tumours and AVMs. *Adv Tech Stand Neurosurg* 1991 Jan;18:113-132.
17. Sim JE, Noh SJ, Song YJ, Kim HD. Removal of intradural-extramedullary spinal cord tumors with unilateral limited laminectomy. *J Korean Neurosurg Soc* 2008 May;43(5):232-236.
18. Asazuma T, Toyama Y, Maruiwa H, Fujimura Y, Hirabayashi K: Surgical strategy for cervical dumbbell tumors based on a three-dimensional classification. *Spine (Phila Pa 1976)* 2004 Jan;29(1):E10-E14.
19. Ito K, Aoyama T, Miyaoka Y, Horiuchi T, Hongo K. Surgical strategies for cervical spinal neurinomas. *Neurol Med Chir (Tokyo)* 2015 Jul;55(7):557-563.
20. Ito K, Ishizaka S, Sasaki T, Miyahara T, Horiuchi T, Sakai K, Shigeta H, Hongo K. Safe and minimally invasive laminoplastic laminotomy using an ultrasonic bone curette for spinal surgery: technical note. *Surg Neurol* 2009 Nov;72(5):470-475; discussion 475.
21. Ito K, Aoyama T, Kuroiwa M, Horiuchi T, Hongo K. Surgical strategy and results of treatment for dumbbell-shaped spinal neurinoma with a posterior approach. *Br J Neurosurg* 2014 Jun;28(3):324-329.
22. Ahn DK, Park HS, Choi DJ, Kim KS, Kim TW, Park SY. The surgical treatment for spinal intradural extramedullary tumors. *Clin Orthop Surg* 2009 Sep;1(3):165-172.
23. Byvaltsev VA, Damdinov BB, Belykh EG, Ivanova KO, Sorokovikov VA, Tsunetoshi K, Kitai R, Kikuta K. [Neurosurgical outcomes of intradural extramedullary spinal tumors in 97 cases: Siberian experience]. *No Shinkei Geka* 2017 Sep;45(9):781-787.
24. Klekamp J, Samii M. Surgical results of spinal meningiomas. *Acta Neurochir* 1996;65(Suppl):77-81.
25. Gezen F, Kahraman S, Canakci Z, Beduk A. Review of 36 cases of spinal cord meningioma. *Spine (Phila Pa 1976)* 2002 Mar;25(6):727-731.
26. Shin BJ, Lee JC, Yoon TK, Jung HW, Han SW, Kim DW, Kim KJ, Kim YI. Surgical treatments of intradural extramedullary tumor. *J Korean Soc Spine Surg* 2002 Sep;9(3):230-237.
27. Cheng MK. Spinal cord tumors in the People's Republic of China: a statistical review. *Neurosurgery* 1982 Jan;10(1):22-24.
28. Harry, N. *The spine*. 4th ed. Philadelphia (PA): WB Saunders Co; 1998. p. 1366.