

## CASE REPORT

**Attachment: Source of Retention**<sup>1</sup>Manisha Singh, <sup>2</sup>Dhanya K Budihal, <sup>3</sup>DB Nandeeshwar**ABSTRACT**

Retention is the ability of the prosthesis to resist the movement of denture away from the supporting tissues/teeth. Concern for removable partial denture (RPD) is retention when compared with other prosthesis. The use of attachment acts as a direct retainer, and how it provides retention without compromising esthetics as compared with the conventional RPD is the main goal of this report. This case report describes the use of Rhein 83 precision attachment in Kennedy's class 1 modification 1 situation.

**Keywords:** Direct retainers, Fixed removable partial denture, Precision attachments, Rhein 83.

**How to cite this article:** Singh M, Budihal DK, Nandeeshwar DB. Attachment: Source of Retention. *Int J Prosthodont Restor Dent* 2018;8(1):32-35.

**Source of support:** Nil

**Conflict of interest:** None

**INTRODUCTION**

Considering good treatment option, it is not always feasible to go for fixed dental prosthesis and implant-retained prosthesis due to several complications like severe ridge defect; so, in this situation, support from the attachment plays an important role in fulfilling patient's esthetic as well as functional demands.<sup>1</sup>

Attachment is a connection device between removable and fixed parts of combined prosthesis. It can be prefabricated or customized. The main disadvantage of this extracoronar attachments is their esthetically compromised nature when used in visible area, and there comes the need for intracoronar attachments.<sup>2</sup>

Precision attachment can be described as a retainer used in fixed and RPD construction, consisting of a metal receptacle and a closely fitting part; the former is usually contained within the normal or expanded contours of the crown of the abutment tooth, and the latter is attached to a pontic or to the denture framework.<sup>3,4</sup>

Intracoronar attachments have been used since the 4th century, but gained popularity in the 20th century with Dr Herman ES Chayes formulating the principle of internal attachments in 1906.<sup>5</sup>

Attachment is an invaluable tool in the field of restorative and implant dentistry.<sup>6</sup> It is used to overcome the problems of alignment and excessive loss of tissue in the oral cavity in the implant work.<sup>7,8</sup>

The purpose of this case report is to describe the ease of use of attachment as both clinical and laboratory technique to fulfill patient esthetic as well as functional requirements.

**CASE REPORT**

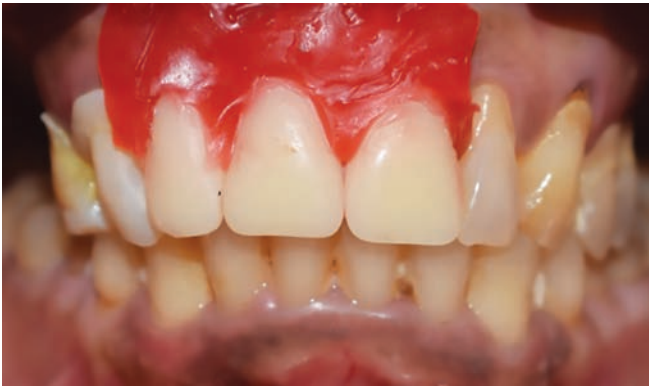This article presents a case in which nonrigid attachments were used as a mode of retention, keeping in mind the patient's esthetics, function, and financial conditions. A 38 year old patient, presented with the chief complaint of missing maxillary anterior teeth (11, 12, and 21) and posterior teeth (15, 16, 17, 26, and 27) due to caries which were extracted 6 months ago. On intraoral examination, the periodontal condition of remaining teeth was found to be good. A treatment planning of anterior nine-unit fixed partial denture (FPD) considering six abutment teeth with attachment-supported cast partial denture (CPD) was made depending on the patient's financial condition. As ridge discrepancy was seen in the anterior region, the option for implant-supported prosthesis was eliminated from the treatment plan.

Diagnostic impressions were made using alginate (3M ESPE) and poured using type III gypsum product (Kalabhai Kalstone). The diagnostic maxilla-mandibular relation was recorded and casts were articulated. A wax pattern with acrylic teeth for anterior FPD was tried in the patient's mouth for approval (Fig. 1). After consent from the patient, abutment teeth selected were 13, 14, 22, 23, 24, and 25 for fabrication of FPD considering pontic as 11, 12, and 21. The crown preparation was done in relation to 13, 14, 22, 23, 24, and 25 followed by gingival retraction using foam cord and compri cap (Figs 2 and 3). The final impression was made using monophasic silicone elastomeric impression material. A provisional bridge was given on the same day from premolar to premolar using protemp provisional cement (3M ESPE) (Fig. 4). Rhein 83 attachment was planned according to the space available and ridge contour. The metal framework try-in with Rhein 83 attachments was done intraorally and the

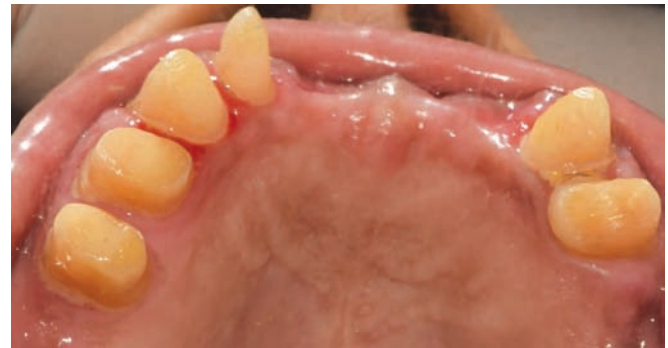<sup>1</sup>Student, <sup>2</sup>Professor, <sup>3</sup>Professor and Head

<sup>1-3</sup>Department of Prosthodontics, Bapuji Dental College & Hospital, Davangere, Karnataka, India

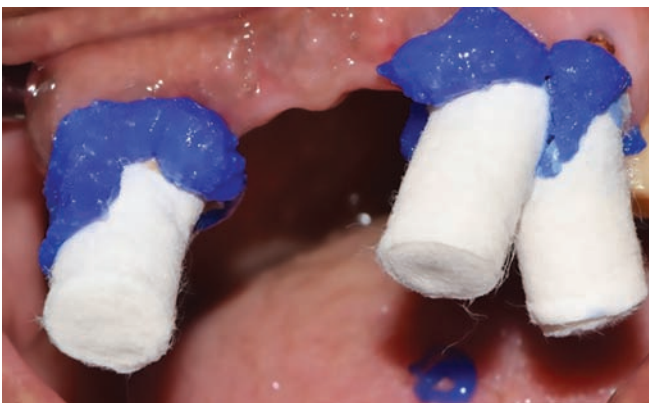**Corresponding Author:** Manisha Singh, Student, Department of Prosthodontics, Bapuji Dental College & Hospital Davangere, Karnataka, India, Phone: +917795828130, e-mail: manishasingh1391@gmail.com



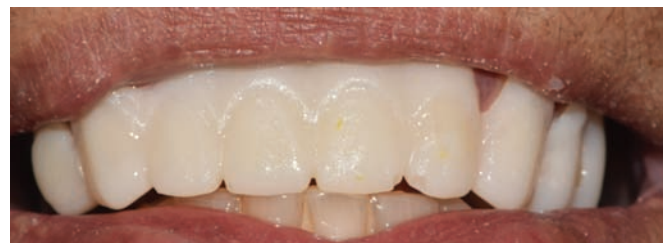**Fig. 1:** Wax up trial



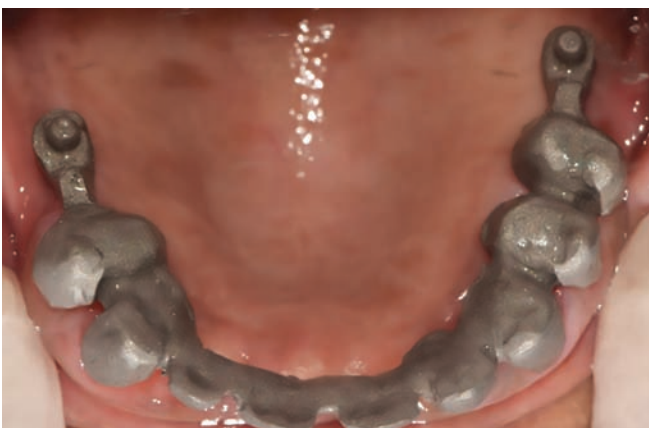**Fig. 2:** Mirror image of tooth preparation



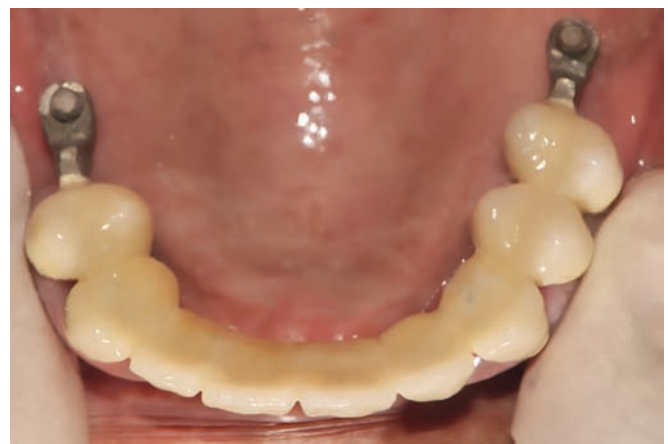**Fig. 3:** Gingival retraction using foam cord and compri caps



**Fig. 4:** Provisional bridge

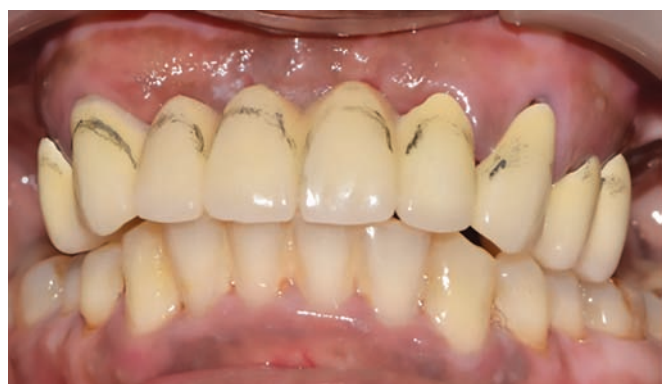

**Fig. 5:** Metal try-in of framework



**Fig. 6:** Bisque try-in

seating of the framework was checked properly followed by proper shade selection for the final porcelain build-up (Fig. 5). Upon bisque try-in of framework, overjet and overbite were visualized and zenith marking intraorally was done using a lead pencil for the replacement of ridge defect using pink porcelain (Figs 6 and 7). Framework pick-up was done using an elastomer impression material (3M ESPE) for the fabrication of CPD framework (Fig. 8). The anterior FPD was cemented after final glazing using glass ionomer cement. The CPD framework try-in was done and the maxilla-mandibular jaw relation for the



**Fig. 7:** Gingival zenith marking for gingival porcelain build-up

arrangement of posterior teeth was recorded with the framework. The CPD try-in was done and the molar relation was checked intraorally (Figs 9 and 10). The CPD

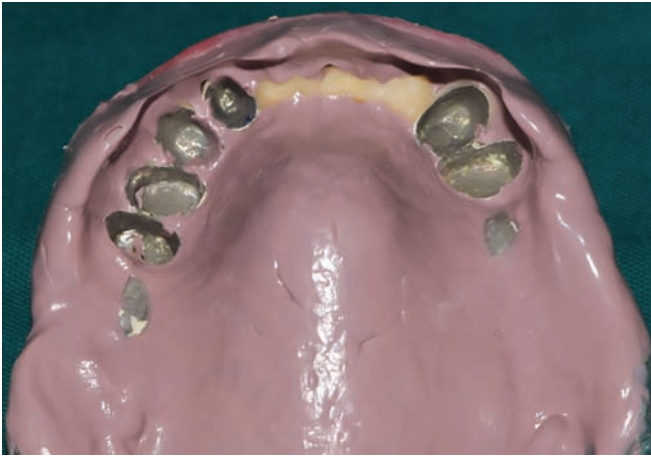


Fig. 8: Framework pick up in elastomer

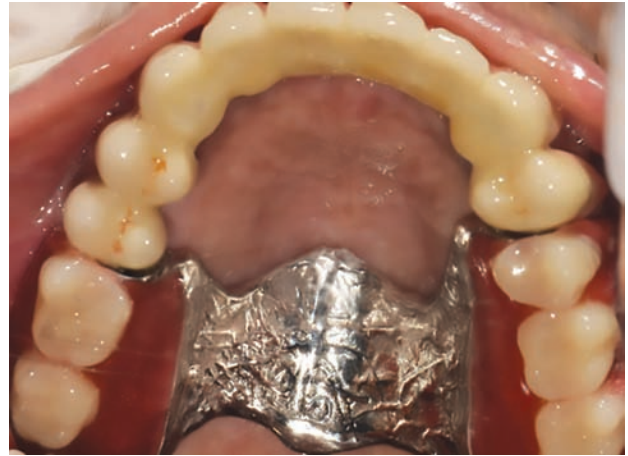

Fig. 9: Cast partial denture try-in

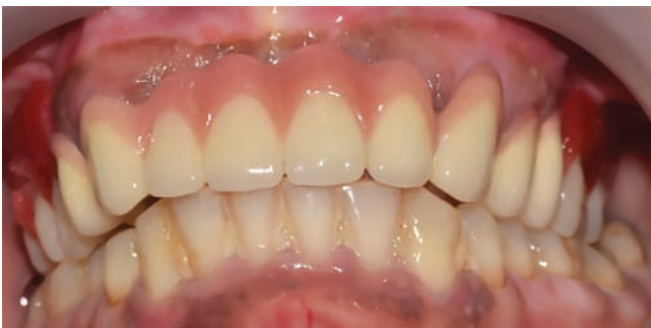

Fig. 10: Anterior FPD and posterior CPD try-in

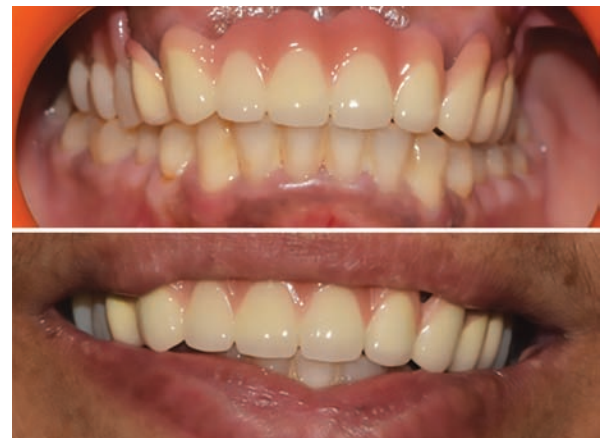

Fig. 11: Cast partial denture insertion

insertion was done with the removal of all interferences present (Fig. 11).

## DISCUSSION

In present case, Rhein 83 (OT Cap) attachment was used. With cases involving edentulous saddles, resiliency can be controlled with a wide range of retentive caps that have various levels of elasticity and retention.<sup>9</sup>

The OT Cap is a resilient distal extension attachment. It is indicated to be used with combined prostheses and RPDs.<sup>10</sup> For treatment plans that require a rigid substructure with milling and adequate counter attachments, the OT Cap functions as a stabilizing retentive connector. In addition, for treatment plans which require resiliency, the OT Cap provides a “cushion effect” similar to a shock absorber.<sup>11</sup> This is achieved by the design of the sphere in conjunction with the elastic retentive caps.<sup>5</sup>

According to the study done by Persic et al,<sup>14</sup> the treatment options can be effected by chewing and oral hygiene and esthetic demand of the patient.<sup>12,13</sup> But it is always preferred to go for attachment-retained RPD over clasp-retained RPD which gives leverage to the patient for insertion and removal of prosthesis without losing retention.<sup>14</sup>

Another method available in literature with anterior ridge discrepancy is fabrication of Andrews’s bridge as described by Cheatham et al<sup>15</sup> and Mueninghoff et al,<sup>16</sup>

but fixed treatment option is always preferred over removable most positively by patients.

## CONCLUSION

The successful prosthesis depends on correct diagnosis and treatment planning keeping in mind the patient’s financial condition. Precision attachment is a technique-sensitive procedure. A thorough understanding of different types of attachments available and knowledge of its material science is an essential part of treatment planning.

## REFERENCES

1. Munot VK, Nayakar RP, Patil R. Prosthetic rehabilitation of mandibular defects with fixed-removable partial denture prosthesis using precision attachment: a twin case report. *Contemp Clin Dent* 2017 Jul-Sep;8(3):473-478.
2. Angadi PB, Aras MA, Williams C, Nagaraal S. Precision attachments; applications and limitations. *J Evol Med Dent Sci* 2012 Dec;1(6):1113-1121.
3. Nigam A, Singh A, Shekhar A, Gupta H. Precision attachments—an overview. *J Dentofac Sci* 2013;2(3):41-44.
4. Rudd, KD.; Morrow, RM.; Eissmann, HF. *Dental laboratory procedures—removable partial dentures*. St. Louis (MO): CV Mosby; 1986.

5. Carr, AB.; McGivney, GP.; Brown, DT. McCracken's removable partial prosthodontics. 11th ed. St. Louis (MO): Elsevier Mosby; 2005.
6. Graber, G. Colour atlas of dental medicine. Vol. 2. Removable partial dentures. Stuttgart: Georg Thieme Verlag; 1988.
7. Ray GE, Alexander AG, Precision attachments. 2nd ed.
8. Mensor MC. Classification and selection of attachments. *J Prosthet Dent* 1973 May;29(5):494-497.
9. Dennis Urban CD. Occlusion and attachments: the underlying scheme for successful over dentures. *Spectr Dial* 2010 Apr;9(4):1-5.
10. Jayasree K, Bharathi M, Dileep Nag V, Vinod B. Precision attachment: retained overdenture. *J Indian Prosthodont Soc* 2012 Mar;12(1):59-62.
11. Pramod Kumar AV, Vinni TK, Mahesh MR. Full mouth rehabilitation with maxillary tooth supported and mandibular tooth and implant supported combination prostheses: a 4-year case. *J Indian Prosthodont Soc* 2012 Jun;12(2):113-119.
12. Shetty NB, Shetty S, Nagaraj E, Shetty O, D'Souza R. Precision attachments for aesthetics and function: a case report. *J Clin Diagn Res* 2014 Jan;8(1):268-270.
13. Steiger, AA.; Boitel, RH. Precision work for partial dentures. Zurich: Berichthaus; 1959.
14. Persic S, Kranjcic J, Pavicic DK, Mikic VL, Celebic A. Treatment outcomes based on patients' self-reported measures after receiving new clasp or precision attachment-retained removable partial dentures. *J Prosthodont* 2017 Feb;26(2):115-122.
15. Cheatham JL, Newland JR, Radentz WH, O'Brien R. The 'fixed' removable partial denture: report of case. *J Am Dent Assoc* 1984 Jul;109(1):57-59.
16. Mueninghoff LA, Johnson MH. Fixed-removable partial denture. *J Prosthet Dent* 1982;48(5):547-550