

# Intralesional Bleomycin as Therapeutic Modality for Low-flow Venous Malformations: Treatment on Outpatient Basis

<sup>1</sup>Abhishek Bhardwaj, <sup>2</sup>Shashank Gupta, <sup>3</sup>Rojita Moirangthem, <sup>4</sup>Abhimanyu Anant, <sup>5</sup>Naresh Bharadwaj

## ABSTRACT

**Introduction:** Venous malformations (VMs) are the most common type of vascular malformations in the human body, most commonly involving head and neck region. Intralesional sclerotherapy with and without image guidance has been used as therapeutic modality with effective outcome. The aim of our study was to evaluate the result of intralesional bleomycin injection without image guidance in low-flow VMs of head and neck.

**Materials and methods:** This was an observational study conducted in the Department of Otorhinolaryngology, Vardhman Mahavir Medical College (VMMC) and Safdarjung Hospital, New Delhi, India, between September 2014 and November 2016. Fifty-five patients, 27 males and 28 females, diagnosed as low-flow VM based on clinical features and ultrasound, were treated with multiple doses of intralesional bleomycin injection at 3 weeks interval on an outpatient basis. Reduction in size, occurrence of adverse reactions, and recurrence were observed and recorded. Outcomes were graded as complete reduction (>90% reduction), considerable reduction (50–90% reduction), partial reduction (20–50% reduction), and no change (<20% reduction). Treatment was considered successful in cases of complete or considerable reduction.

**Results:** A total of 50 (90.9%) patients were successfully treated. Complications were minor and included small skin ulcer in 4 (7.2%) and hyperpigmentation in 3 (5.4%) patients. No recurrence was noted.

**Conclusion:** Intralesional bleomycin sclerotherapy serves as an excellent treatment modality for low-flow VMs. Such patients can be treated on an outpatient basis without fear of any major complication.

**Keywords:** Bleomycin, Injections, Intralesional, Sclerotherapy, Vascular malformations.

**How to cite this article:** Bhardwaj A, Gupta S, Moirangthem R, Anant A, Bharadwaj N. Intralesional Bleomycin as Therapeutic Modality for Low-flow Venous Malformations: Treatment on Outpatient Basis. *Int J Head Neck Surg* 2017;8(3):112-117.

<sup>1,4</sup>Senior Resident, <sup>2,3</sup>Postgraduate Student, <sup>5</sup>Chief Medical Officer

<sup>1-5</sup>Department of ENT, Vardhman Mahavir Medical College & Safdarjung Hospital, New Delhi, India

**Corresponding Author:** Shashank Gupta, Postgraduate Student, Department of ENT, Vardhman Mahavir Medical College & Safdarjung Hospital, New Delhi, India, e-mail: sha2nkgupta@gmail.com

**Source of support:** Nil

**Conflict of interest:** None

## INTRODUCTION

Vascular anomalies are divided into vascular neoplasms and vascular malformations as two primary biological categories by the International Society for the Study of Vascular Anomalies (ISSVA) classification system. Vascular neoplasms include congenital hemangioma, infantile hemangioma, tufted angioma, hemangioendothelioma, angiosarcoma, and dermatologic acquired vascular neoplasms. Vascular malformations include high-flow malformations (arteriovenous malformation, arterial malformation, and arteriovenous fistula), low-flow malformations (venous, capillary, and lymphatic), and combined malformations (i.e., venolymphatic malformation). Endothelial cell turnover is high in vascular neoplasms, whereas growth in vascular malformations is in proportion to the child.<sup>1</sup> Genetic syndromes associated with vascular malformations include Kasabach–Merritt syndrome, Servelle–Martorell syndrome, Klippel–Trénaunay syndrome, and Parkes Weber syndrome, which must be excluded.<sup>2</sup>

Venous malformations consist of clusters of veins, venules, and venular capillaries. They account for about 66% of all vascular malformations and may be located anywhere in the body.<sup>3</sup> In the cervical-facial region, most common vascular anomaly is VMs, formerly referred to as “cavernous hemangiomas.” They may involve mucosa, skin, and critical neuromuscular structures. It increases gradually and finally affects appearance and organ functions if left untreated. Bleeding, speech problems, dentition distortion, or even airway obstruction may be seen in intraoral VMs.<sup>4</sup>

Clinical assessment including history and physical examination helps in establishing the diagnosis.<sup>5</sup> Venous malformation may be present at birth, which grows slowly with age. Venous malformation appears as bluish or purple compressible tumor-like formations without arterial murmur or beat on physical examination.<sup>6,7</sup> Lesion may manifest clinically as cosmetic disfigurement, bleeding, pain, ulceration, compression of nerves or adjacent structures, and functional impairments.<sup>8,9</sup>

Ultrasonography helps in differentiating high-flow from low-flow lesions and in guiding percutaneous injections during sclerotherapy procedures.<sup>10,11</sup>

Various options of treating VM include sclerotherapy, laser therapy, cryotherapy, surgical excision, and irradiation.<sup>12</sup> Difficulties encountered in surgical resection include excessive bleeding and damage to important neurovascular structures, often making complete resection challenging. Sclerotherapy serves as a good alternative with minimal complications and no external scarring. Hence, sclerotherapy is selected as the first choice for VMs in the face and neck.<sup>4,13</sup>

Many sclerosing agents, including sodium morrhuate, absolute ethanol, and bleomycin, have been used for treating VMs, each having their particular advantages and limitations. Sodium morrhuate can promote thrombosis and occlude the vascular venous vessels in the lesions and may be associated with complications, such as hematuria and ulceration if a high dose is injected. Advantages of ethanol include easy availability, low cost, and antiseptic quality. Ethanol sclerotherapy may complicate as skin necrosis, severe pain immediately after injection, neuropathy, and facial nerve injury.<sup>4,6,14</sup>

A Cu<sup>2+</sup>-containing glycoligopeptide antibiotic, bleomycin was first isolated from the culture medium of *Streptomyces verticillus*. One of the most widely used anticancer drugs after research proved its chemotherapeutic effects, bleomycin is currently also being used as a sclerosing agent.<sup>15-18</sup>

We performed direct percutaneous/perimucosal sclerotherapy using bleomycin as sclerosing agent for VMs according to the size of malformation. In the present study, we review the effects of bleomycin on VMs treated in a tertiary care hospital on an outpatient basis.

## MATERIALS AND METHODS

The study was conducted in the Department of Otorhinolaryngology, VMMC and Safdarjung Hospital at New Delhi, India, between September 2014 and November 2016. It was an observational study. All procedures contributing to this work comply with the ethical standards of the institutional guidelines on human experimentation and with the Helsinki Declaration of 1975, as revised in 2008. The diagnosis of VM was made based on clinical history and physical examination findings. Ultrasonography Doppler was done to rule out high-flow vascular malformation. Only patients having low-flow vascular malformation were taken up for percutaneous sclerosing therapy. A written informed consent was taken from all patients before sclerotherapy explaining the possible risks and complications. Study included 55 patients of VMs.

Longer and shorter axes of lesions were measured using a ruler. The longer axis was taken as reference for size. Informed consent was taken from all patients and multiple sessions of sclerotherapy were performed at an interval of 3 weeks. Patients underwent puncture of the lesion and complete aspiration of the intralesional fluid. The bleomycin was multiply injected in a radial fashion. The amount of bleomycin injected depended on the size of the malformation and ranged from 2 to 15 units per session. Patients remained under observation for approximately 1 hour before discharge.

Size of the lesion was measured and serially compared before each session. Response to the treatment (reduction in size), the occurrence of adverse reactions (inflammation, infection necrosis, and ulceration), and recurrence were observed and recorded.

Treatment was stopped when complete reduction of the swelling was achieved or if no change occurred over three treatment sessions and in case of development of adverse reaction. Outcomes were graded as complete reduction (>90% reduction), considerable reduction (50–90% reduction), partial reduction (20–50% reduction), and no change (<20% reduction). Treatment was considered successful in cases of complete or considerable reduction. Data were analyzed using Statistical Package for the Social Sciences (version 16) software with Student's t-test and Mann–Whitney test.

## RESULTS

Fifty-five patients, 27 males and 28 females, aged between 3 and 40 years (median age: 25 years), were included in the study. They were treated with percutaneous bleomycin sclerotherapy under local anesthesia on an outpatient basis between March 2014 and October 2015 and analyzed retrospectively. Patients were followed up for a period ranging from 6 to 18 months, median follow-up period being 12 months.

Most common site of VM was neck (30.9%), followed by tongue (29.09%) and face (25.4%) (Table 1).

All 55 patients presented with complaints of deformity (swelling or discoloration) while 9 (16.3%) had associated pain and 2 (3.6%) had associated bleeding. Eight patients having tongue lesions also complained of difficulty in swallowing.

**Table 1:** Sex distribution of VM in various subsites

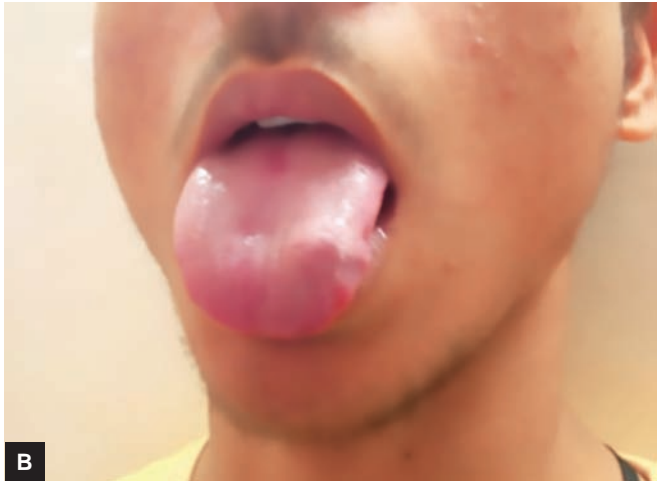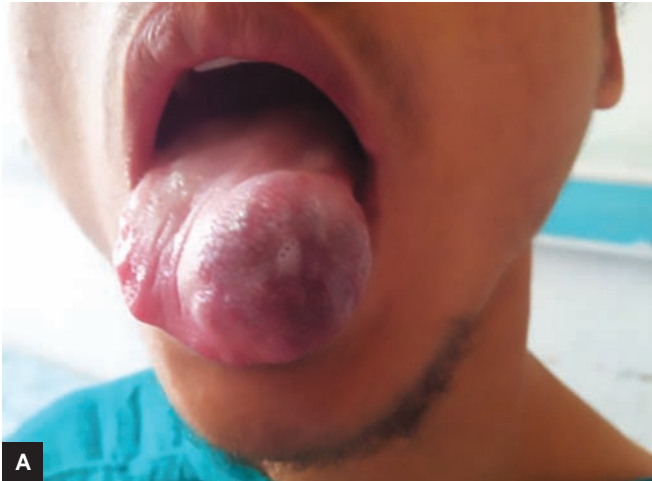	Male	Female	Total
Face	6	8	14
Tongue	6	10	16
Neck	10	7	17
Lip	4	2	6
Pinna	1	1	2

A total of 19 (34.5%) lesions measured <2 cm, 20 (36.3%) measured 2 to 4 cm, while 16 (29.1%) measured more than 4 cm (Table 2).

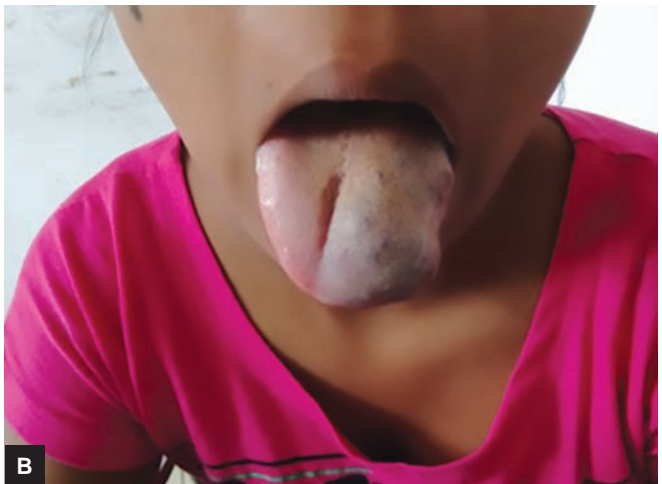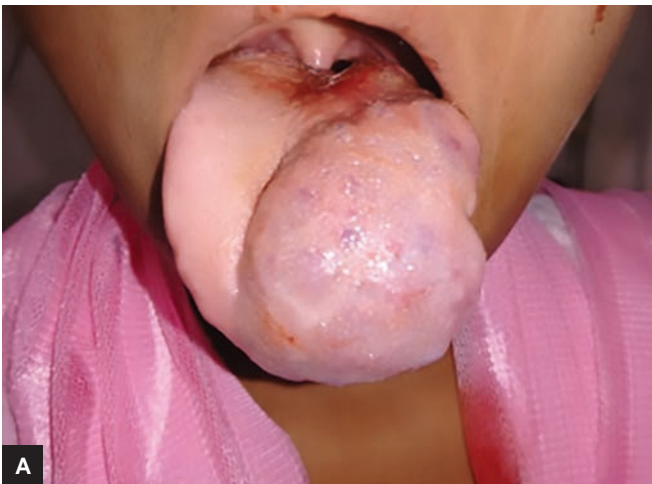Treatment was successful in 50 (90.9%) patients (Figs 1 to 5). Complete reduction was seen in 23 (41.8%) and considerable reduction in 27 (49.1%) patients (Table 3).

**Table 2:** Size of lesion (presclerotherapy) in various subsites


	<2 cm	2–4 cm	>4 cm
Face	3	9	2
Tongue	5	5	6
Neck	3	6	8
Lip	6	0	0
Pinna	2	0	0



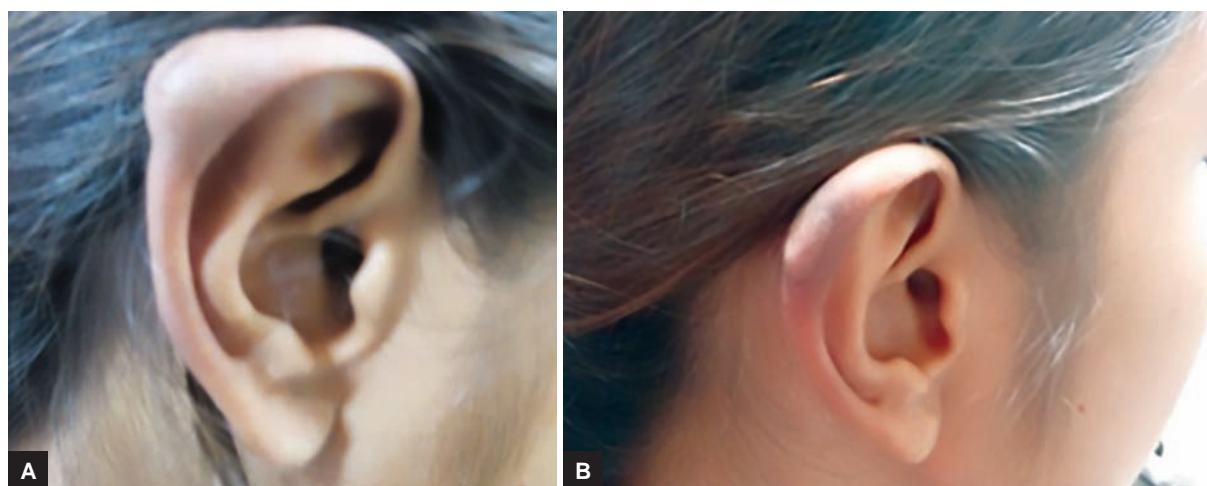
**Figs 1A and B:** Pre- and postsclerotherapy image of tongue lesion (anterior one-third) showing complete reduction



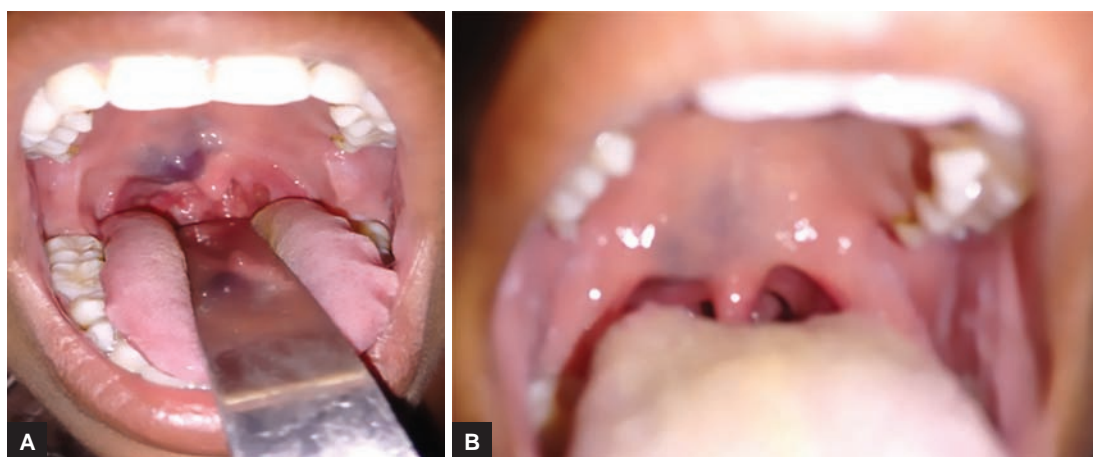
**Figs 2A and B:** Pre- and postsclerotherapy image of tongue lesion (anterior two-thirds) showing complete reduction



**Figs 3A and B:** Pre- and postsclerotherapy image of neck lesion showing complete reduction



**Figs 4A and B:** Pre- and postsclerotherapy image of pinna lesion showing complete reduction



**Figs 5A and B:** Pre- and postsclerotherapy image of soft palate lesion showing complete reduction

**Table 3:** Number of lesions with corresponding reduction in size postsclerotherapy in various subsites in relation to presclerotherapy size

		Complete (>90%)	Considerable (>50–90%)	Partial (20–50%)	No change (<20%)
Face	<2 cm	2	1	0	0
	2–4 cm	2	6	1	0
	>4 cm	0	2	0	0
Tongue	<2 cm	3	2	0	0
	2–4 cm	2	2	0	1
	>4 cm	3	3	0	0
Neck	<2 cm	2	1	0	0
	2–4 cm	1	4	1	0
	>4 cm	2	5	1	0
Lip	<2 cm	5	0	0	1
Pinna	<2 cm	1	1	0	0
<b>Total</b>		<b>23</b>	<b>27</b>	<b>3</b>	<b>2</b>

Treatment was uneventful without any complications in 48 patients (87.2%); 4 (7.2%) patients presented with small skin ulcers, while 3 (5.4%) presented with hyperpigmentation. No other complication was noted in any patient. None of the patients developed recurrence.

## DISCUSSION

Treatment options for VMs include sclerotherapy, surgical excision, cryotherapy, laser therapy, and irradiation.<sup>12</sup> Laser therapy is effective for small superficial VMs<sup>19</sup> and surgical resection for localized well-defined lesions.<sup>20</sup> Surgical excision of extensive lesions is associated with high recurrence rates, cosmetic disfigurement, and significant functional impairments.<sup>21</sup>

Intralesional sclerotherapy is a minimally invasive treatment modality for low-flow VMs and macrocystic lymphatic malformations.<sup>22</sup> This is not helpful in arteriovenous malformations which have a high flow. High-flow malformations are treated by a combination of endovascular embolization with or without surgical excision of the remaining malformation.<sup>23-25</sup> We performed intralesional sclerotherapy in patients of low-flow VMs. Preoperatively, we performed ultrasound in order to plan the best treatment modality and only low-flow VM cases were included in the study. Ultrasound serves as an inexpensive tool for making diagnosis and planning the treatment.

Bleomycin disturbs cell proliferation by snipping the deoxyribonucleic acid (DNA) chain during S stage of cell cycle.<sup>26</sup> Bleomycin was discovered in 1966 as an antitumor drug.<sup>27</sup> This drug acts by inhibiting DNA synthesis<sup>28</sup> and also affects vascular endothelium by its sclerosing characteristics.<sup>29</sup>

Bleomycin, sodium tetradecyl sulfate, polidocanol, and pure ethanol have been employed for intralesional sclerotherapy in low-flow VMs. Sodium tetradecyl sulfate (sotradecol) and polidocanol cause thrombosis and fibrosis of the lesion by interfering with cell surface lipids, resulting in endothelial damage.<sup>30</sup> Revascularization of treated lesions has been reported.<sup>31,32</sup> Sotradecol injection of extensive cephalic VM has been reported to cause complications like blindness and anaphylactic shock.<sup>7,33</sup> Intralesional ethanol administration promotes denaturing of blood proteins, vessel wall necrosis, and disruption of erythrocytes, with subsequent thrombosis and fibrosis of the intima leading to regression of the VM.<sup>34</sup> Complications reported include trophic cutaneous scars, cardiac arrhythmia, respiratory depression, hypoglycemia, and rhabdomyolysis.<sup>30,35</sup> Complications reported include infection of the injection site, superficial skin necrosis, skin blisters, and bleeding from permucosal puncture site.<sup>36</sup>

In a study by Alakailly et al,<sup>37</sup> sclerotherapy was performed without ultrasound guidance. All patients received oral analgesic and intramuscular injection of dexamethasone postsclerotherapy to reduce pain and inflammation. In our study, none of the patients received dexamethasone postsclerotherapy.

In studies by Hou et al<sup>4</sup> and Yamaki et al,<sup>13,38</sup> intralesional sclerotherapy was performed under ultrasound guidance in view of possible complications of intravascular administration, anaphylactic reactions, and reduced therapeutic effect associated with direct percutaneous therapy.<sup>13</sup> No systemic complications were reported in our study in spite of sclerotherapy being performed without ultrasound guidance. Local complications included small skin ulcer in 4 (7.2%) patients and hyperpigmentation in 3 (5.4%) patients, which improved on conservative management.

Observation of large draining veins may also preclude treatment because the peripheral extent of the sclerosant into the systemic circulation may lead to hemolysis or cardiac/pulmonary/renal complications.<sup>39</sup>

More than 90% size reduction was seen in 23 (41.8%) patients; 50 to 90% reduction was seen in 27 (49.1%) patients. Less than 50% reduction was seen in 5 (9.1%) patients. Intralesional bleomycin has been successfully used to treat hemangiomas and VMs with a success rate of 87 and 84% respectively.<sup>40</sup> In another study by Spence et al,<sup>41</sup>

37 patients with facial VMs were treated by percutaneous bleomycin sclerotherapy. The authors considered bleomycin sclerotherapy to be an effective treatment for VMs and concluded that MRI may not be required to demonstrate treatment benefits.

Sixteen out of 19 (84.2%) lesions measuring less than 2 cm showed more than 50% reduction in size. Seventeen out of 20 (85%) lesions measuring 2 to 4 cm showed more than 50% reduction in size. Fifteen out of 16 (93.7%) lesions measuring more than 4 cm showed more than 50% reduction in size. No correlation was noted between lesion size and its response to treatment in our study.

## CONCLUSION

Low-flow VMs show excellent response to intralesional bleomycin sclerotherapy. Such patients can be treated on an outpatient basis with minimum morbidity or complication. There is no correlation between lesion size and response to bleomycin sclerotherapy.

## REFERENCES

1. Lowe LH, Marchant TC, Rivard DC, Scherbel AJ. Vascular malformations: classification and terminology the radiologist needs to know. *Semin Roentgenol* 2012 Apr;47(2):106-117.
2. Parmar V, Haldeman C, Amaefuna S, Hanna AS. A vascular malformation presenting as a peripheral nerve sheath tumor. *J Brachial Plex Peripher Nerve Inj* 2016 Oct;11(1):e38-e41.
3. Paes ER, Vollmar J. Diagnosis and surgical aspects of congenital venous angiodysplasia in the extremities. *Phlebology* 1995 Dec;10(4):160-164.
4. Hou R, Guo J, Hu K, Yang Y, Wang L, Kong L, Liu G, Lei D. A clinical study of ultrasound-guided intralesional injection of bleomycin A5 on venous malformation in cervical-facial region in China. *J Vasc Surg* 2010 Apr;51(4):940-945.
5. Finn MC, Glowacki J, Mulliken JB. Congenital vascular lesions: clinical application of a new classification. *J Pediatr Surg* 1983 Dec;18(6):894-900.
6. Berenguer B, Burrows PE, Zurakowski D, Mulliken JB. Sclerotherapy of craniofacial venous malformations: complications and results. *Plast Reconstr Surg* 1999 Jul;104(1):1-11, discussion 12-15.
7. de Loriecier AA. Sclerotherapy for venous malformations. *J Pediatr Surg* 1995 Feb;30(2):188-193, discussion 194.
8. Kim KH, Sung MW, Roh JL, Han MH. Sclerotherapy for congenital lesions in the head and neck. *Otolaryngol Head Neck Surg* 2004 Sep;131(3):307-316.
9. Lee CH, Chen SG. Direct percutaneous ethanol instillation for treatment of venous malformation in the face and neck. *Br J Plast Surg* 2005 Dec;58(8):1073-1078.
10. Dubois J, Patriquin HB, Garel L, Powell J, Filiatrault D, David M, Grignon A. Soft-tissue hemangiomas in infants and children: diagnosis using Doppler sonography. *AJR Am J Roentgenol* 1998 Jul;171(1):247-252.
11. Donnelly LF, Bissett GS 3rd, Adams DM. Combined sonographic and fluoroscopic guidance: a modified technique for percutaneous sclerosis of low-flow vascular malformations. *AJR Am J Roentgenol* 1999 Sep;173(3):655-657.

12. Domp Martin A, Vikkula M, Boon LM. Venous malformation: update on aetiopathogenesis, diagnosis and management. *Phlebology* 2010 Oct;25(5):224-235.
13. Yamaki T, Nozaki M, Fujiwara O, Yoshida E. Duplex-guided foam sclerotherapy for the treatment of the symptomatic venous malformations of the face. *Dermatol Surg* 2002 Jul;28(7):619-622.
14. Yang Y, Sun M, Hou R, Yan Z, Wang L, Cheng X, Lei D, Liu Y. Preliminary study of fibrin glue combined with pingyangmycin for the treatment of venous malformations in the oral and maxillofacial region. *J Oral Maxillofac Surg* 2008 Nov;66(11):2219-2225.
15. Ming LJ. Structure and function of "metalloantibiotics". *Med Res Rev* 2003 Nov;23(6):697-762.
16. Ostrowski MJ. An assessment of the long-term results of controlling the reaccumulation of malignant effusions using intracavity bleomycin. *Cancer* 1986 Feb;57(4):721-727.
17. Shastri S, Slayton RE, Wolter J, Perlia CP, Taylor SG 3rd. Clinical study with bleomycin. *Cancer* 1971 Nov;28(5):1142-1146.
18. Hassan Y, Osman AK, Altyeb A. Noninvasive management of hemangioma and vascular malformation using intralesional bleomycin injection. *Ann Plast Surg* 2013 Jan;70(1):70-73.
19. Derby LD, Low DW. Laser treatment of facial venous vascular malformations. *Ann Plast Surg* 1997 Apr;38(4):371-378.
20. Ethunandan M, Mellor TK. Haemangiomas and vascular malformations of the maxillofacial region-a review. *Br J Oral Maxillofac Surg* 2006 Aug;44(4):263-272.
21. Kane WJ, Morris S, Jackson IT, Woods JE. Significant hemangiomas and vascular malformations of the head and neck: clinical management and treatment outcomes. *Ann Plast Surg* 1995 Aug;35(2):133-143.
22. Jackson IT, Carreno R, Potparic Z, Hussain K. Hemangiomas, vascular malformations, and lymphovenous malformations: classification and methods of treatment. *Plast Reconstr Surg* 1993 Jun;91(7):1216-1230.
23. Kohout MP, Hansen M, Pribaz JJ, Mulliken JB. Arteriovenous malformations of the head and neck: natural history and management. *Plast Reconstr Surg* 1998 Sep;102(3):643-654.
24. Han MH, Seong SO, Kim HD, Chang KH, Yeon KM, Han MC. Craniofacial arterio-venous malformation: preoperative embolization with direct puncture and injection of n-butyl cyanoacrylate. *Radiology* 1999 Jun;211(3):661-666.
25. Kim JY, Kim DI, Do YS, Lee BB, Kim YW, Shin SW, Byun HS, Roh HG, Choo IW, Hyon WS, et al. Surgical treatment for congenital arteriovenous malformation: 10 years' experience. *Eur J Vasc Endovasc Surg* 2006 Jul;32(1):101-106.
26. Luo QF, Zhao FY. The effects of Bleomycin A5 on infantile maxillofacial haemangioma. *Head Face Med* 2011 Jul;7:11.
27. Umezawa H, Suhara Y, Takita T, Maeda K. Purification of bleomycin. *J Antibiot (Tokyo)* 1966 Sep;19(5):210-215.
28. Lopez-Larrazza D, De Luca JC, Bianchi NO. The kinetics of DNA damage by bleomycin in mammalian cells. *Mutation Res* 1990 Sep;232(1):57-61.
29. Yura J, Hashimoto T, Tsuruga N, Shibata K. Bleomycin treatment for cystic hygroma in children. *Nihon Geka Hokan* 1977 Sep;46(5):607-614.
30. Pascarella L, Bergan JJ, Yamada C, Mekenas L. Venous angioma: treatment with sclerosant foam. *Ann Vasc Surg* 2005 Jul;19(4):457-464.
31. Burrows PE, Mason KP. Percutaneous treatment of low flow vascular malformations. *J Vasc Interv Radiol* 2004 May;15(5):431-445.
32. Mimura H, Kanazawa S, Yasui K, Fujiwara H, Hyodo T, Mukai T, Dendo S, Iguchi T, Hiraki T, Koshima I, et al. Percutaneous sclerotherapy for venous malformations using polidocanol under fluoroscopy. *Acta Med Okayama* 2003 Oct;57(5):227-234.
33. Siniluoto TM, Svendsen PA, Wikholm GM, Fogdestam I, Edström S. Percutaneous sclerotherapy of venous malformations of the head and neck using sodium tetradecylsulphate (sotradecol). *Scand J Plast Reconstr Surg Hand Surg* 1997 Jun;31(2):145-150.
34. Berthelsen B, Fogdestam I, Svendsen P. Venous malformations in the face and neck. Radiologic diagnosis and treatment with absolute ethanol. *Acta Radiol Diagn (Stockh)* 1986 Mar-Apr;27(2):149-155.
35. Orlando JL, Caldas JG, Campos HG, Nishinari K, Wolosker N. Outpatient percutaneous treatment of deep venous malformations using pure ethanol at low doses under local anesthesia. *Clinics (Sao Paulo)* 2010 Sep;65(9):837-840.
36. Sachin K, Rashmi S, Manish S, Siddhartha W, Uday L. Haemangiomas and venous malformations of the head and neck: A retrospective analysis of endovascular management in 358 patients. *Indian J Plast Surg* 2013 Jan;46(1):109-116.
37. Alakailly X, Kummoona R, Quereshy FA, Baur DA, Gonzalez AE. The use of sodium tetradecyl sulphate for the treatment of venous malformations of the head and neck. *J Maxillofac Oral Surg* 2015 Jun;14(2):332-338.
38. Yamaki T, Nozaki M, Sakurai H, Takeuchi M, Soejima K, Kono T. Prospective randomized efficacy of ultrasound-guided foam sclerotherapy compared with ultrasound-guided liquid sclerotherapy in the treatment of symptomatic venous malformations. *J Vasc Surg* 2008 Mar;47(3):578-584.
39. Imbesi SG, Green DA, Cho A, Pakbaz RS. MR angiographic-guided percutaneous sclerotherapy for venous vascular malformations: a radiation dose-reduction strategy. *AJNR Am J Neuroradiol* 2016 Feb;37(2):205-209.
40. Muir T, Kirsten M, Fourie P, Dippennar N, Ionescu GO. Intralesional bleomycin injection (IBI) treatment for haemangiomas and congenital vascular malformations. *Pediatr Surg Int* 2004 Jan;19(12):766-773.
41. Spence J, Krings T, terBrugge KG, da Costa LB, Agid R. Percutaneous sclerotherapy for facial venous malformations: subjective clinical and objective MR imaging follow-up results. *AJNR Am J Neuroradiol* 2010 May;31(5):955-960.