

ORIGINAL RESEARCH

Role of Autologous Costal Cartilage Grafts in Otolaryngology Practice: A Surgical Review

¹Sanjeev Mohanty, ²Vinoth Manimaran

ABSTRACT

Aim: The aim of this article is to describe the advantages and disadvantages of the costal cartilage grafts in reconstruction from the otolaryngologist's perspective and have an analysis of the surgical review of the use of this autologous graft in reconstructive procedures.

Materials and methods: A retrospective case series was conducted from 2010–2015. A total of 23 patients were selected and they were categorized depending on the defects and reconstructive procedures performed; 6th, 7th, and/or 8th rib grafts were harvested and carved according to the nature and site of the defect. The remodeled grafts were used for augmentation rhinoplasty (14 patients), laryngotracheal reconstruction (7 patients), and microtia repair (2 patients).

Results: The age group of study population was 8 to 57 years. All patients had improved outcomes, barring a minimal warping effect in recipient area.

Conclusion: High viability, good texture, and availability in large sum make rib grafts ideal for reconstruction in otolaryngological procedures.

Clinical significance: Knowledge of various grafts and reconstruction techniques is important for otolaryngologist practice. This study describes briefly about the techniques and role of costal cartilage grafting in the esthetically complex head and neck region.

Keywords: Autologous grafts, Costal cartilage, Laryngotracheal reconstruction, Rhinoplasty.

How to cite this article: Mohanty S, Manimaran V. Role of Autologous Costal Cartilage Grafts in Otolaryngology Practice: A Surgical Review. *Int J Head Neck Surg* 2017;8(3):93-97.

Source of support: Nil

Conflict of interest: None

INTRODUCTION

Reconstruction of facial defects and deformities is one of the most common challenges faced by otolaryngologists

in current practice. The common defects faced by them are saddle nose deformity, laryngotracheal stenosis, and congenital ear anomalies excluding that due to the resection of head and neck malignancies. The availability of allografts and autografts has minimized the resultant functional and cosmetic problems associated with these defects and deformities.¹ Both allografts and autografts have been used in practice as each has distinct advantages and disadvantages. Unlimited availability, lack of morbidity from donor site, relative ease in remodeling shape and volume of grafts are some advantages of allografts while foreign body reaction and graft extrusion are its potential disadvantages.² Among the autografts, costal cartilage is unique in providing cartilage, bone, and/or both.³ Its versatility and availability of a larger graft are important advantages.

The aim of this study is to describe the advantages and disadvantages of the costal cartilage grafts in reconstruction from otolaryngologist's perspective and have an analysis of the surgical review of the use of this autologous graft in reconstructive procedures.

MATERIALS AND METHODS

A retrospective interventional case series study was conducted in the Department of Otorhinolaryngology in a tertiary care hospital from January 2010 to December 2015. A total of 23 patients who required autologous rib cartilage grafting were included in the study. A written consent was obtained from all the patients/guardians prior to surgery. According to the site needed to be reconstructed, they were categorized into patients indicated for nasal, laryngotracheal, and auricular reconstruction (Table 1).

Among the 23 patients, 18 were male and 5 were female. The age group of the study population was 8 to 57 years. All were primary cases and revision cases were excluded from the study.

Table 1: Categorization of patients depending on diagnosis

| Diagnosis | Type of procedure | Number of patients |
|----------------------------------|--------------------------------|--------------------|
| Saddle nose deformity | Augmentation rhinoplasty | 14 |
| Subglottic and tracheal stenosis | Laryngotracheal reconstruction | 7 |
| Microtia | Microtia repair | 2 |

¹Professor and Head, ²Senior Resident

^{1,2}Department of Otolaryngology and Head and Neck Surgery Sri Ramachandra Medical College and Research Institute Chennai, Tamil Nadu, India

Corresponding Author: Vinoth Manimaran, Senior Resident Department of Otolaryngology and Head and Neck Surgery Sri Ramachandra Medical College and Research Institute Chennai, Tamil Nadu, India, Phone: +914445928500, e-mail: vinomb88@gmail.com

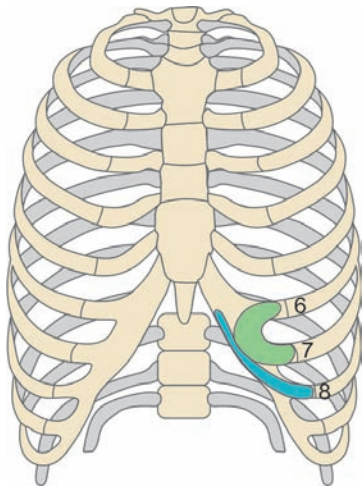


Fig. 1: Diagrammatic depiction of ribs harvested

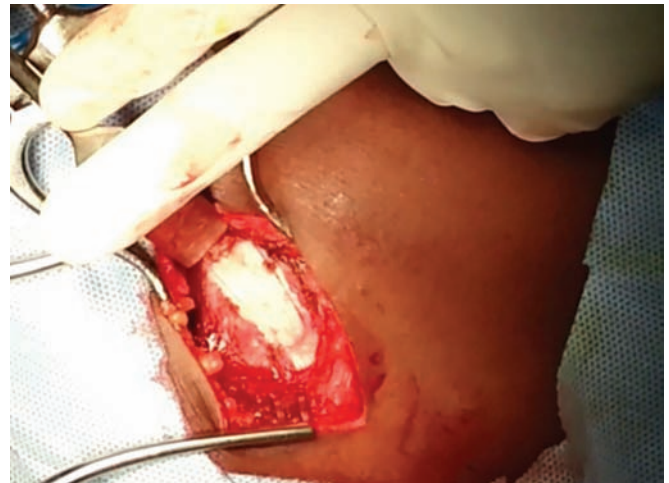

Fig. 2: Exposure of rib with removal of outer perichondrium along with graft

The preoperative clinical data of concern included the etiology, duration, site, and description of the structural, functional, and esthetic consequences of the deformity or the defect.

Preoperative and postoperative clinical photographs were taken for all ear and nose cases. Computed tomography imaging and flexible fiberoptic laryngoscopic assessment were done for all cases of laryngotracheal stenosis and graded according to Cotton–Meyer classification. The patients with only grades III and IV were included in the study.

Graft Harvesting

The 7th or 8th rib graft was harvested for rhinoplasty and laryngotracheal reconstruction while 6th, 7th, and 8th ribs (Fig. 1) were harvested for microtia repair, reason being that these cartilages are usually “C” shaped. An inframammary skin incision was given down to the muscles that were split and retracted to expose the rib. Two parallel incisions are taken along the cranial and caudal margin of the rib leaving behind 2 to 3 mm of perichondrium along the margins. The outer perichondrium in between the incisions is harvested along with the cartilage graft (Fig. 2). The inner perichondrium was always kept intact as a measure of protecting the pleura.

During harvesting, continuous palpation of the underlying rib is essential to avoid pleural injury. Pneumothorax was excluded by the absence of air leakage after filling the wound with saline solution while the anesthetist was applying positive pressure into the lungs. The wound was then infiltrated with 5 to 10 mL of 2% xylocaine and closed in layers after application of a suction drain.

For augmentation rhinoplasty, either an external or internal approach was chosen depending upon the patient status. In internal rhinoplasty, transfixation followed by bilateral intercartilagenous incision was

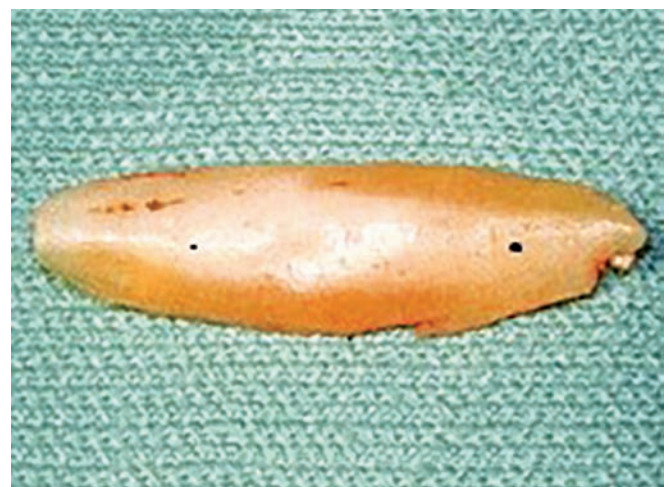

Fig. 3: Boat-shaped cartilage designed for augmentation rhinoplasty

given, while in external rhinoplasty, transcolumellar followed by bilateral marginal incision was given. In both the approaches, a dorsal pocket was created above the septum and the graft which was remodeled like a boat was placed in the pocket (Fig. 3) and incision was closed using 3-0 Vicryl.

In laryngotracheal reconstruction, after performing a laryngofissure through a horizontal skin crease incision at the level of cricoid cartilage, Montgomery T-tube was inserted through the previous tracheostome site. The refashioned costal cartilage graft was placed with the perichondrium side facing the lumen and fixed to the anterior tracheal wall using 3-0 Vicryl (Fig. 4). Suction drain was inserted and the incision was finally closed in layers. The stent was removed after 3 months.

Microtia repair was performed in two stages. In the first stage, a postauricular incision was given and a subcutaneous pocket was created. The refashioned costal cartilage graft, as shown in Figure 5, was placed

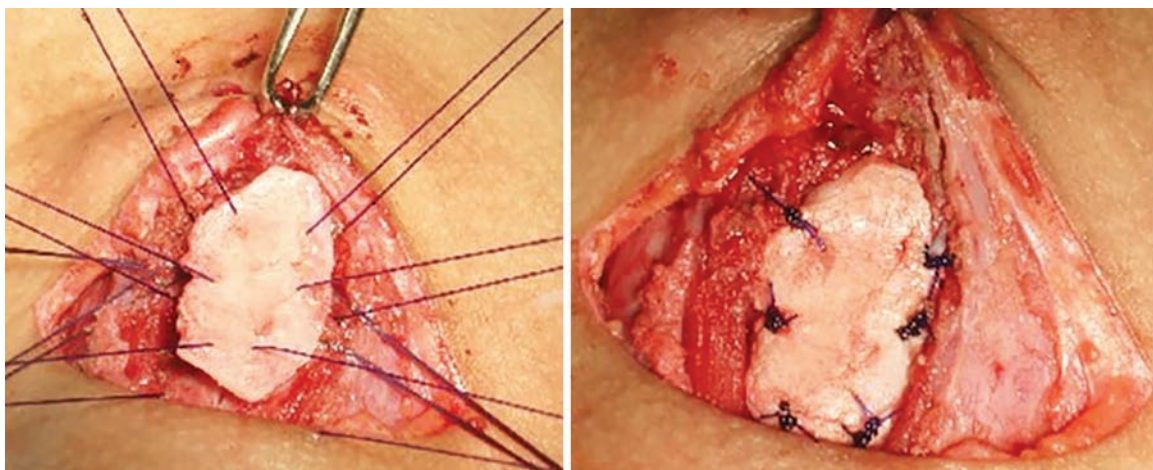


Fig. 4: Placement of anterior costal cartilage graft

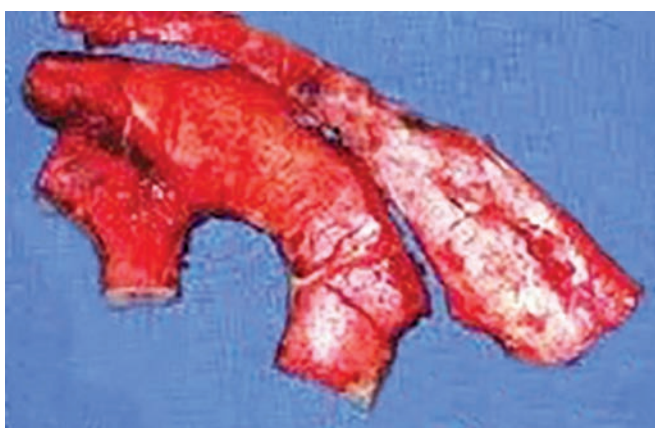


Fig. 5: Refashioned cartilage for microtia repair

in the pocket. Suction drain was inserted and wound closed. Second stage was performed after 6 months, in which the framework was released and the lobule was created. Also the postauricular region was grafted with full thickness skin.

RESULTS

Patients with Saddle Nose Deformity

A total of 14 patients in the age group of 20 to 57 years underwent augmentation rhinoplasty for saddle nose deformity. The cause of saddling in all the patients was a neglected facial trauma. None had previous attempts of surgical correction of saddling. Preoperatively, all the patients were found to have variable degrees of broadening and saddling of the nasal dorsum, shortening of the columella, rounded nostrils, and tip deformity in the form of low projection and downward rotation. Five patients additionally required tip plasty for retracted columella, which was done using Goldman's technique. Postoperatively, all the patients reported satisfactory esthetic results. None of the grafts was extruded. Wounds healed

without reported infections. Minor degree of dorsal graft warping was noted in five patients.

Patients with Subglottic Stenosis

A total of seven patients in the age group of 8 to 30 years underwent laryngotracheal reconstruction for subglottic and tracheal stenosis. These patients developed stenosis after prolonged endotracheal intubation for a period that ranged from 15 to 40 days. The causes of admission to the intensive care unit were road traffic accidents and organophosphorus poisoning. All of them had an already done tracheostomy. Preoperative endoscopic and radiologic evaluation revealed the presence of grades III or IV subglottic stenosis (Cotton–Meyer classification) with or without tracheal involvement. Vocal cords were freely mobile in all the patients. The silicone tracheal T-tube stenting was removed after 5 months and the airway was reassessed. The graft take-up rate was 100% and the patients were decannulated successfully as per surgical protocol. Three patients had granulations at the site of graft, which delayed their successful outcome for a few months. They were managed using microlaryngoscopic removal of granulations and topical application of mitomycin C. Voice change was noted in two patients, which did not hamper social communication skills.

Microtia Repair

Two patients who were 35 and 37 years old, respectively, underwent microtia repair. Both the patients had grade II microtia according to Marx classification. Two-staged repair was done. The second stage was done 6 months after the first stage. None of the patients had graft infection or rejection. Minimal warping was noted in both the patients after a period of 6 months.

As regards the donor site, control of the postoperative pain was achieved in most patients with Diclofenac

intramuscular injection once or twice daily for 3 to 5 days followed by the oral intake of Diclofenac three times daily till the end of the week. Minor wound infection was reported in two patients, which was controlled without sequels. Wound dehiscence or pneumothorax was not reported.

DISCUSSION

The surgeons' preference for grafts in reconstructing head and neck defects and deformities depends on many factors, such as the age of the patient, nature of the defects; with their consequent structural, functional, and cosmetic effects, available resources, and personal experience and training. Despite significant advances in biomedical engineering, the perfect graft material has to be attained. The rib grafts are among the sources of free nonvascularized bone and cartilage grafting materials that have versatility in otolaryngological reconstruction.

Rhinoplasty is a real challenge for esthetic surgeons. The use of costal cartilage has gained popularity among the rhinoplasty surgeons, especially in situations like saddle nose, underprojection of nasal tip, and revision cases.⁴ In spite of the availability of many alloplastic materials, silastic, high-density porous polyethylene (Medpor), and expanded polytetrafluoroethylene (Gore-Tex), autogenous cartilage is the preferred material for use since synthetic implants act as foreign bodies and have a high rate of infection and extrusion.⁵⁻⁷ Small to moderate augmentation can be managed with conchal or septal cartilage.

For laryngotracheal stenosis, though a lot of treatment options like balloon dilatation, light amplification by stimulated emission of radiation are available, open surgical procedures are preferred for grades III and IV laryngotracheal stenosis. The choice of the open surgical procedures depends on the length of the stenotic segment, anterior or posterior segmental stenosis. Segmental tracheal resection with an end-to-end anastomosis became the best method but only for short stenotic segments without involvement of the upper part of the subglottis. In long segment stenosis, tracheal reconstruction with a variety of grafting materials has been the surgical treatment of choice.⁸ The rib cartilage has been useful in this study as a grafting material in laryngotracheal reconstruction as preferred by many studies.⁹⁻¹¹ The abundance of cartilage material sufficient to reconstruct long segment, stability, strength, absence of resorption, and ease of shaping and fixation make rib grafts an ideal material for laryngotracheal reconstruction. In general, this surgery is considered successful if the patient is decannulated with an adequate comfortable breathing without the need for reintubation over a long period

of follow-up. In our study, though there was a delay in decannulation in some patients due to granulation, all were successfully decannulated.

Auricular reconstruction is always complex because of multiplicity of surgical procedures and difficulty in achieving esthetically satisfactory outcome. The various options available include silicone implants and costal cartilage grafting. Though we did auricular reconstruction in only two cases in our study, the role of cartilage grafts is well established in many studies.^{12,13}

Warping is considered to be a major disadvantage of costal cartilage grafts. Warping refers to the natural tendency of the cartilage to bend or curve over a period of time, which results in distorted esthetic profile in the postoperative period. Various theories have been proposed for warping. Gibson and Davis⁸ described that surface tension forces lead to bending of costal cartilage. Fry¹⁴ demonstrated that protein polysaccharides in the cartilage lead to internal tensile stresses that change the shape. The author feels that the combined effect of all such forces results in warping. The remedy for this has been sought since the times when Gibson and Davis⁸ described the balanced cross-sectional carving in their landmark paper in 1958. In a recent publication, Agrawal et al¹⁵ showed counterbalancing as a wise option for preventing warping.

In this study, we carved the cartilage equally on each side, and thus maintaining balanced cross-sections of the graft. Most warping occurs within 15 to 60 minutes of harvesting.¹⁶ Waiting for early warping to occur and then reshaping the graft before placement can largely diminish this problem. Although we do not have any experience, using Kirschner wires as advocated by Gunter et al⁴ could prevent possible long-term warping.

Pneumothorax is the most serious potential complication during costal cartilage harvesting, but this can easily be avoided by preservation of perichondrium on the undersurface of the rib.¹⁷ As mentioned, we did not encounter any problems with the donor site wounds or with pneumothorax. Preserving the inner perichondrium also facilitates chondrocyte growth, reduces resorption, and gives better tensile strength. The other well-known complication of rib cartilage harvesting is pain. Wee et al¹⁸ conducted a meta-analysis and considered postrib harvesting pain as a significant morbidity. This can be reduced by performing muscle "split" rather than "cut" during graft harvest, infiltration of the wound with xylocaine at the end of the procedure, and the use of postoperative analgesia.

The ample blood supply of the head and neck region which is assumed to inhibit bone graft resorption may explain the high rate of rib graft take in this study. The good osteoconductivity of the split costal cartilage graft

refers to its high content of progenitor cells which will initiate the bone formation at a short span of time.^{19,20}

CONCLUSION

Autologous rib cartilage is an outstanding option when large amounts of tissue are required. Costal cartilage has good texture and high viability and can be harvested in large quantities. These characteristics make it an excellent material for contour improvement and especially structural support. However, stating particular advantages of the rib grafts in each defect requires further studies including a larger sample size among each category of defects with a longer follow-up.

CLINICAL SIGNIFICANCE

Reconstruction of head and neck defects is one of the increasing challenges faced by otolaryngologists. Knowledge of grafts and reconstruction techniques plays a pivotal role for budding surgeons. This study briefly describes about the technique, uses, and possible complications of costal cartilage graft in the reconstruction of this esthetically and anatomically complex region.

REFERENCES

- Gurtner GC, Evans GR. Advances in head and neck reconstruction. *Plast Reconstr Surg* 2000 Sep;106(3):672-682.
- Ansari K, Asaria J, Hilger P, Adamson PA. Grafts and implants in rhinoplasty—techniques and long-term results. *Oper Tech Otolaryngol* 2008 Mar;19(1):42-58.
- Boyaci Z, Çelik Ö, Ateşpare A, Koca Ö. Conservative costal cartilage harvest for revision septorhinoplasty. *J Craniofac Surg* 2013 May;24(3):975-977.
- Gunter JP, Cochran CS, Marin VP. Dorsal augmentation with autogenous rib cartilage. *Semin Plast Surg* 2008 May;22(2):74-89.
- Vuyk HD, Adamson PA. Biomaterials in rhinoplasty. *Clin Otolaryngol Allied Sci* 1998 Jun;23(3):209-217.
- Lovice DB, Mingrone MD, Toriumi DM. Grafts and implants in rhinoplasty and nasal reconstruction. *Otolaryngol Clin North Am* 1999 Feb;32(1):113-141.
- Moretti A, Sciuto S. Rib grafts in septorhinoplasty. *Acta Otorhinolaryngol Ital* 2013 Jun;33(3):190-195.
- Gibson T, Davis WB. The distortion of autogenous cartilage grafts: its cause and prevention. *Br J Plast Surg* 1958;10:257-274.
- Phipps LM, Raymond JA, Angeletti TM. Congenital tracheal stenosis. *Crit Care Nurse* 2006 Jun;26(3):60-69.
- Younis RT, Lazar RH, Astor F. Posterior cartilage graft in a single-stage laryngotracheal reconstruction. *Otolaryngol Head Neck Surg* 2003 Sep;129(3):168-175.
- Pradhan T, Kapil S, Thakar A. Posterior cricoid split with costal cartilage augmentation for high subglottic stenosis. *Indian J Otolaryngol Head Neck Surg* 2008 Jun;60(2):147-151.
- Dashan Y, Haiyue J, Qinghua Y, Bo P, Lin L, Tailing W, Yanmei W, Xiao Q, Hongxing Z. Technical innovations in ear reconstruction using a skin expander with autogenous cartilage grafts. *J Plast Reconstr Aesthet Surg* 2008;61 (Suppl 1):S59-S69.
- Lee TS, Lim SY, Pyon JK, Mun GH, Bang SI, Oh KS. Secondary revisions due to unfavourable results after microtia reconstruction. *J Plast Reconstr Aesthet Surg* 2010 Jun;63(6):940-946.
- Fry H. Nasal skeletal trauma and the interlocked stresses of the nasal septal cartilage. *Br J Plast Surg* 1967 Apr;20(2):146-158.
- Agrawal KS, Bachhav M, Shrotriya R. Namaste (counterbalancing) technique: overcoming warping in costal cartilage. *Indian J Plast Surg* 2015 May-Aug;48(2):123-128.
- Adams WP, Rohrich RJ, Gunter JP, Clark CP, Robinson JB. The rate of warping in irradiated and nonirradiated homograft rib cartilage: a controlled comparison and clinical implications. *Plast Reconstr Surg* 1999 Jan;103(1):265-270.
- Miranda N, Larocca CG, Aponte C. Rhinoplasty using autologous costal cartilage. *Facial Plast Surg* 2013 Jun;29(3):184-192.
- Wee JH, Park MH, Jin HR. Post-rib harvesting pain should be considered as a potential significant morbidity in reconstructive rhinoplasty. *JAMA Facial Plast Surg* 2015 May-Jun;17(3):226.
- Takumi I, Akimoto M. Catcher's mask cranioplasty for extensive cranial defects in children with an open head trauma: a novel application of partial cranioplasty. *Childs Nerv Syst* 2008 Aug;24(8): 927-932.
- Balaji SM. Mandibular cystic defect: a composite approach with rhBMP-2 and rib graft. *J Maxillofac Oral Surg* 2009 Mar;8(1):27-30.