

## CASE REPORT

# A Case of Isolated Sphenoid Sinusitis with Orbital Complication and Maxillary Osteomyelitis

<sup>1</sup>Kamalika P Roy, <sup>2</sup>Deepeshkumar R Maurya

## ABSTRACT

**Aim:** One should have a high index of suspicion to diagnose cases of isolated sphenoid sinusitis.

**Background:** Isolated acute sphenoid sinusitis is a rare clinical entity and accounts for less than 3% of all cases of sinusitis. Sphenoid sinusitis usually occurs in conjunction with infections of the other paranasal sinuses. Here, we report a case of acute isolated sphenoid sinusitis leading to orbital cellulitis and maxillary osteomyelitis.

**Case report:** Patient presented with history of sudden pain behind the right eye that progressed to loss of vision within 3 weeks. Within the next week, a draining sinus appeared in the cheek.

**Treatment:** Treatment included intravenous antibiotic, endoscopic ethmoidosphenoidotomy, and right total maxillectomy with orbital exenteration.

**Outcome:** Patient is performing his daily activities normally.

**Conclusion:** Isolated sphenoiditis with maxillary osteomyelitis is uncommon. It usually presents with subtle symptoms and illusive physical findings and, hence, a high index of suspicion is necessary. Nasoendoscopy with aid of computed tomography/magnetic resonance imaging (CT/MRI) sinuses allows for early diagnosis. Complications arise due to the close proximity of optic nerve to sphenoid.

**Clinical significance:** Early recognition of the disease is necessary to prevent persistence and progression of disease and avoid morbid complications.

**Keywords:** Complication, Headache, Isolated sphenoid sinusitis, Maxillary osteomyelitis.

**How to cite this article:** Roy KP, Maurya DR. A Case of Isolated Sphenoid Sinusitis with Orbital Complication and Maxillary Osteomyelitis. *Int J Otorhinolaryngol Clin* 2017;9(2):55-57.

**Source of support:** Nil

**Conflict of interest:** None

## BACKGROUND

Isolated acute sphenoid sinusitis is a rare clinical entity and accounts for less than 3% of all cases of sinusitis.<sup>1</sup>

<sup>1</sup>Assistant Professor, <sup>2</sup>Postgraduate Trainee

<sup>1,2</sup>Department of ENT, Down Town Hospital, Guwahati, Assam India

**Corresponding Author:** Kamalika P Roy, Assistant Professor Department of ENT, Down Town Hospital, Guwahati, Assam India, Phone: +919435492494, e-mail: kamalikaproy16@gmail.com

The common presenting complaint is headache and visual loss. Rarely, it leads to bilateral acute vision loss. Permanent blindness is reported in 10% of cases of acute sphenoiditis.<sup>2</sup>

Sphenoid sinusitis usually occurs in conjunction with infection of the other paranasal sinuses.<sup>3</sup>

Here, we report a case of acute isolated sphenoid sinusitis leading to orbital cellulitis and maxillary osteomyelitis.

## CASE REPORT

A 63-year-old male residing in Sibsagar, Assam, India, presented with a 2-month history of sudden-onset pain behind the right eye, which was dull in nature. After 1 week of retro-orbital pain, the patient developed right-sided swelling of the eyelid. There was diminished vision for 2 months, initially beginning with blurring of vision on right side for first week, which progressed to complete loss of vision within next 2 to 3 weeks. Thereafter, a draining sinus appeared in the cheek. He was a known uncontrolled diabetic for 20 years and on insulin for the last 1 year.

On examination, a discharging sinus was visible in the right nasolabial angle. There was right eye proptosis with eyelid edema, conjunctival chemosis, and movement of eye was restricted. There was only perception of light with normal papillary reaction. Left eye examination was within normal limit.

Intravenous antibiotics were started and referral to ophthalmologist was done, who confirmed the orbital cellulitis.

Noncontrast-enhanced CT of paranasal sinus was done, which showed heterogeneous opacity (Fig. 1) filling the sphenoid sinus with osteosclerotic bones in right maxilla along with multiple pathological fractures correlating with maxillary osteomyelitis (Fig. 2).

A fungal smear and pus culture and sensitivity from the discharging sinus did not reveal any fungal elements.

On endoscopic biopsy, histopathology from maxillary sinus showed inflammatory bony fragments. Specimen from the sphenoids after endoscopic ethmoidosphenoidotomy showed inflammatory polypoidal nasal mucosa. A template for obturator for hard palate was designed before the proposed surgery. Under general anesthesia, the right total maxillectomy with orbital exenteration was done (Fig. 3).

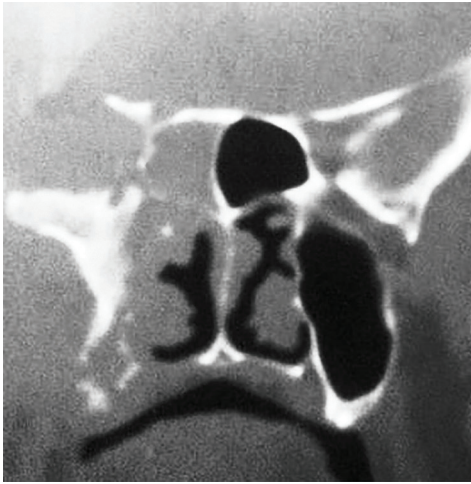


Fig. 1: Heterogeneous opacity in sphenoid sinus

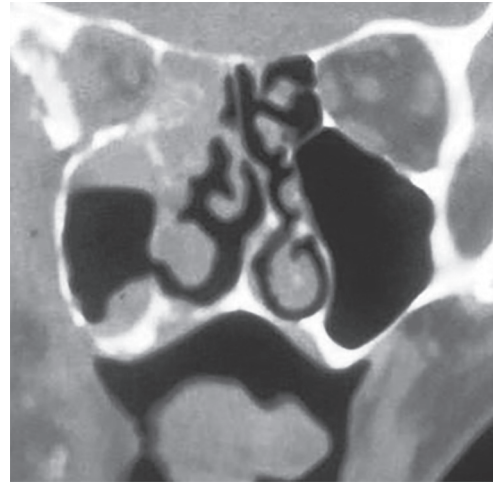
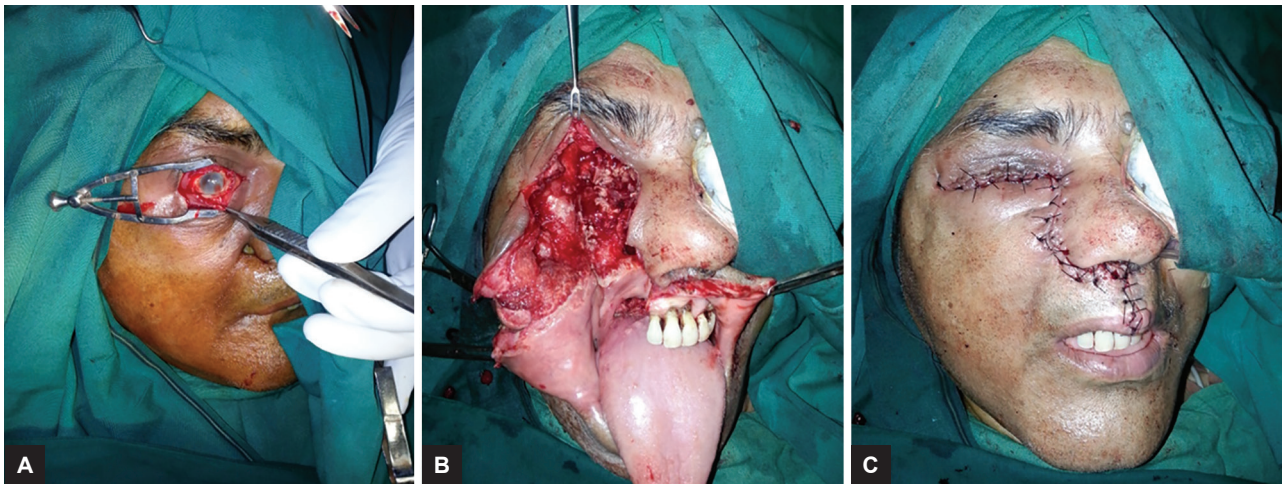


Fig. 2: Osteosclerotic bones in right maxilla with multiple pathological fractures



Figs 3A to C: Right total maxillectomy with orbital exenteration

On postoperative period, regular dressing of wound and antral wash through palatal wound were done with diluted betadine.

Patient was discharged after 7 days, and called for regular follow-up.

## DISCUSSION

The sphenoid sinus involvement in sinus disease has decreased over the years due to improvements in antibiotic therapy.<sup>4</sup> Sphenoid sinus is lined with ciliated pseudostratified epithelium with fewer mucous-secreting cells as compared with the other paranasal sinuses. This contributes to fewer drainage problems and explains the low incidence of isolated sphenoiditis.<sup>5</sup> The common presenting symptoms are headache and visual disturbances.<sup>6</sup>

Osteomyelitis of the craniofacial bones is a rare clinical entity. Osteomyelitis secondary to sinusitis is even more a rare occurrence. This generally results from inadequately treated infections of the sinuses and is aggravated by

systemic diseases that decrease host defenses like anemia, malnutrition, radiation, malignancy, osteoporosis, Paget's disease, and other conditions that decrease vascularity.<sup>5</sup> In the present case, patient was a known uncontrolled diabetic, on insulin since the past 1 year.

Osteomyelitis of maxilla is much less frequent among all craniofacial bones because of extensive maxillary blood supply, thin cortical plate, and a relatively less amount of medullary tissue in the maxilla. However, in the discussed case, osteomyelitis was restricted to maxilla.<sup>5</sup>

Isolated sphenoid sinusitis is frequently misdiagnosed because of its vague symptoms and the paucity of clinical findings. The diagnosis is often delayed until the patient suffers neurological complications,<sup>6</sup> as in the present case where optic nerve was involved.

## CONCLUSION

Isolated sphenoiditis with maxillary osteomyelitis is uncommon. It usually presents with subtle symptoms

and illusive physical findings and, hence, a high index of suspicion is necessary for diagnosis. Nasoendoscopy with the aid of CT/MRI sinuses allows for early diagnosis. Complications arise due to the close proximity of optic nerve to sphenoid sinuses.

### **CLINICAL SIGNIFICANCE**

Early recognition of the disease is necessary for preventing persistence and progression of disease and avoiding morbid complications.

### **ACKNOWLEDGMENT**

Authors would like to thank Dr Narendra Nath Dutta, Chairman and Managing Director, Down Town Hospital, Guwahati, India, for his support in publishing this article.

### **REFERENCES**

1. Lew D, Southwick FS, Montgomery WW, Weber AL, Baker AS. Sphenoid sinusitis; a review of 30 cases. *N Engl J Med* 1983 Nov;309(19):1149-1154.
2. Verma RK, Panda NK. Bilateral blindness due to acute isolated sphenoid sinusitis- is it reversible? A case report. *Otolaryngol Online J* 2015 Jul;5(3):91-96.
3. Holt GR, Standefer JA, Brown WE Jr, Gates GA. Infectious diseases of the sphenoid sinus. *Laryngoscope* 1984 Mar; 94(3):330-335.
4. Deans JA, Welch AR. Acute isolated sphenoid sinusitis: a disease with complications. *J Laryngol Otol* 1991 Dec;105(12):1072-1074.
5. Singh M, Singh S, Jain J, Singh KT. Chronic suppurative osteomyelitis of maxilla mimicking actinomycotic osteomyelitis: a rare case report. *Natl J Maxillofac Surg* 2010 Jul-Dec;1(2):153-156.
6. Tan HK, Ong YK. Acute isolated sphenoid sinusitis. *Ann Acad Med Singapore* 2004 Sep;33(5):656-659.