



CASE REPORT

A Rare Case of Herpes Zoster with Pharyngolaryngeal, Facial, and Vestibulocochlear Nerve Involvement

¹Nitty Mathew, ²Raghavendra K Suresh, ³Ganamukhi M Shivaputra, ⁴Suhel Hasan

ABSTRACT

Herpes zoster virus (HZV) infection can present as various symptoms according to site of involvement. We present a case of herpes zoster with multiple cranial nerve palsies. Patient presented with initial symptoms of otalgia, dysphagia and odynophagia. Her condition progressed to herpetic rashes over the ear, facial nerve palsy, sensorineural hearing loss and vocal cord paresis. All the lesions tended to lateralize to the right side.

Keywords: Herpes zoster, Pharyngolaryngeal herpes, Polyneuritis cranialis, Polyneuropathy, Varicella zoster.

How to cite this article: Mathew N, Suresh RK, Shivaputra GM, Hasan S. A Rare Case of Herpes Zoster with Pharyngolaryngeal, Facial, and Vestibulocochlear Nerve Involvement. *Int J Phonosurg Laryngol* 2017;7(2):75-77.

Source of support: Nil

Conflict of interest: None

INTRODUCTION

Varicella zoster virus (VZV) is an exclusively human neurotropic alpha herpes virus. Primary infection causes varicella (chickenpox), after which virus becomes latent in cranial nerve ganglia, dorsal root ganglia, and autonomic ganglia along the entire neuraxis. Years later, as cell-mediated immunity to VZV declines with age or immunosuppression, as in patients with cancer or acquired immunodeficiency syndrome or organ transplant recipients, VZV reactivates to cause zoster (shingles), a syndrome characterized by pain and a vesicular rash on an erythematous base in 1 to 3 dermatomes.¹

Ramsay-Hunt's syndrome is also known as geniculate ganglion herpes or otic zoster. Main characteristics include ipsilateral facial palsy and herpes zoster features of the auricle, external auditory canal, and tympanic membrane, and is often accompanied by neurological symptoms of the inner ear. Cases in which the facial nerve

and vestibulocochlear nerve are simultaneously involved are commonly reported, but involvement of other cranial nerves is extremely rare.² Only two cases of herpetic eruptions involving the innervated mucosa of both the glossopharyngeal nerve and vagus nerve and associated with or without unilateral facial paralysis, sudden hearing loss, and vestibulopathy have been reported in the past.³

Here we are reporting a case of pharyngolaryngeal herpes infection with involvement of facial and vestibulocochlear nerves.

CASE REPORT

A 55-year-old female patient, known diabetic and hypertensive since 2 years, on regular medications, presented to our Emergency Department with pain in the right ear of 4 days duration, dull aching type, more during night, not associated with ear discharge, tinnitus, or decreased hearing. It was associated with fever. Gradually, patient developed difficulty and pain on swallowing both liquids and solids. She was evaluated for the same from outside hospital, diagnosed as right vocal cord palsy and right acute otitis media, and started on oral antibiotics.

At the time of admission, examination of external ear appeared normal. Otoloscopic examination revealed granulation tissue in the posterior wall of right external auditory canal could be probed all around except posteriorly. Visualized part of tympanic membrane appeared intact. On oropharyngeal examination uvula was central, palatal movements equal on both sides. Gag reflex was absent. Rest of oral cavity examination appeared normal.

Magnetic resonance imaging brain was normal. Computed tomography temporal bone with contrast was done which showed soft tissue thickening in the right external auditory canal. Right mastoid was found to be pneumatized.

She was admitted and was started on Injection Ceftriaxone, Injection Amikacin, and ear drops, along with analgesics and ryle's tube feeds were initiated. On the next day, patient developed perichondritis of right ear (Fig. 1). Patient also developed ulcers and few vesicles over the right side of palate and posterior pillar. On laryngeal examination, ulcers were found over the laryngeal surface of epiglottis, right lateral, and posterior pharyngeal wall. Right hemilarynx was edematous with slough and ulcers and showed restricted movement of

¹Postgraduate Resident, ^{2,3}Consultant, ⁴Senior Consultant and Head

¹⁻⁴Department of ENT, Narayana Hrudayalaya Ltd, Bengaluru Karnataka, India

Corresponding Author: Nitty Mathew, Postgraduate Resident Department of ENT, Narayana Hrudayalaya Ltd, Bengaluru Karnataka, India, Phone: +919902519055, e-mail: nm6588@gmail.com

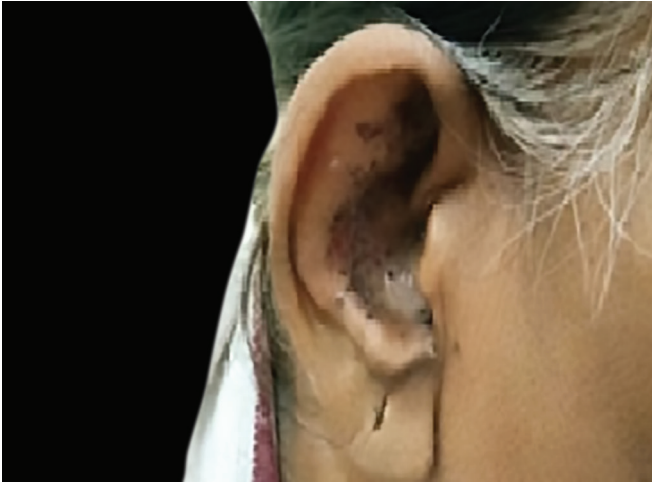

Fig. 1: Crusted vesicles over right pinna

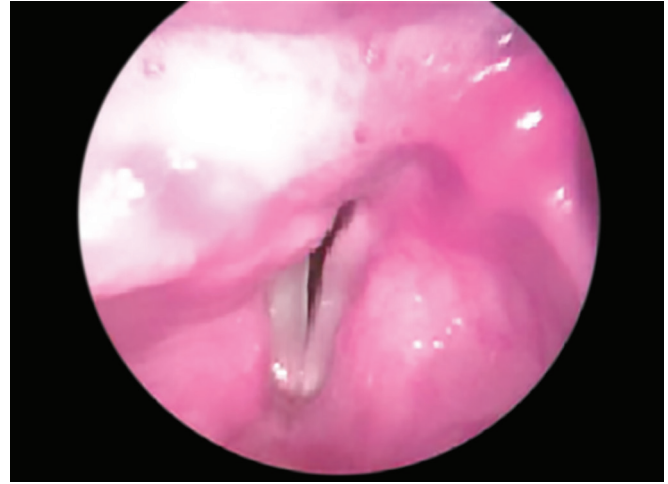


Fig. 2: Slough, ulcer over right hemilarynx, restricted right cord mobility

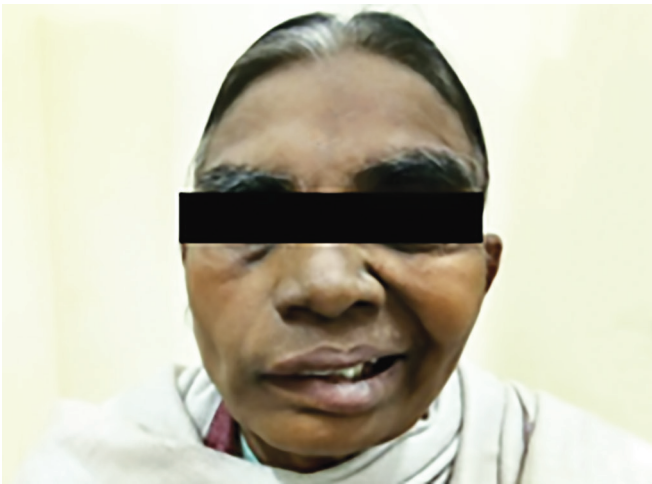

Fig. 3: Right LMN facial palsy

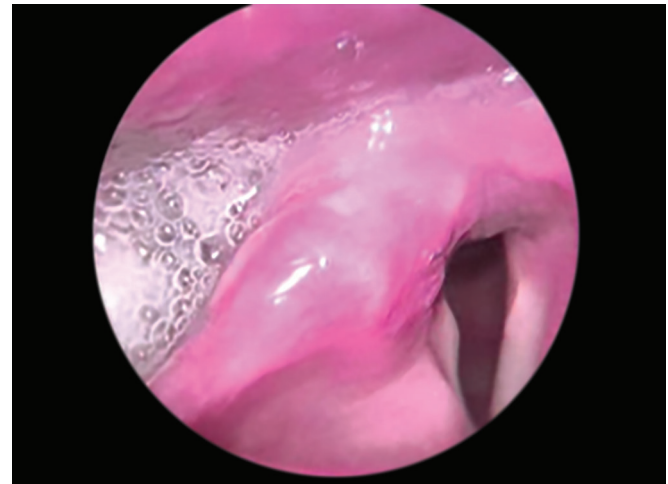


Fig. 4: Improvement of laryngeal lesions posttreatment

right vocal cord (Fig. 2). Pooling of saliva was noted in the right pyriform sinus. Left hemilarynx was normal. Audiometric evaluation of patient showed 90 dB hearing loss (sensorineural type) in the right ear, left ear being normal.

Suspecting herpes zoster, dermatologist opinion was taken. Injection Acyclovir 400 mg 5 times a day and topical acyclovir ointment for the lesions over the ear were started. Injection Ceftriaxone was discontinued on starting antivirals.

On the 2nd day of admission, she developed right-sided lower motor neuron (LMN)-type facial palsy, House–Brackmann stage 1 initially, which progressed to stage 4 over 3 days (Fig. 3). Steroids were started (injection methyl prednisolone 2 mg/kg/day). Her blood sugar levels were monitored regularly and kept under control. Facial physiotherapy was initiated.

Patient improved symptomatically. Perichondritis of right pinna and pustules in the posterior pharyngeal wall gradually subsided. Repeat laryngoscopic examination

showed improvement in right vocal cord movement and right hemilarynx edema found to be reduced (Fig. 4). Minimal phonatory gap, reduced lesions of pharynx, hypopharynx, and larynx were found. Pooling of saliva was present. Patient started taking foods orally without signs of aspiration by day 4 of starting antiviral therapy and RT feeding was discontinued.

Otomicroscopic examination of right ear revealed congested tympanic membrane and absent vesicles. Right external auditory canal appeared normal, no granulation tissue was seen, and swelling over the pinna was found reduced. Patient was discharged after 7 days of injectable antiviral therapy, on oral antiviral drugs, tapering dose of oral steroids, and analgesics for pain.

DISCUSSION

Ramsay–Hunt’s syndrome develops due to infection by HZV in the geniculate ganglion of the facial nerve, and leads to facial palsy, otalgia, and skin lesions of the auricle

and external auditory canal. In addition, symptoms, such as dizziness and hearing loss may develop following involvement of the vestibulocochlear nerve. Rarely, there have been case reports describing simultaneous involvement of the glossopharyngeal nerve and vagus nerve.²

Polyneuritis Cranialis

There have been multiple instances of polyneuritis cranialis produced by VZV. The first report was of a 70-year-old man who seroconverted to VZV during acute disease.⁴ Another report described a 43-year-old man with acute polyneuritis cranialis who developed antibody in cerebrospinal fluid (CSF) to VZV but not to other human herpes viruses or to multiple ubiquitous paramyxoviruses or togaviruses.⁵ Both men were immunocompetent. The VZV-induced polyneuritis cranialis without rash has also been described in a patient with involvement of cranial nerves IX, X, and XI as well as upper cervical nerve roots without rash, and with anti-VZV antibody in the CSF.⁶

First, invasion of cranial nerves may have been due to anatomical locations. The facial nerve joins the vestibulocochlear nerve via anterior and posterior locations of the geniculate ganglion,⁷ and on account of connection with the glossopharyngeal nerve and vagus nerve, simultaneous viral infection is possible. Secondly, the glossopharyngeal nerve, vagus nerve, accessory nerve, and hypoglossal nerve are supplied by the ascending pharyngeal artery. The facial nerve, maxillary nerve, and mandibular nerve of the trigeminal nerve are supplied by the middle meningeal artery.⁸ This supports the possibility of polyneuropathy occurring after vasculitis due to viral infection.⁹

CONCLUSION

Varicella zoster virus infection can present in various forms with the virus involving mucous membranes and causing multiple cranial nerve palsies. This therefore, demands the attention from the side of clinicians to have a look out for mucosal eruptions, signs of cranial nerve palsies in patients with VZV infections. And *vice versa*, possibility of VZV infection should be borne in mind while treating patients with multiple cranial nerve palsies. This will help in identifying the disease at an earlier stage, initiating treatment early, and decreasing the morbidity.

REFERENCES

1. Gilden D, Cohrs RJ, Mahalingam R, Nagel MA. Neurological disease produced by varicella zoster virus reactivation without rash. *Curr Top Microbiol Immunol* 2010;342:243-253.
2. Shim JH, Park JW, Kwon BS, Ryu KH, Lee HJ, Lim WH, Lee JH, Park YG. Dysphagia in Ramsay Hunt's syndrome—a case report. *Ann Rehabil Med* 2011 Oct;35(5):738-741.
3. Choi JH. Two cases of pharyngolaryngeal zoster advanced to multiple cranial neuropathy. *Am J Otolaryngol* 2013 Jul-Aug;34(4):369-372.
4. Mayo DR, Booss J. Varicella zoster associated neurologic disease without skin lesions. *Arch Neurol*. 1989;46:313-315.
5. Osaki Y, Matsubayashi K, Okumiya K, Wada T, Doi Y. Polyneuritis cranialis due to varicella-zoster virus in the absence of rash. *Neurology* 1995;45:2293.
6. Funakawa I, Terao A, Koga M. A case of zoster sine herpete with involvement of the unilateral IX, X and XI cranial and upper cervical nerves. *Rinsho Skinkeigaku* 1999;39:958-960.
7. Tschiasny K. Herpes zoster oticus (Ramsay Hunt's syndrome) comments on an article by Johnson and Zonderman. *Arch Otolaryngol* 1950 Jan;51(1):73-82.
8. Lapresle J, Lasjaunias P. Cranial nerve ischaemic arterial syndromes. A review. *Brain* 1986 Feb;109(Pt 1):207-216.
9. Kleinschmidt-DeMasters BK, Amlie-Lefond C, Gilden DH. The patterns of varicella zoster virus encephalitis. *Hum Pathol* 1996 Sep;27(9):927-938.