

Comparative Study of Tacker vs Glue Fixation of Mesh in Laparoscopic Intraperitoneal Onlay Mesh Repair of Ventral Hernias

¹Vinaya K Ambore, ²Jalbaji P More, ³Ajay H Bhandarwar, ⁴Saurabh S Gandhi, ⁵Chintan B Patel, ⁶Ravi Taori

ABSTRACT

Aim: To compare results of tacker and glue fixation of mesh in laparoscopic intraperitoneal onlay mesh repair of ventral hernias.

Materials and methods: Patients admitted to the General Surgery Department of Sir Jamshedjee Jeejeebhoy Group of Hospitals, Mumbai, India, from January 2015 to June 2016 for ventral hernia repair were included for the study. A total of 60 patients were enrolled, and each group consisted of 30 cases.

Results: In our study, the mean age of ventral hernia patients subjected for glue fixation was found to be 38 years and for tacker fixation it was found to be 38.77 years. There is no statistically significant difference among the age of cases in the two groups in terms of mean age ($p = 0.75$). Out of 60 cases, 28 (46.66%) were females, whereas 32 (53.33%) cases were males. Maximum size of hernia defect was restricted to 6 cm. The mean size of hernia defect was 2.84 ± 1.02 cm in the glue fixation group, while that in the tacker fixation group was 3.15 ± 0.731 cm. Mean duration of surgery was 83.67 minutes in the glue fixation group and 64.50 minutes in the tacker fixation group. There was no intraoperative and postoperative complications with glue fixation. In tacker fixation, seroma was seen in 4 cases (13.33%), hematoma in 1 (3%), bowel ileus in 1 (3%), whereas there were no intra-abdominal complications, bowel obstruction, bleeding from trocar site, and enterocutaneous fistula. The mean pain [visual analog scale (VAS) score] of glue fixation and tacker fixation at 24 hours was 1 and 2.23 respectively. Mean postoperative hospital stay for patients with tacker fixation is 3 days, and 2 days in glue fixation. Mean time to return to normal activities was 3 ± 0.6 days in tacker fixation group and 1 ± 0.58 days in glue fixation group. No recurrence was found in both groups of fixation methods.

Conclusion: Mesh fixation with glue is better as compared with tacker in terms of cost, postoperative pain, and length of hospital stay; however, the use of tacker or glue depends on surgeon preference, patient affordability, and availabilities of facilities.

Keywords: Glue fixation, Intraperitoneal onlay mesh, Laparoscopic, Tacker fixation, Ventral hernia.

How to cite this article: Ambore VK, More JP, Bhandarwar AH, Gandhi SS, Patel CB, Taori R. Comparative Study of Tacker vs Glue Fixation of Mesh in Laparoscopic Intraperitoneal Onlay Mesh Repair of Ventral Hernias. *World J Lap Surg* 2017;10(3):87-90.

Source of support: Nil

Conflict of interest: None

INTRODUCTION

An abdominal wall hernia, or a ventral hernia, often occurs at the weakest point of the abdominal wall and it includes umbilical, incisional, epigastric, supraumbilical, infraumbilical, etc. The intra-abdominal pressure forces the contents to move out from the defect. The protruded contents dilate the opening further, leading to increased diameter of the defect, and hence, more contents protrude. This positive feedback loop results in increase in size of hernia, and continues till either the hernia is operated, or it develops complications like obstruction, strangulation, or incarceration. The mechanism behind the continued progression of hernia can be explained by Pascal's law, which states that "A change in pressure at any point in an enclosed fluid at rest is transmitted undiminished to all points in the fluid." In this condition, the "fluid" can be taken as the abdominal cavity contents. So, a rise in pressure in the abdominal cavity is transmitted to all points along the abdomen equally.

The open technique of ventral hernia repair involved extensive dissection of surrounding tissues, which led to complications, such as wound infections, seroma formation, etc. To overcome these, laparoscopic techniques were devised. In 1991, LeBlanc and Booth described their experience with repair of incisional hernia using expanded polytetrafluoroethylene prosthetic graft using laparoscopic technique. Ever since its introduction, the trend is toward attempting a laparoscopic repair of ventral hernias. In this technique, the contents of the hernia sac are reduced and a prosthetic mesh is placed intraperitoneally/preperitoneally extending beyond the borders of the fascial defect and held in place by either staples sutures or glue.

The dilemma always persists regarding which technique is better, from a patient benefit point of view.

¹Associate Professor and Head, ^{2,6}Chief Resident, ³Professor and Head, ^{4,5}Assistant Professor

¹⁻⁶Department of General Surgery, Grant Medical College and Sir Jamshedjee Jeejeebhoy Group of Hospitals, Mumbai Maharashtra, India

Corresponding Author: Vinaya K Ambore, Associate Professor and Head, Department of General Surgery, Grant Medical College and Sir Jamshedjee Jeejeebhoy Group of Hospitals Mumbai, Maharashtra, India, Phone: +919920707170, e-mail: vinaya.ambore@gmail.com

So we conducted a comparative prospective study of laparoscopic intraperitoneal onlay mesh fixation using tacker and glue.

This study is aimed at comparing 60 patients of ventral hernias, selected randomly from patients admitted to the Sir Jamshedjee Jeejeebhoy Group of Hospitals, Mumbai, India, between the period June 2015 and June 2016.

MATERIALS AND METHODS

Research Site

Grant Government Medical College and Sir Jamshedjee Jeejeebhoy Group of Hospitals, Byculla, Mumbai, India.

Sample Size

A total of 60 cases; 30 cases assigned randomly to two groups, either tacker or glue fixation.

Inclusion Criteria

Patients diagnosed with ventral hernias clinically, patients who gave consent to undergo the procedure and be a part of the study, patients between 18 and 70 years of age, patients with ventral hernias and defect size <6 cm without any complications were included.

Exclusion Criteria

Patients with body mass index >35, patients with recurrence after previous repair, patients afflicted with chronic obstructive pulmonary disease, lower urinary tract syndromes, prostatomegaly with complaints of nocturia, patients unfit for general anesthesia, and patients with acute abdominal emergency were excluded.

CONDUCTION OF STUDY

Patients were selected for the study after taking careful detailed history, clinical examination, laboratory investigations, and ultrasound examination as described above. The patients eligible for the study were selected, informed, and explained regarding the above study and a proper informed, valid, written consent was taken for participation in the study.

Patients were kept nil by mouth after 10 pm the previous day of surgery. Patients were shaved and prepared, and informed, valid, written consent for surgery taken. All patients received preoperative dose of antibiotic. Patients were operated by experienced laparoscopic surgeons of the hospital with experience of >50 laparoscopic ventral hernia repair (LVHR) procedures done previously. All incisions were infiltrated with local anesthetic at the end of the procedure.

Duration of surgery was measured from the time of incision to the time of closure. Patients were started on liquid diet on the evening of surgery and full diet on the next morning of surgery. All patients were encouraged to mobilize as early as possible. Inj. Diclofenac sodium 50 mg intramuscular was given as analgesic postoperatively on demand by the patient as guided by the VAS in which the pain experienced by the patient was graded by the patient on a scale of 1 to 10 and recorded every 6 hourly for the first 24 hours postoperatively. Analgesics were given if VAS score was >5 (Fig. 1).

Postoperative hospital stay was measured from the date of surgery to the date of discharge. Patients were asked to follow-up on day 7, at 1 month, and 3 months postoperatively. Suture removal was on postoperative day 7 in all cases. Time to return to normal activity was noted in all patients. Patients were reassessed on all occasions and wound infection, port site herniation were checked, and all patients were followed up for minimum 6 months after surgery and were assessed for recurrence.

OBSERVATIONS AND RESULTS

The following facts and figures are observed from our study.

- In our study, 28 (46.66%) out of 60 cases were females, whereas 32 (53.33%) cases were males, which shows a higher incidence in males.
- In our study, the mean duration of surgery was 83.67 minutes in the glue fixation group, which was significantly more (p = 0.000) than the tacker fixation group where mean duration of surgery was 64.50 minutes.

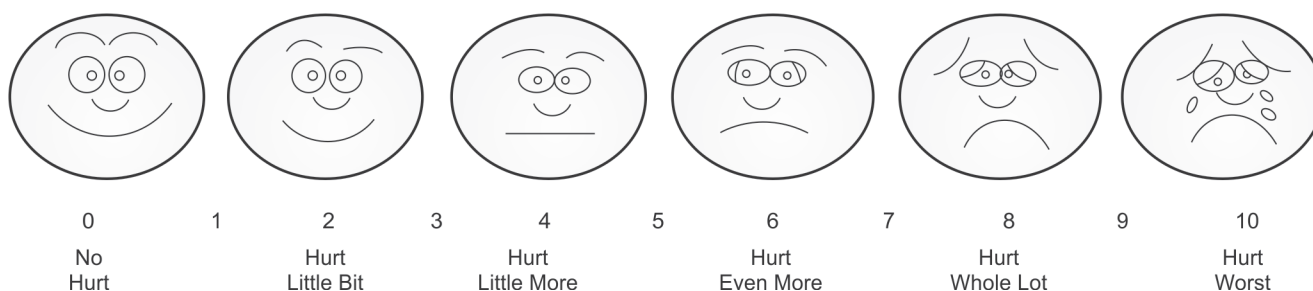


Fig. 1: Visual analog scale

There were no intraoperative and postoperative complications with glue fixation.

In tacker fixation, seroma was seen in 4 cases (13.33%), hematoma in 1 (3%), bowel ileus in 1 (3%), whereas intra-abdominal complications, bowel obstruction, bleeding from trocar site, and enterocutaneous fistula were 0 (0%). The glue fixation group did have a lesser complication rate 0/30 (0%) as compared with 6/30 (20%) in tacker group.

Pain is a reliable criterion in the assessment of any ventral hernia repair, due to the extent of dissection involved. The postoperative pain was recorded at 24 hours, 48 hours, and 1 month after operation by using VAS pain scoring system. The mean pain score of glue fixation and tacker fixation at 24 hours was 1 and 2.23 respectively ($p = 0.00$) (Table 1 and Graph 1).

Median (range) postoperative hospital stay for patients with tacker fixation is 3 (2–4) days, which is more as compared with 2 (1–3) days in glue fixation, which is statistically significant ($p < 0.0001$) (Table 2 and Graph 2).

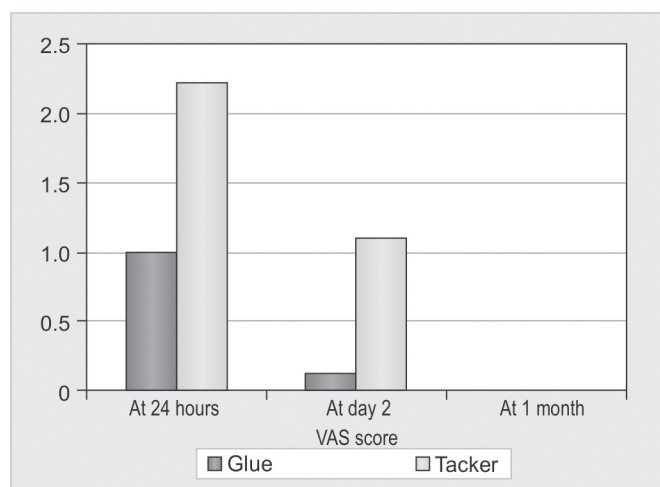
Patients with tacker fixation took more time to return to normal activities like ambulation, personal dressing, and toilet use, with mean of 3 ± 0.6 days as compared with 1 ± 0.58 days in glue fixation group, which is statistically significant ($p < 0.005$).

Cost of glue fixation is 50% less as compared with tacker fixation owing to the added cost of tacker.

Table 1: Comparison of pain

VAS score	Groups			
	Glue		Tacker	
	Mean	SD	Mean	SD
At 24 hours	1.00	0.45	2.23	1.14
At day 2	0.13	0.35	1.10	0.31
At 1 month	0	0	0	0

SD: Standard deviation

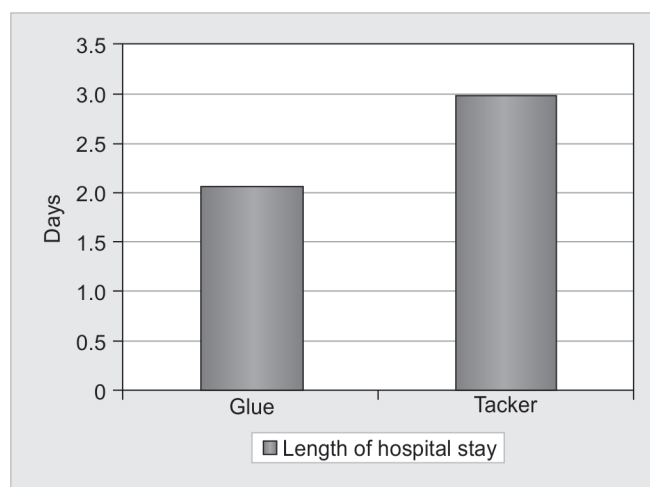


Graph 1: Comparison of pain in tacker vs glue fixation

Table 2: Length of Hospital Stay

	Glue		Tacker	
	Mean	SD	Mean	SD
		2.07	0.25	3.00

SD: Standard deviation



Graph 2: Length of hospital stay in tacker vs glue fixation

DISCUSSION

Treatment for hernia is surgical repair, which has evolved continuously over several centuries. The concept of minimally invasive surgery has changed many aspects in the surgical care of the patients, regardless of the access techniques employed for a given patient. Most of the benefits are centered on improvements in the postoperative recovery period, including a shorter length of hospital stay and earlier return to normal activities. Recently, there has been an increasing demand for laparoscopic repair from the patient population, and it has also become part of the surgeon's choice.

The aim of this study is to apply to hernia surgery the advantages of laparoscopy: Less trauma, lesser postoperative pain, early discharge, and early renewal of the normal activity. Chevrel and Rath¹ first proposed fibrin sealant as an alternative means of mesh fixation in hernia repair.

In our study, the average operation time in tacker fixation as compared with glue fixation is lesser in our study, which is again comparable to the study of Eriksen et al,² which shows glue fixation took longer than tacker fixation.

The mean pain score of glue fixation and tacker fixation at 24 hours was 1 and 2.23 respectively ($p = 0.00$). Olmi et al^{3,4} from Zingonia, Italy, evaluated the efficacy and acceptability of glue in small- to medium-sized ventral hernias. In two clinical studies, they detected stable and uniform fixation of the prosthesis and minimized intra- and postoperative complications with a

low incidence of postoperative pain. Since the p-value for the t-test is less than that of 0.05, the VAS score at 24 and 2 days indicates significant difference and also more pain tacker. Median (range) postoperative hospital stay for patients with tacker fixation is 3 (2–4) days, which is more as compared with 2 (1–3) days in glue fixation, which is statistically significant ($p < 0.0001$).

Eriksen et al² from the group of Prof. Rosenberg at the University of Copenhagen, Denmark, have performed and published an experimental study and a clinical randomized control trial on the fixation of mesh in ventral hernia with glue. They concluded that mesh fixation with glue in LVHR was associated with less postoperative discomfort and pain. In our study, no recurrence was found in both groups of fixation methods. In all studies evaluating hernia repairs, the most important benchmark is recurrence and the minimum period of follow-up, for assessing it till the date of completion of study.

CONCLUSION

- Return to normal physical activity is earlier in patients with glue fixation.
- Tackers are used for fixation of mesh in LVHR and are available in absorbable and nonabsorbable. They

work by penetrating fixation mechanism and anchors the mesh; however, this leads to some amount of postoperative pain.

- Length of hospital stay was less in the glue fixation group.
- Cost of glue fixation is 50% less as compared with tacker fixation owing to the added cost of tacker.
- Postoperative follow-up up to 1 year does not show any recurrence; however, no data of efficiency with longer follow-up are available.

However, the use of tacker or glue depends on surgeon's preference, patient affordability, and availabilities of facilities.

REFERENCES

1. Chevrel JP, Rath AM. The use of fibrin glues in the surgical treatment of incisional hernias. *Hernia* 1997 May;1(1):9-14.
2. Eriksen JR, Bisgaard T, Assaadzadeh S, Jorgensen LN, Rosenberg J. Randomized clinical trial of fibrin sealant versus titanium tacks for mesh fixation in laparoscopic umbilical hernia repair. *Br J Surg* 2011 Nov;98(11):1537-1545.
3. Olmi S, Cesana G, Sagutti L, Pagano C, Vittoria G, Croce E. Laparoscopic incisional hernia repair with fibringlue in select patients. *JLS* 2010 Apr-Jun;14(2):240-245.
4. Olmi S, Scaini A, Erba L, Croce E. Use of fibrin glue (Tissucol) in laparoscopic repair of abdominal wall defects: preliminary experience. *Surg Endosc* 2007 Mar;21(3):409-413.