

# Histological Evaluation of a Novel Pulpotomy Technique with Low-level Laser Therapy and Its Comparison with Formocresol: A Randomized Animal Trial

<sup>1</sup>AR Prabhakar, <sup>2</sup>Amitha M Shagale, <sup>3</sup>Chandrashekar Yavagal

## ABSTRACT

**Aim:** Low-level laser therapy (LLLT) has been increasingly used over the past few decades in both medicine and dentistry. It has been suggested that LLLT may be helpful in pulpal wound healing following pulp exposure. The purpose of this study was to evaluate the histological changes in dental pulp tissue after a pulpotomy procedure using a low-level diode laser in comparison with the gold standard formocresol.

**Materials and methods:** In this experimental split-mouth study, 20 teeth were randomly selected from five dogs. The animals were anesthetized and pulpotomized using a low-level diode laser (660 nm, 36 mW) and formocresol respectively. One week later, the pulpotomized teeth were extracted and subjected to histological evaluation. Histological changes seen in the pulp tissues of all the interventional groups were subjected to statistical analysis using Mann–Whitney U test for pairwise comparison;  $p < 0.05$  was considered as statistically significant and  $p > 0.05$  nonsignificant.

**Results:** On histologic evaluation, least amount of inflammation and maximal healing was evident in the LLLT group. On the contrary, the formocresol group showed severe inflammation.

**Conclusion:** Low-level laser therapy promises to be a safe, minimally invasive, yet maximally effective modality for pulpotomy.

**Keywords:** Formocresol, Low-level laser therapy, Pulpotomy medicament.

**How to cite this article:** Prabhakar AR, Shagale AM, Yavagal C. Histological Evaluation of a Novel Pulpotomy Technique with Low-level Laser Therapy and Its Comparison with Formocresol: A Randomized Animal Trial. *Int J Laser Dent* 2016;6(1):1-5.

**Source of support:** Nil

**Conflict of interest:** None

## INTRODUCTION

The aim of pulpotomy therapy is to maintain a carious primary tooth until natural exfoliation by removing the

coronal portion of the infected pulp while preserving the uninfected radicular tissue.<sup>1</sup> Formocresol has been the material of choice for pulpotomy, mainly because of its ease of usage and excellent clinical success. Yet, despite its clinical success rate, formocresol pulpotomy has constantly been under the scanner because of its dubious safety profile.<sup>2</sup>

There is enough evidence to demonstrate the systemic distribution of formocresol with attendant potential toxic effects, such as mutagenicity, carcinogenicity, and immune sensitization.<sup>3</sup>

The technological progress in the field of preserving pulpal vitality after accidental, traumatic, or carious exposures justifies the use of lasers for pulpotomy. Lasers have shown to improve the clinical and biological status of treated pulp tissue, because of their inherent wound conditioning ability through disinfection, tubular sealing, as well as excellent hemostasis.<sup>4</sup>

The added advantage of its minimally invasive nature, inherent safety, and effective procedural analgesia make low-level laser therapy (LLLT) an even more attractive preposition for use in pediatric dentistry. Hence, the present study was planned to evaluate the histological changes in dental pulp after pulpotomy with a low-level diode laser in comparison with formocresol, which has remained a gold standard medicament over the years.

## MATERIALS AND METHODS

### Study Design

This is an experimental, *in vivo*, randomized animal trial.

### Study Setting

This study was carried out in the Department of Pedodontics and Preventive Dentistry, Bapuji Dental College & Hospital, in association with Government Veterinary Hospital, Davangere, Karnataka, India. The ethical approval was obtained from both the institutional review board and the Animal husbandry Department of the state.

### Methodology

A total of 20 healthy 8-week-old dogs' primary premolars were selected for the study with the help of a veterinary

<sup>1</sup>Professor and Head, <sup>2</sup>Postgraduate Student, <sup>3</sup>Reader

<sup>1-3</sup>Department of Pedodontics and Preventive Dentistry, Bapuji Dental College and Hospital, Davangere, Karnataka, India

**Corresponding Author:** Amitha M Shagale, Postgraduate Student, Department of Pedodontics and Preventive Dentistry Bapuji Dental College and Hospital, Davangere, Karnataka, India e-mail: amithamshagle@gmail.com

surgeon. Strict adherence to the inclusion criteria was observed. Only those animals which had undergone prior vaccination against life-threatening diseases were included in the study. Similarly, only those dogs that had sound premolars were selected. A split-mouth design was followed for allocation of teeth. If one sound premolar on one side of the arch was randomly selected for group I intervention, then the same sound tooth on the contralateral arch was selected for group II intervention. A lottery dip method was used for randomized selection and allocation by a separate examiner who was not involved in the study. All the clinical interventions were carried out by a single calibrated investigator so as to maintain standardization.

### Preanesthetic Evaluation and Preparation of Animals

After a thorough evaluation from the veterinary surgeon, the animals were fed with solid food 12 hours prior to the procedure, and they were kept nil per oral for 6 hours. General anesthesia was administered by a veterinary surgeon with an intramuscular injection of 20 mg/kg of ketamine hydrochloric acid and 12 mg/kg of xylazine. An infiltration injection of xylocaine 2% was used for achieving local anesthesia.<sup>3</sup> A lateral recumbence position was maintained throughout the procedure for all the animals.

### Clinical Procedure in Detail

Once anesthesia was achieved, the cavity preparation was done on the selected teeth by a single calibrated examiner, and the pulp chamber was exposed using a slow-speed no. 4 round bur. The same bur was used to penetrate the coronal pulp, parallel to the long axis of the tooth. The coronal pulp was then removed using a small size (1 mm) sharp spoon excavator followed by copious irrigation with saline. Primary hemostasis was achieved by placing a sterile saline-soaked cotton pellet on the radicular pulp under light pressure for 5 minutes.

### Pulpotomy with LLLT

In the LLLT group, complete hemostasis was achieved by exposing the canal orifices to 660 nm low-level laser of 36 mW output in noncontact mode. The energy delivered (fluence) with an optical laser headpiece held for 4 minutes was 8.64 J/cm<sup>2</sup> followed by the placement of a zinc oxide eugenol base (Fig. 1).

### Pulpotomy with Formocresol

In the formocresol group, after hemostasis was achieved, a sterile cotton pellet dampened and double-squeezed with formocresol (1:5 conc.) was placed in contact with

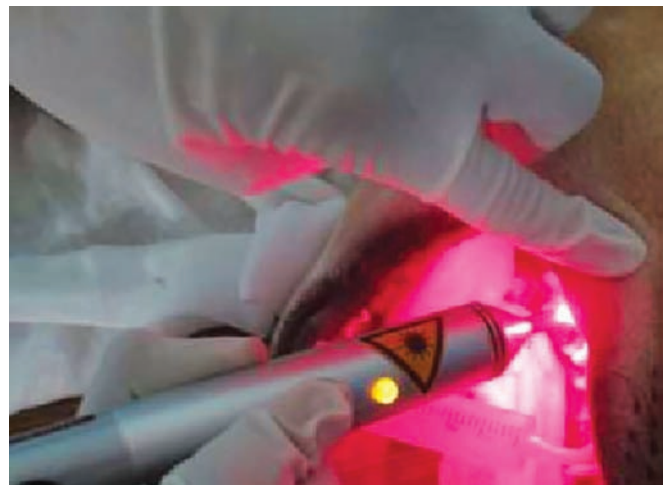


Fig. 1: Application of low-level diode laser

the pulp for 4 minutes, which was then followed by the placement of a zinc oxide eugenol base.

Postoperatively, the animals were kept under strict supervision and intense monitoring under a trained veterinary surgeon.

After 1 week, 20 pulpotomized premolars from the dogs were extracted. All these specimens were fixed in 10% buffered formalin for 2 days and subsequently decalcified using 10% nitric acid. The teeth were then processed, sectioned, and stained with hematoxylin and eosin for histological assessment. The sections were observed under an optical light microscope by a trained and calibrated oral pathologist. The histopathological changes were assessed using the following criteria<sup>3</sup>:

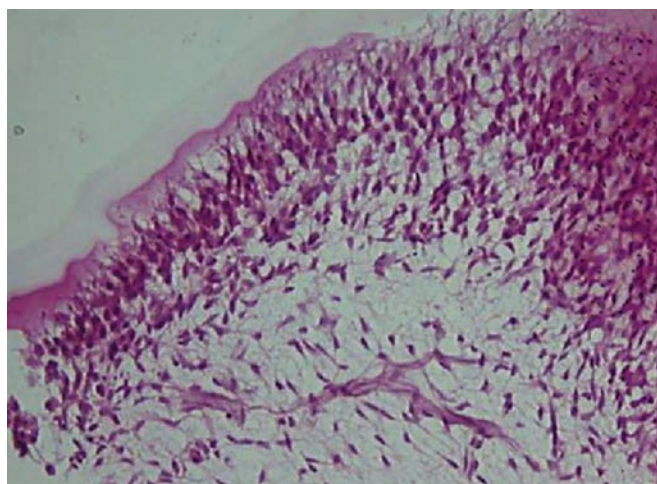
- 1 = absent or very few inflammatory cells polymorphonuclear neutrophils (PMNs);
- 2 = mild, defined as an average of <10 inflammatory cells (PMNs);
- 3 = moderate, defined as an average of 10 to 25 inflammatory cells (PMNs);
- 4 = severe, defined as an average >25 inflammatory cells (PMNs).<sup>3</sup>

### Statistical Analysis

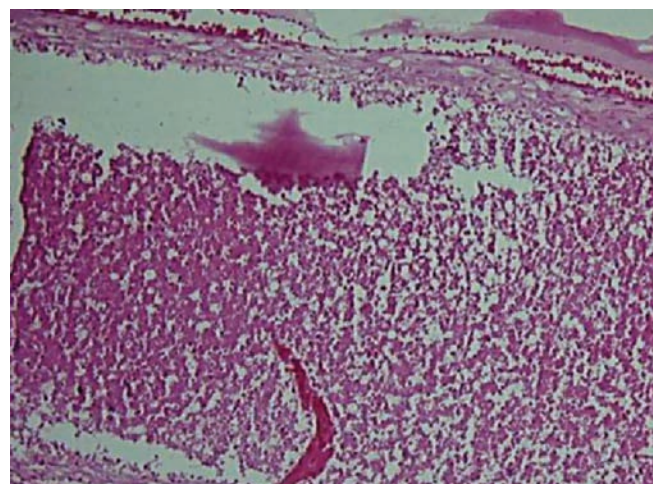
Statistical analysis was carried out using Statistical Package for the Social Sciences (version 16). Results were subjected to statistical analysis using Mann-Whitney U test for pairwise comparison;  $p < 0.05$  was considered as statistically significant and  $p > 0.05$  nonsignificant.

## RESULTS

Based on light microscopic observations, least inflammation was seen in low-level diode laser (Fig. 2) as compared with severe inflammation in formocresol (Fig. 3), refer Table 1. On pairwise comparison, for group I LLLT,



**Fig. 2:** Histological picture showing least inflammation in LLLT group



**Fig. 3:** Histological picture showing severe inflammation in formocresol group

**Table 1:** Histopathological findings of LLLT and formocresol

	No inflammation	Mild	Moderate	Severe
<i>Group I</i>				
LLLT	9	1	0	0
<i>Group II</i>				
Formocresol	0	1	1	8

Sample size – 10 samples for each group

**Table 2:** Pairwise comparison of interventional groups using the Mann–Whitney U-test

Study groups	n	Median (Q1–Q3)	Mann–Whitney U-test	
			U statistic	p-value
<i>Group I</i>				
LLLT	10	0 (0–0)	0.500	<0.001*
<i>Group II</i>				
Formocresol	10	3 (2.75–3)		

p < 0.05, statistically significant; p > 0.05, nonsignificant; \*significant

the median inflammation was 0 (0), while for group II (formocresol), the median inflammation was 3 (2.75–3). Thus, there was a statistically significant difference in the inflammation between the two interventional groups, i.e., group II showed a greater amount of inflammation as compared with group I with a p-value of <0.001 (Table 2).

## DISCUSSION

Day in and day out, pediatric dentists face the challenge of treating deep carious lesions in primary teeth. The scenario becomes all the more complicated when it is evident that pulpal health is compromised. The retention of pulpally involved primary teeth in a healthy state until their time of normal exfoliation has remained a dilemma for clinicians. But, it is worth every effort since primary teeth maintain the shape of the dental arches, hold the space for succedaneous teeth, prevent detrimental tongue and speech habits, preserve aesthetics, as well as maintain function. Hence, primary teeth with caries should ideally be restored rather than extracted.<sup>5</sup>

Pulpotomy is a well-recognized conservative endodontic procedure for treating deep carious lesions, when inflammation is restricted to the coronal aspect of the pulp. The technique of pulpotomy is achieved by the amputation of the inflamed/infected coronal tissues, thereby allowing healing to take place at the entrance of the root canals while maintaining the vitality of

the radicular tissue underneath. In doing so, the pulp stumps need to be treated with certain medicaments that promote healing and help in preserving the vitality of the tooth.<sup>6</sup>

Formocresol has been the drug of choice ever since it was introduced as a pulpotomy medicament. In fact, it has always been referred to as the “gold standard” as far as pulpotomy medications are concerned. The reasons for this include its ease of availability, bacteriostatic nature, and superior tissue fixation property, thrusting an impressive success rate in the range of 70 to 90%.<sup>7</sup> However, of late, several concerns have been raised about formocresol as a pulpotomy medicament because of the following entities:

- Pulpal responses with severe inflammation and necrosis
- Cytotoxicity
- Systemic disturbances
- Mutagenic and carcinogenic potential and
- Immunologic responses.<sup>8</sup>

All the above-cited reasons thus reiterate the need for an alternate pulpotomy medicament.

In an effort to find a more biologically acceptable and effective alternative to formocresol, nonpharmacologic haemostatic techniques, such as electrosurgery and

laser therapy have been tried.<sup>9</sup> Using laser technology for pulpotomy has several advantages, such as control of hemorrhage, sterilization, preservation of pulpal vitality, minimal discomfort/pain, and a shortened healing period. The lasers commonly used for pulpotomy procedure are carbon dioxide, diode, neodymium-doped yttrium aluminum garnet (YAG), erbium-doped YAG, and erbium-doped yttrium-scandium-gallium-garnet.<sup>3</sup> However, all these laser wavelengths and outputs affect pulpal tissue through coagulation and vaporization, with some potential for thermal damage. Hence, they have been termed as high-power surgical lasers.

Of late, a lesser known variant of laser technology, i.e., the low-powered therapeutic lasers, has garnered much attention. These low-power lasers act more as biostimulators and are hence, referred to as healing lasers or cold lasers. These lasers have wavelengths that span the "visible red" to "near infrared" part of the electromagnetic spectrum. The advantage of these low-level lasers is that they stimulate natural biological processes and mainly affect cells that show a poor redox potential.<sup>10</sup> Hence, in the present intervention, formocresol, which has remained a gold standard for pulpotomy, was considered as the control and a novel low-level laser was compared against it. The laser was operated at an ultra-safe power setting (0.036 mW) so as to make a clinical extrapolation viable at a later date.

In order to assess the clinical success and therapeutic outcome of any pulpotomy medicament, clinical and radiographic findings are usually employed. But in order to know the true biologic response of the dental pulp, a thorough histopathological evaluation is needed, which may not be feasible with human subjects especially those belonging to the pediatric age group. Hale<sup>11</sup> has demonstrated structural and histological similarities between human and canine dental pulps. Hence, the present study was conducted on the primary premolars of healthy dogs coinciding with their time of natural exfoliation.

The results of the present intervention affirmed that LLLT reduces inflammation as evidenced by the lack of it in most of the samples. This is scientifically plausible and easy to explain as all low-level laser wavelengths have potent anti-inflammatory, analgesic, and hemostatic abilities. These findings implicate a positive healing outcome, thus preserving the vitality of the radicular pulp. In addition to this, LLLT gives a whole new dimension to primary endodontics as it is a noninvasive and a nonpharmacological entity offering superior therapeutic benefits, such as lack of bleeding, faster healing, adequate analgesia, and reduced postoperative infection.

Previous researchers Sun and Tunér have reported that low-level lasers provide many additional positive

postoperative outcomes like accelerated wound healing, regeneration, relief of pain, and enhancement of local immunity.<sup>12</sup> Similarly, Todea et al<sup>4</sup> and Mareddy et al<sup>3</sup> have also shown that laser therapy stimulates the odontoblast cells by activating the cell signaling molecules, such as Smads, a class of proteins that help in modulating the activity of the transforming growth factor beta ligands, ultimately leading to mineralization and formation of tertiary dentin. This could explain the superior therapeutic outcomes observed with the low-level laser group of the present study.

Shoji et al<sup>13</sup> reported that thermal injury to the pulp depends on the length of laser exposure rather than the output power of the device. Thus, we decided to stick to the standardized time of exposure of 4 min in our study, so as to ultimately deliver a fluence of 8.64 J/cm<sup>2</sup>.

The use of formocresol on canine pulps showed necrosis of the coronal portion next to a thin superficial layer of fixation, which indicates a poor and inadequate outcome.<sup>2</sup> In the present study, severe inflammation with some tissue necrosis was also observed. On histological evaluation, dense layers of eosinophilic fixed tissue subadjacent to formocresol were seen followed by an inflammatory zone that was evident in most of the study samples. These are in accordance with previous studies that have reported severe reaction of the dental pulp to formocresol, and the present study reemphasizes the fact that the fixation of pulp tissue using formocresol is never complete.<sup>14</sup>

Our results are also in accordance with those of Agamy et al,<sup>8</sup> who reported depositions of poorly calcified secondary dentin bridging the pulp tissues. The dispersed pulp cells were almost completely necrotic with islands of inflammatory cells. The specimens showed little evidence of odontoblastic cell layers being present.

## CONCLUSION

Within the parameters tested in the present intervention, LLLT appears to be a safe, minimally invasive, yet a maximally effective modality for pulpotomy in comparison to formocresol.

## REFERENCES

1. Golpayegani MV, Ansari G, Tadayon N, Shams S, Mir M. Low-level laser therapy for pulpotomy treatment of primary molars. *J Dent (Tehran)* 2009;6(4):168-174.
2. El-Meligy O, Abdalla M, El-Baraway S, El-Tekya M, Dean JA. Histological evaluation of electrosurgery and formocresol pulpotomy techniques in primary teeth in dogs. *J Clin Pediatr Dent* 2001 Fall;26(1):81-85.
3. Mareddy A, Mallikarjun SB, Shetty PV, Vanga V, Rao N, Chandru TP. Histological evaluation of diode laser pulpotomy in dogs. *J Oral Laser Appl* 2010 Jan;10(1):7-16.

4. Todea C, Kerezsi C, Balabuc C, Calniceanu M, Filip L. Pulp capping – conventional to laser-assisted therapy. *J Oral Laser Appl* 2008;8:71-82.
5. Caicedo R, Abbott PV, Alongi DJ, Alarcon MY. Clinical, radiographic and histological analysis of the effects of mineral trioxide aggregate used in direct pulp capping and pulpotomies of primary teeth. *Aust Dent J*. 2006 Dec;51(4):297-305.
6. Ibricevic H, al-Jame Q. Ferric sulfate as pulpotomy agent in primary teeth: twenty month clinical follow-up. *J Clin Pediatr Dent* 2000 Summer;24(4):269-272.
7. Patchett CL, Srinivasan V, Waterhouse PJ. Is there life after Buckley's formocresol? Part II – development of a protocol for the management of extensive caries in the primary molar. *Int J Paediatr Dent* 2006 May;16(3):199-206.
8. Agamy HA, Bakry NS, Mounir MM, Avery DR. Comparison of mineral trioxide aggregate and formocresol as pulp-capping agents in pulpotomized primary teeth. *Pediatr Dent* 2004 Jul-Aug;26(4):302-309.
9. Hunter ML, Hunter B. Vital pulpotomy in the primary dentition: attitudes and practices of specialists in paediatric dentistry practising in the United Kingdom. *Int J Paediatr Dent* 2003 Jul;13(4):246-250.
10. Moritz, A. Oral laser application. Berlin: Quintessenz Verlags-GmbH; 2006.
11. Hale, FA. Hale veterinary clinic; 1997 Jan [cited 2014 Jan 2]. p. 1-3. Available from: <http://www.toothvet.ca>.
12. Sun G, Tunér J. Low-level laser therapy in dentistry. *Dent Clin North Am* 2004 Oct;48(4):1061-1076, viii.
13. Shoji S, Nakamura M, Horiuchi H. Histopathological changes in dental pulps irradiated by CO<sub>2</sub> laser: a preliminary report on laser pulpotomy. *J Endod* 1985 Sep;11(9):379-384.
14. Jose B, Ratnakumari N, Mohanty M, Varma HK, Komath M. Calcium phosphate cement as an alternative for formocresol in primary teeth pulpotomies. *Indian J Dent Res* 2013 Jul-Aug;24(4):522.